



Cervical Subcutaneous Cartilaginous Choristoma in an Infant

Abdurrahman Karaman*, Canan Ceran*, Sema Uğuralp*, İclal Gürses**, Mehmet Demircan*

* Department of Pediatric Surgery, Medical School of İnönü University, Malatya, Turkey

** Department of Pathology, Medical School of İnönü University, Malatya, Turkey

The cartilaginous choristoma in children is very rare in literature. Its treatment is complete surgical removal as promptly as possible in order to get an exact histopathological diagnosis. In this study we present and discuss a 10-month-old girl with cartilaginous choristoma located subcutaneously just on the left sternocleidomastoid muscle without any associated anomalies such as branchial remnants.

Key Words: Cartilage, Choristoma, Heterotopia, Cervical tumor, Children

Bir İnanıtta Saptanan Servikal Subkutan Yerleşimli Kartilajinöz Koristoma

Kartilajinöz koristoma çocuklarda oldukça nadir görülen bir patolojidir. Kitlenin total çıkarılması en seçkin tedavi yöntemidir. Bu çalışmada boyun lateral yerleşimli bir kartilajinöz koristoma olgusu sunulmuştur.

Anahtar Kelimeler: Cartilaj, Koristoma, Heterototi, Servikal tümör, Çocuk

Choristoma is defined as a tumor-like mass of normal cells or tissue that develops in an abnormal location. Choristoma is mostly seen in the head and neck, especially in the oral cavity.¹ Cartilage, salivary gland, bone, thyroid, sebaceous gland, brain tissue, and gastric mucosa are identified as the sources of intraoral choristoma.² Most of the cartilaginous choristomas involve the tongue. They were also found in the buccal mucosa and soft palate, but are rarely seen in the neck.^{1,3} We present an infant with a cartilaginous choristoma on sternocleidomastoid muscle (SCM).

CASE REPORT

A 10-month-old girl infant presented to the Department of Pediatric Surgery with a left cervical mass. The mass was a firm lesion measuring 1 cm in diameter and located subcutaneously on the left lower third of the neck and at just anterior border of SCM. The overlying skin appeared normal. The lesion was painless and had a calcified appearance. No inflammation or discharge were disclosed. (Figure 1). The lesion had been presented since birth. Pilomatricoma was thought as the initial diagnosis, and surgical excision was planned. At surgical exploration, a mature and shaped cartilage was found subcutaneously on the left sternocleidomastoid muscle. There was any other pathologies or any connection with the deep cervical underlying structures (Figure 2). The lesion was excised and subjected to histological analysis. Microscopic examination disclosed a circumscribed nodule of hyaline cartilage separated from the adjacent skeletal muscle and overlying skin by a thin fibrous connective tissue capsule (Fig 3).

DISCUSSION

Childhood tumors and tumor-like lesions of the neck are rare and tend to be benign. Congenital, developmental, and inflammatory lesions make up the majority of the masses in the pediatric neck.⁴ Congenital cystic lesions (thyroglossal duct cysts, branchial cysts, dermoid cysts, lymphangiomas, or cystic hygromas) are very common. Common neoplastic lesions are hemangiomas and papillomas. The most common malignant tumors in the head and neck region are lymphomas and rhabdomyosarcomas. Reactive or infectious lymph node enlargements account also

for a significant amount of cervical masses.^{4,5} Furthermore some rare lesions were reported such as choristoma in children.⁶

Figure 1. Clinical appearance of the mass

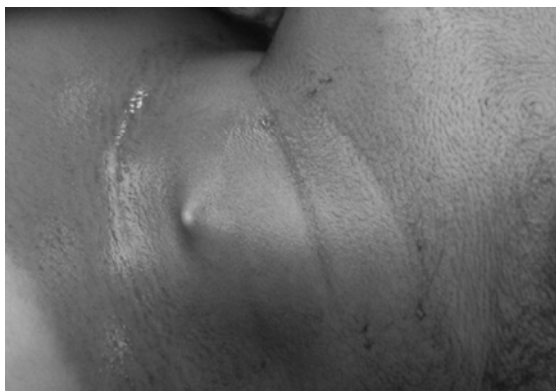

Figure 2. At surgical exploration, a mature and shaped cartilage was found

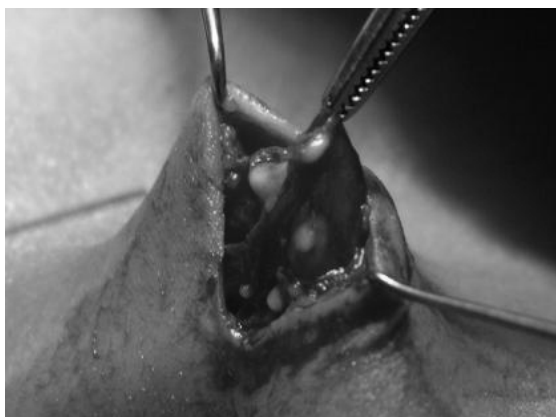
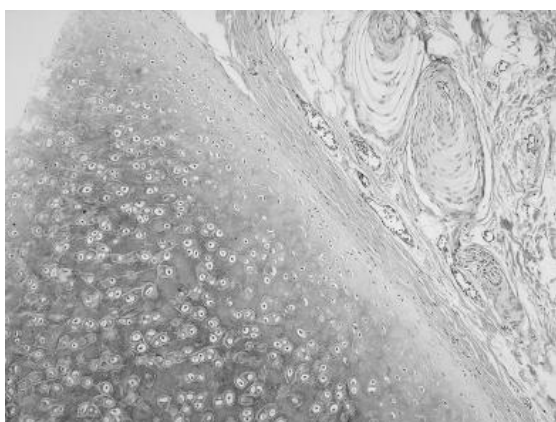


Figure 3. Light micrograph showing normal subcutaneous area with the subjacent island of mature hyaline cartilage (hematoxylin and eosin; original magnification, 100).



Choristoma is defined as a mass formed by normal tissue that is present in an aberrant location. Whereas cartilage choristoma is a well-described entity in the head and neck, the finding of heterotopic cartilage on the sternocleidomastoid muscle is much less common. Cartilaginous choristoma was first described by Berry in 1890.^{6,7} It is usually found in the distal extremities and rarely in the soft tissue of head and neck.¹⁻³ Among the head and neck choristomas the oral cavity^{8,9}, the nasopharynx¹⁰, the middle ear¹¹ and the eye region¹² have been described in literature. Bhargava et al. presented a case having cartilaginous choristoma associated with the tonsil.⁹ Toida et al. also reported a cartilaginous choristoma of the tongue and concluded that lingual cartilaginous choristomas are rare tumors.¹ In another study Malis et al described one case of a cartilaginous choristoma of the nasopharynx.¹⁰

In our case, cartilaginous choristoma was located subcutaneously on lateral cervical area and anterior to the sternocleidomastoid muscle. There are a lot of cases associated with cervical cartilage choristoma and branchial remnants.^{13,14} In our case we did not find any associated anomalies. We found two reports similar to our case in literature. Kao et al reported second case of cartilaginous choristoma of the neck that coexists with a branchial cleft cyst.¹⁵ In another study, two cases of elastic cartilage choristoma in the skin and subcutaneous tissues of the lower midline of the neck were reported by Rachman et al.¹⁶

The underlying pathogenesis of cartilaginous choristoma is still unclear. As the possible origin of cartilage in the soft tissue undifferentiated mesenchymal cells may be considered. The tumour-like expansion may be explained by the process of cartilage formation from multipotential mesenchymal cells with proper stimulation and by its active interstitial and appositional growth.² Another possible origin is embryonic remnants. During embryonic development, the heterotopic cartilaginous remnants from major and minor alar cartilages and septal cartilage may grow under the influence of certain stimuli.⁶

Cartilaginous choristoma should be distinguished from cartilaginous metaplasia that usually occurs in the soft tissue beneath trauma or neoplastic degeneration. Cartilaginous metaplasia in the head and neck masses has also been reported as an accompanied circumstance. These lesions usually are located in laryngotracheal area. In a study, Casiraghi et al reported 19 cases of chondroid tumors which

Cervical Subcutaneous Cartilaginous Choristoma in an Infant

contain two chondroid metaplasia of the larynx.¹⁷ In another study, a case of fibroepithelial polyp with chondroid metaplasia of the tongue had been reported by Lloyd et al.¹⁸ In present case, lesion forms purely mature and shaped cartilage and with no history of trauma.

The treatment of choice should be complete surgical removal as promptly as possible, as these lesions can not be diagnosed without histopathological investigations. Despite no such pathology was encountered in this specific case, the surgeon should be cautious about associated anomalies during excision. Recurrence and malignant change have not yet been reported.²

REFERENCES

1. Toida M, Sugiyama T, Kato Y. Cartilaginous choristoma of the tongue. *J Oral Maxillofac Surg* 2003; 61:393-396.
2. Chou L, Hansen LS, Daniels TE. Choristomas of the oral cavity: a review. *Oral Surg Oral Med Oral Pathol* 1991; 72:584-593.
3. Rachman R, Heffernan AH. Elastic cartilage choristoma of the neck. *Plast Reconstr Surg* 1979; 63:424-425.
4. Imhof H, Czerny C, Hormann M, Krestan C. Tumors and tumor-like lesions of the neck: from childhood to adult. *Eur Radiol* 2004; 14:L155-165
5. Som PM, Curtin HD. *Head and neck imaging*, 4th edn. Mosby, St. Louis 2003.
6. Matsushita K, Tahara M, Sato H, Nakamura E, Fujiwara T. Cartilaginous choristoma deep in the upper midline oral vestibule. *British Journal of Oral and Maxillofacial Surgery* 2004; 42: 436-438.
7. Berry J. Fibro-chondroma of tongue. *Trans Pathol Soc Lond* 1890; 41:81-82.
8. Kainz J, Kobierski S, Jakse R, Beham A. Choristoma of the soft palate. *Eur. Arch. Otorhinolaryngol* 1990; 247: 264-266
9. Bhargava D, Raman R, Abri RKA, Bushnurmath B. Heterotopia of the tonsil. *J. Laryngol. Otol* 1996; 110: 611- 612.
10. Malis DJ, Breisch EA, Billman GF. Cartilaginous choristoma of the nasopharynx. *Clin. Anat.* 2000; 13: 263-266
11. Anderhuber W, Beham A, Walch C, Stammberger H. Choristoma of the middle ear. *Eur. Arch. Otorhinolaryngol.* 1996; 253: 182-184
12. Blenc AM, Gomez JA, Lee MV, Torres FX, Linder JS. Phakomatous choristoma: a case report and review of the literature. *Am. J. Dermatopath.* 2000; 22: 55- 59
13. Braun H, Hofmann T, Wolfigruber H, Anderhuber W, Beham A, Stammberger H. Case report of bilateral cervical chondrocutaneous branchial remnants. *Int J Pediatr Otorhinolaryngol.* 2003; 67:89-92
14. Atlan G, Egerszegi EP, Brochu P, Caouette-Laberge L, Bortoluzzi P. Cervical chondrocutaneous branchial remnants. *Plastic Reconstr. Surg.* 1997; 100: 32- 39
15. Kao CH, Wang HW, Yu CP. Cartilaginous choristoma of the neck associated with a branchial cleft cyst. *Otolaryngol Head Neck Surg.* 2001; 124:705-6
16. Rachman R, Heffernan AH. Elastic cartilage choristoma of the neck. *Plast Reconstr Surg* 1979; 63:424-5
17. Casiraghi O, Martinez-Madrigal F, Pineda-Daboin K, et al. Chondroid Tumors of the Larynx: A Clinicopathologic Study of 19 Cases, Including Two Dedifferentiated Chondrosarcomas. *Annals of Diagnostic Pathology*, 2004; 8: 189- 97
18. Lloyd S, Lloyd J, Dhillon R. Chondroid metaplasia in a fibroepithelial polyp of the tongue. *J Laryngol Otol.* 2001; 115: 681-2

Corresponding Address:

Prof.Dr. Mehmet Demircan
Department of Pediatric Surgery
Inönü University Medical School
44280 Malatya, Turkey
E-mail: mdemircan@inonu.edu.tr
Phone : 422 341 06 60
Fax : 422 341 07 28