

Cortical Dysplasia and Epilepsy in a Patient with Thrombocytopenia-Absent Radii (TAR) Syndrome

TAR (Thrombocytopenia-Absent Radii) Sendromu Olan Bir Hastada Kortikal Displazi ve Epilepsi

Özden Kamışlı¹, Serap Saygı²

¹Inönü Üniversitesi Tıp Fakültesi, Nöroloji Anabilim Dalı, Malatya, Türkiye

²Hacettepe Üniversitesi Tıp Fakültesi, Nöroloji Anabilim Dalı, Ankara, Türkiye

Turk Norol Derg 2011;17:55-57

ÖZET

"Thrombocytopenia-absent radii (TAR)" sendromu her iki başparmak varlığına rağmen bilateral radius yokluğu ve trombositopeni ile karakterizedir. TAR sendromlu hastalarda alt ekstremitte tutulumu, kardiyak, gastrointestinal, renal ve genital anormallikler de görülebilir. Ayrıca bazı hastalarda nörolojik anormallikler olarak; epilepsi, öğrenme güçlüğü, intrakraniyal vasküler malformasyonlar, sensorinöral işitme kaybı, korpus kallosum hipoplazisi ve serebellar disgenezi bildirilmiştir. TAR sendromu ve kortikal displazi birlikteliği daha önceden bildirilmemiştir. Biz bu yazımızda sağ pariyetal displaziye bağlı fokal epilepsisi olan TAR sendromlu bir olguyu sunduk.

Anahtar Kelimeler: Trombositopeni ve radius yokluğu sendromu, epilepsi, kortikal gelişim anomalisi.

ABSTRACT

Cortical Dysplasia and Epilepsy in a Patient with Thrombocytopenia-Absent Radii (TAR) Syndrome

Özden Kamışlı¹, Serap Saygı²

¹Department of Neurology, Faculty of Medicine, University of Inonu, Malatya, Turkey

²Department of Neurology, Faculty of Medicine, University of Hacettepe, Ankara, Turkey

Thrombocytopenia-absent radii (TAR) syndrome is characterized by bilateral absence of the radii in the presence of both thumbs and thrombocytopenia. Lower limb involvement and cardiac, gastrointestinal, renal, and genital abnormalities may also be seen in the patients with TAR syndrome. Although epilepsy, learning difficulties, intracranial vascular malformations, sensorineural hearing loss, hypoplasia of the corpus callosum, and cerebellar dysgenesis as neurological abnormalities have been reported in a few patients, there is no previous report of a patient with TAR syndrome and cerebral cortical dysplasia. Here we report a patient with TAR syndrome who suffered from focal epilepsy due to right parietal dysplasia.

Key Words: Thrombocytopenia absent radius syndrome, epilepsy, malformations of cortical development.

INTRODUCTION

Thrombocytopenia-absent radii (TAR) syndrome is a rare, probably autosomal recessive disease and was first described by Shaw and Oliver in 1959 (1-3). Lower limb involvement and cardiac, renal, genital, and gastrointestinal abnormalities have also been reported (2-7). Central nervous system involvement in TAR syndrome is very rare. Epilepsy, learning difficulties, intracranial vascular malformations, sensorineural hearing loss, hypoplasia of the corpus callosum, and cerebellar dysgenesis have been reported in a few patients (3,7-9). We describe here a patient with TAR syndrome who suffered from focal epilepsy due to right parietal dysplasia. To the best of our knowledge, no case of TAR syndrome and cortical dysplasia has been reported previously.

CASE

A 25-year-old male was admitted to the neurology clinic for drug-resistant simple partial seizures characterized by the sensations of falling, urge to urinate, and feeling thirsty. Secondary generalized seizures were controlled by antiepileptic medication. The seizures had started at the age of 2. There was no consanguinity between parents. The physical examination revealed bilateral short upper extremities and lower extremities with genu varum and valgus of the feet. His older brother had similar limb defects and died in the first year of life. It was reported that his father's sister also had a daughter with similar limb abnormalities. The patient's chromosomal investigation had been done during childhood and was reported as normal 46, XY karyotype. Other investigations in the past considering renal and cardiac anomalies had been reported as normal. The laboratory examinations were normal except for platelet count, which was decreased (77.000/mL). The X-rays of his arms showed the bilateral absence of radii (Figure 1). Interictal EEG recordings showed sharp slow

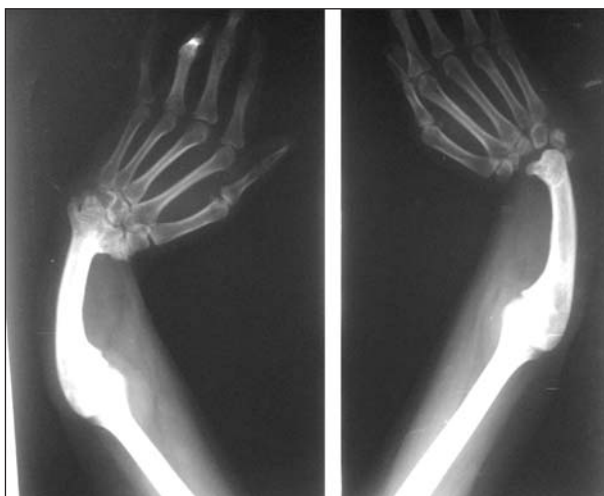

Figure 1. X-ray of the patient showing bilateral absence of radii.

wave paroxysms on the right temporoparietal area. His brain magnetic resonance imaging (MRI) was reported initially as normal by the radiologist, but dysplastic cortex on the right mesial parietal lobe was obvious especially on the flair sequences (Figure 2).

DISCUSSION

TAR syndrome is a congenital malformation syndrome characterized by bilateral absence of the radii and thrombocytopenia (1-3). Although bilateral absent radii in the presence of both thumbs is a constant feature of this syndrome, approximately half of the patients with TAR syndrome (47%) may have lower limb anomalies, as in our patient (2). Platelet counts of our patient since childhood had consistently shown thrombocytopenia. Thrombocytopenia cannot be found initially in some patients. If there is a strong suspicion of TAR syndrome, platelet count should be repeated, as the platelet counts may fluctuate (3). The etiology of thrombocytopenia is unknown. Bone marrow examinations have shown normal or hypercellular bone marrow with very low, absent, or immature megakaryocytes (2,3). Only two cases with TAR syndrome and epilepsy have been reported to date, and one of them also had intracranial vascular anomaly (3). Our patient is the third case with epilepsy and TAR syndrome and the first to also have cortical dysplasia.

The genetic basis of TAR syndrome is uncertain. In the majority of the cases, it is autosomal recessive, although an autosomal dominant penetrance has also been proposed (2,5,10). Interestingly, there was no consanguinity in most of the families of TAR patients, and there was also no consanguinity in our patient's family (2). The existence of the other two affected family members of our patient is another evidence for the genetic basis of TAR syndrome. It is reported that TAR syndrome is associated with a deletion on chromosome 1q21.1, but the phenotype de-

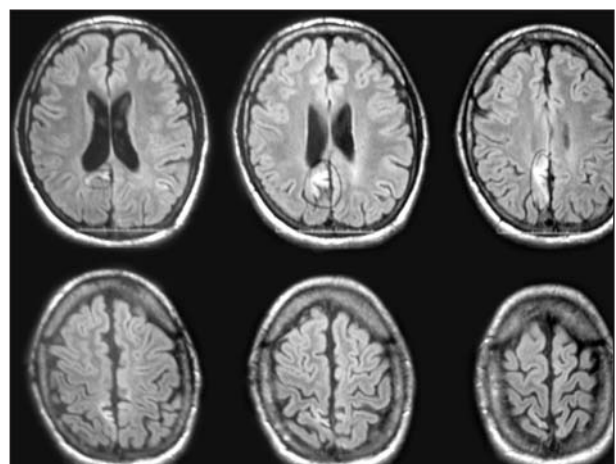


Figure 2. Flair sequences of the brain MRI of the patient showing right mesial parietal cortical dysplasia.

velops only in the presence of an additional as-yet-unknown modifier (mTAR) (10). The mechanism during embryogenesis leading to multiple congenital anomalies is not clear yet, and we cannot explain why the cortical dysplasia developed in our case with TAR syndrome. More routine MRI investigations may reveal an increase in the number of patients with TAR syndrome and cortical dysplasia, but subtle cortical abnormalities may easily be overlooked by the physicians.

REFERENCES

1. Shaw S, Oliver RAM. Congenital hypoplastic thrombocytopenia with skeletal deformities in siblings. *Blood* 1959;14:374-7.
2. Hall JG. Thrombocytopenia and absent radius (TAR) syndrome. *J Med Genet* 1987;24:79-83.
3. Greenhalgh KL, Howell RT, Bottani A, Ancliff PJ, Brunner HG, Verschuuren-Bemelmans CC, et al. Thrombocytopenia-absent radius syndrome: a clinical genetic study. *J Med Genet* 2002;39:876-81.
4. Whitfield MF, Barr DG. Cows' milk allergy in the syndrome of thrombocytopenia with absent radius. *Arch Dis Child* 1976;51:337-43.
5. Hedberg VA, Lipton JM. Thrombocytopenia with absent radii. A review of 100 cases. *Am J Pediatr Hematol Oncol* 1988;10:51-64.
6. Bradshaw A, Donnelly LF, Foreman JW. Thrombocytopenia and absent radii (TAR) syndrome associated with horseshoe kidney. *Pediatr Nephrol* 2000;14:29-31.
7. Menghsol SC, Harris RD, Ornvold K. Thrombocytopenia and absent radii, TAR syndrome: report of cerebellar dysgenesis and newly identified cardiac and renal anomalies. *Am J Med Genet A* 2003;123:193-6.
8. MacDonald MR, Schaefer GB, Olney AH, Patton DF. Hypoplasia of the cerebellar vermis and corpus callosum in thrombocytopenia with absent radius syndrome on MRI studies. *Am J Med Genet* 1994;50:46-50.
9. Skórka A, Bielicka-Cymermann J, Gieruszczak-Bialek D, Korniszewski L. Thrombocytopenia-absent radius (TAR) syndrome: a case with agenesis of corpus callosum, hypoplasia of cerebellar vermis and horseshoe kidney. *Genet Couns* 2005;16:377-82.
10. Klopocki E, Schulze H, Strauss G, Ott CE, Hall J, Trotier F, et al. Complex inheritance pattern resembling autosomal recessive inheritance involving a microdeletion in thrombocytopenia-absent radius syndrome. *Am J Hum Genet* 2007;80:232-40.

Yazışma Adresi/Address for Correspondence

Prof. Dr. Serap Saygi
Hacettepe Üniversitesi Tıp Fakültesi
Nöroloji Anabilim Dalı
Ankara/Türkiye

E-posta: ssaygi@hacettepe.edu.tr

geliş tarihi/received 02/09/2010

kabul edildiği tarihi/accepted for publication 27/09/2010