

# Comparison of intracorporeal or extracorporeal placement of stapler anvil in colorectal NOSE surgery

Ersin Gundogan, Cuneyt Kayaalp

Inonu University Faculty of Medicine, Department of Gastroenterology Surgery, Malatya, Turkey

Copyright © 2020 by authors and Annals of Medical Research Publishing Inc.

## Abstract

**Aim:** The aim of this study is to compare the results of the patients for whom intracorporeal or extracorporeal anvil insertions were performed. Natural orifice specimen extraction (NOSE) surgery has been started from the 21st century onwards in order to reduce wound-related complications of laparoscopy. Two types of anvil placements, including intracorporeal or extracorporeal placements, are used in the application of NOSE, which is combined with distal colorectal surgery.

**Material and Methods:** We retrospectively collected the data from 77 patients who underwent laparoscopic distal colorectal surgery combined with NOSE in our clinic between 2013 and 2019. Patients were evaluated in two groups as intra-corporeal and extracorporeal. Selection of the technique was based on the length of sigmoid colon and mesocolon. Demographic data, operative findings, pathological results and follow-up information were evaluated.

**Results:** Of 77 patients who underwent distal colorectal surgery and circular stapler anastomosis; 44 were in the intracorporeal group and 33 were in the extracorporeal group. There was no difference between the two groups in terms of gender, age, BMI, comorbidity, and abdominal operation history of patients. The number of patients undergoing low anterior resection was higher in the extracorporeal group, and also the number of patients undergoing anterior resection was higher in the intracorporeal group. Peroperative findings, intraoperative and postoperative complications of patients were similar in both groups. The postoperative first-day pain scale was lower in the intracorporeal group ( $3.3 \pm 2.1$  vs.  $4.4 \pm 2.3$ ,  $p=0.03$ ). No significant difference was found between the two groups in other pain scales and cosmetic scores. The oncologic results were similar during the mean follow-up of  $35.5 \pm 24.1$  months.

**Conclusion:** Although anvil placement techniques are not interchangeable, it is seen that neither method predominates the other in cases where both are suitable.

**Keywords:** Minimally invasive surgery; NOSE; colon cancer; low anterior; colectomy; transanal; transvaginal; laparoscopic colorectal surgery

## INTRODUCTION

Thanks to the advances in minimally invasive surgery, new methods have been developed which increase the advantages of laparoscopy in colorectal surgery. The fact that conventional laparoscopy requires an abdominal incision for the extraction of the specimen, which leads to infection, hernia and postoperative pain has been the subject of research (1). Natural orifice specimen extraction (NOSE) surgery has come to the fore in selected patients and has been an alternative to conventional laparoscopy. Thanks to NOSE, low morbidity, and reduced

wound-related pain advantage has been achieved (2,3). In NOSE surgery, as in other distal colorectal surgeries, anastomosis is often performed with the aid of stapler. Stapler anvil is placed in two types as intracorporeally and extracorporeally. The location and stage of the tumor and the length of sigmoid colon - mesenterium are the main determinants of this choice. However, there are cases where both techniques can be performed.

The aim of this study was to compare the results of patients undergoing intracorporeal and extracorporeal anvil placement in distal colorectal diseases in which we

Received: 15.01.2020 Accepted: 06.02.2020 Available online: 17.02.2020

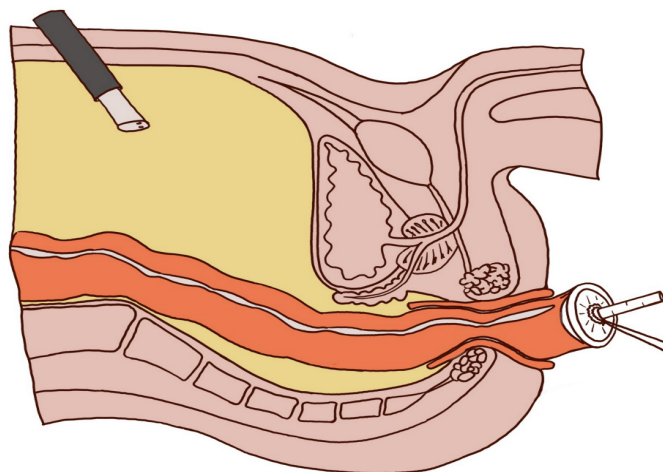
Corresponding Author: Ersin Gundogan, Inonu University Faculty of Medicine, Department of Gastroenterology Surgery, Malatya, Turkey, E-mail: ersingundogan@hotmail.com

performed NOSE surgery.

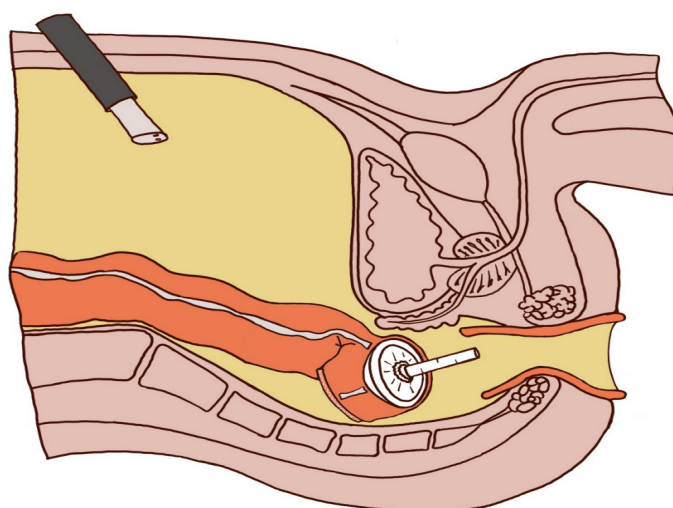
## MATERIAL and METHODS

In our clinic, between March 2013 and July 2019, 77 patients who underwent laparoscopic anterior, low anterior, total proctocolectomy, and total colectomy that all combined with NOSE were included in the study. The patients were evaluated in two groups: 44 patients with intracorporeal anvil placement and 33 patients with extracorporeal anvil placement. After detailed information was given to the patients, a detailed consent form was obtained. The selection of specimen extraction was performed according to technical suitability regarding to tumor and features. Age, sex, body mass index (BMI), comorbidities, history of operation, ASA scores, duration of operation, amount of bleeding, incision size, perioperative and postoperative complications, length of hospital stay, specimen pathology, tumor size, extracted lymph node, positive lymph node, tumor stage, visual analog scale (VAS), cosmetic score, long-term complications, presence of recurrence and overall survival parameters of the patients were evaluated. The largest size specified in the pathological reports was taken as the tumor size. The VAS scores of the patients were rated as 10 being the highest pain score, and 1 being the lowest pain score; and were evaluated during the first three days after operation without patients receiving analgesic support. The cosmetic score was rated as 10 being the best score and 1 being the worst score. During the follow-up period, the patients were contacted by phone and data on their latest status, hernia and cosmetic score were obtained. Descriptive statistics were made for all data, and reported in mean values and percentages or median and range when required. Continuous variables were analyzed by unpaired t-test or Mann Whitney U test. Categorical variables were analyzed by Chi-Square Test and Fisher-Exact Test. Statistical significance was taken as  $p < 0.05$ . Data were analyzed using SPSS 16.0 version and Microsoft Excel 2013.

After the surgical resection procedure was completed in the intracorporeal group, the proximal part was intracorporeally separated with the help of a stapler. The specimen was extracted transanally or transvaginally. Then, the anvil was sent through the extraction orifice into the abdomen. The closed stapler line in the proximal part was opened with scissors, the anvil needle was removed from the lateral wall of the proximal colon and the distal end of this colon was closed by a linear stapler. The distal rectal stump was closed again with the help of a stapler and the lateral end anastomosis was performed using a circular stapler (4). In the extracorporeal group, the proximal part of the specimen was taken out of the extraction area (through the anus or vagina) without performing intracorporeal separation, and the anvil was extracorporeally inserted into the proximal part after an extracorporeal excision. The proximal part was inserted back into the abdomen. The distal part was closed again with the help of a stapler and the anastomosis was completed with a circular stapler (5) (Figure 1-2).



**Figure 1.** Transanal colonic extraction and anvil placement



**Figure 1.** Sending anvil-placed colon into the abdomen

## RESULTS

Forty seven (61%) of the patients were male, the mean age of all patients was  $59.1 \pm 14.1$  and with a mean body mass index (BMI) of  $26.8 \pm 5.1$ . Thirty nine patients (50%) had comorbidities and 21 patients (47%) had a history of previous abdominal surgery (Table 1).

Forty seven (61%) underwent low anterior resection with 3 underwent liver metastasectomy. Anterior resection was performed in 21 patients (27%), two of whom underwent liver metastasectomy, one appendectomy, and one rectopexy procedure. Seven patients (9%) underwent total colectomy and one of them underwent subtotal gastrectomy. Total proctocolectomy J pouch-anal anastomosis was performed in two patients (2%). The mean operative time was  $329 \pm 116$  minutes and the intraoperative bleeding amount was  $72 \pm 60$  ml. Specimen extraction was performed transanally in 67 (87%) patients and transvaginally in 10 (13%) patients. Perioperative complications were observed in seven patients.

Table 1. Preoperative parameters				
Parameters		Intracorporeal (n:44)	Extracorporeal (n:33)	P
Gender (Female/Male)		16 / 28	14 / 19	0.64
Age	Mean SD	57.4±15.7	61.3±11.3	0.23
	Median (Range)	59.5 (21-79)	62 (35-77)	0.50
BMI	Mean SD	26.5±4.8 kg/m <sup>2</sup>	27.3±5.7 kg/m <sup>2</sup>	1.00
	Median (Range)	26.4 (17-34)	26.2(20.5-48.9)	0.35
ASA	Mean SD	2.0±0.5	2.0±0.7	
	Median (Range)	2 (1-3)	2 (1-3)	
Patients with co-morbidity		20 (45%)	19 (57%)	
	Diabetes mellitus	3 (6%)	7 (21%)	
	Hypertension	14 (31%)	11 (33%)	
	Chronic obstructive pulmonary disease	4 (9%)	1 (3%)	
	Periferic vascular disease	5 (11%)	6 (18%)	
	Hepatitis B virus	1 (2%)	1 (3%)	0.79
	Goiter	2 (4%)	1 (3%)	
	Chronic renal failure	1 (2%)	0 (0%)	
Patients with prior abdominal surgery		13 (29%)	8 (24%)	
	Gynecologic operation	5	2	
	Open inguinal hernia repair	2	3	
	Opening ileostomy	0	0	
	Subtotal gastrectomy	0	0	
	Cholecystectomy	2	2	0.71
	Appendectomy	3	4	
	Sigmoidectomy	2	0	
Neoadjuvant treatment		5 (11%)	7 (21%)	0.28

BMI: Body mass index

Intraabdominal bleeding was in two from the sacral venous plexus, which was stopped with compression. In one patient, the resected colon segment was opened and fecal contamination occurred. The air leakage test was positive in two patients after anastomosis and supportive sutures were added in these areas. The operation was terminated when no leakage was detected in the air control test. One patient had a ureteral injury and was laparoscopically repaired with a double-j stent. In one patient, the rectal

stump, which was closed with the help of a stapler, was opened during anastomosis and closed again with the help of a stapler, and anastomosis was performed. When the two groups were compared, there was no difference in terms of intraoperative and postoperative complications. No difference was detected in postoperative early VAS values except the first day. The VAS values were found to be lower on the first day in the intracorporeal group (3.3±2.1 vs 4.4±2.3, p=0.03) (Table 2).

Table 2. Intraoperative and postoperative outcomes

Parameters	Intracorporeal (n:44)	Extracorporeal (n:33)	P
<b>Operation type</b>			
LAR	15	29	0.0001
+Liver metastasectomy	2	1	1.00
Anterior resection	15	2	0.004
+ Liver metastasectomy	2	0	0.50
+ Rectopexy	1	0	1.00
+ Appendectomy	1	0	1.00
Total proctocolectomy	1	1	1.00
Total colectomy	6	0	0.03
+ Subtotal gastrectomy	1	0	1.00
Ileostomy	2 (4%)	3 (9%)	0.42
Extraction Type	39/5	28/5	0.73
NOSE (TA/TV)	1 (2%)	1 (3%)	
Circular stapler size (mm)	30.7±1.4 31 (28-33)	30.4±1.5 31 (28-33)	1.00
<b>Duration of surgery</b>			
Mean SD	329±127 minutes	329±96 minutes	
Median (Range)	300 (120-600)	296 (180-540)	0.93
<b>Intraoperative bleeding</b>			
Mean SD	72±67 ml.	71±25 ml.	
Median (Range)	50 (5-300)	60 (40-100)	
Intraoperative complications	4 (9%)	3 (9%)	1.00
Fecal contamination	1	0	
Bleeding	1	1	
Air leak test (+)	2	0	
Ureteral injury	0	1	
Rectal stump opened	0	1	
Doughnuts not intact	0 (0%)	3 (9%)	0.04
Postoperative complications	15 (34%)	16 (48%)	0.24
<b>Intraabdominal complications</b>			
Bleeding	1	2	
Abscess * #	3	1	
Anastomotic leakage#	3	3	
Anastomotic stenosis	1	3	
Rectovaginal fistula	1	2	
Ileostomy prolapse	0	0	
Paralytic ileus	2	2	

Biliary fistula	0	0	
Chylous fistula	1	0	
<b>Extraabdominal complications</b>			
Atelectasis	1	2	
Wound infection *	2	1	
Urinary infection	1	2	
Pneumonia	1	0	
Pleural effusion	1	0	
Reoperation	1 (2%)	3 (9%)	0.18
Bleeding	0	2	
Anastomotic leakage	1	1	
<b>VAS score (total)</b>			
Mean SD	2.5±1.9	3.1±2.0	
Median (Range)	2 (0-8)	3 (0-9)	0.18
<b>VAS score on day 1</b>			
Mean SD	3.3±2.1	4.4±2.3	
Median (Range)	3.5 (0-8)	3 (2-9)	0.03
<b>VAS score on day 2</b>			
Mean SD	2.5±1.8	3.0±0.9	
Median (Range)	2 (0-8)	3 (2-5)	0.14
<b>VAS score on day 3</b>			
Mean SD	1.6±1.5	2.0±1.6	
Median (Range)	1.5 (0-5)	1 (0-5)	0.26
<b>Length of hospital stay</b>			
Mean SD	8.7±6.8 days	9.3±6.2 days	
Median (Range)	6.5 (3-28)	8 (3-27)	0.69
<b>Cosmetic score</b>			
Mean SD	9.3±1.1	9.4±1.0	
Median (Range)	10 (7-10)	10 (6-10)	0.68
Recurrence <sup>^</sup>	5 (11%)	3 (9%)	1.00
Perioperative mortality	1 (2%)	0 (0%)	0.38
Life with stoma	1 (2%)	4 (12%)	0.08
<b>Duration of follow-up</b>			
Mean SD	25.8±21.5 months	48.4±21.1 months	
Median (Range)	23 (1-79)	54 (9-80)	0.0001

TA: transanal, TV: transvaginal

\* Abdominal abscess nad wound infection in the same patients

# Anastomotic leakage and abdominal abscess in the same patients

<sup>^</sup> Statistics were made among tumor patients

Table 3. Pathology of the malignancies			
	Intracorporeal (n:25)*	Extracorporeal (n:29)*	P
<b>T</b>			
Tis	1	0	0.46
T1	1	1	1.00
T2	1	8	0.02
T3	17	18	0.77
T4 (a-b)	5 (5-0)	2 (2-0)	0.22
<b>N</b>			
0	9	17	0.11
1 (a-b-c)	9 (3-6-0)	9 (5-3-1)	0.77
2 (a-b)	7 (2-5)	3 (0-3)	0.15
<b>M</b>			
0	19	26	0.27
1 (a-b)	6 (4-2)	3 (3-0)	0.27
<b>Stage</b>			
0	1	0	0.46
1	2	8	0.08
2 (a-b-c)	6 (6-0-0)	7 (7-0-0)	1.00
3 (a-b-c)	10 (0-6-4)	11 (1-7-3)	1.00
4 (a-b)	6 (4-2)	3 (3-0)	0.27
<b>Tumor size</b>			
Mean SD	3.9±1.7	4.0±1.5	
Median (Range)	3.5 (1.3-8)	4 (1-9)	
<b>Removed lymph node (Total)</b>			
Mean SD	24.1±25.3	17.1±10.9	
Median (Range)	17 (4-113)	17 (0-49)	
<b>Positive lymph node</b>			
Mean SD	3.6±5.0	1.9±4.7	
Median (Range)	2 (0-19)	0 (0-13)	
* Statistics were made among tumor patients			

Anastomotic leakage was observed in 6 patients (8%). 3 of these patients were in the intracorporeal group and 3 were in the extracorporeal group. Two patients in the extracorporeal group required postoperative reoperation. One of these patients underwent end colostomy and drainage procedures and the other patient underwent diverting ileostomy. The other patients were conservatively followed up and no additional surgical intervention was needed. Transanal abscess drainage was performed for one of two patients in the intracorporeal group and the other was conservatively followed. Three patients (9%) in the extracorporeal group had anal stenosis in the late-period. Treatment could not be achieved in two of these patients despite repeated anal dilatation, and colostomy was required. The other patient was treated with anal dilatation. Anal stenosis was seen in one patient in the intra-corporeal group and was treated with dilatation. When the pathology results were examined, the pathology of 54 (70%) patients was reported as adenocarcinoma. One patient, in each group, underwent resection due to surgical margin positivity in the pathology of polypectomy. However, the pathological examination did not reveal any tumor focus. Four patients (5%) were operated on due to sigmoid volvulus and their pathologies were reported as mucosal edema. One patient had sigmoid diverticulum and the resection pathology was reported as diverticulosis. The pathology specimen of one patient with rectal prolapse was reported as mucosal congestion. The pathologies of other patients were reported as polyposis coli and villous adenoma. The mean tumor size was found to be 3.9±1.6 cm. The mean total extracted lymph node was 20.3±19.3, while the mean positive lymph node was 2.7±4.9. When tumor stages were examined, it was seen that 9 (16%) tumors were at stage 4, 21 (39%) at stage 3, 13 (25%) at stage 2, 10 (18%) at stage 1, and 1 (2%) at stage 0. The pathology results of the two groups are given in Table 3 comparatively.

One patient died in the early postoperative period. This patient, who was in the intracorporeal group, had a rectum tumor and a colostomy was opened due to anastomosis leakage on the postoperative 4th day. The patient was lost due to respiratory failure on the postoperative 27th day. The total late period mortality rate was 12%. The mean follow-up period of the patients was 35.5±24.1 months. The recurrence rate was 10% when evaluated in tumor patients. Of the patients with recurrence, two (3%) had liver metastasis, two (3%) had lung metastasis and the others (7%) had an intra-abdominal recurrence.

## DISCUSSION

With the advances in minimally invasive surgery over the past two decades, the advantages of laparoscopy have become more evident. This advancement has also affected colorectal surgery, and extraction area and related complications were minimized with NOSE. In the NOSE surgery combined with distal colorectal surgery, the transanal route is often used as the extraction site, while the transvaginal route is used for the extraction

of large tumors, and proximal diseases. However, no consensus has been reached in terms of anastomosis form and anvil insertion. It has been observed in the literature that there is a variety in terms of the number of staplers and anvil insertion techniques, but that pelvic anatomy and meso length are generally ignored (6). As stated in the consensus on NOSE colorectal surgery in 2019, the placement technique of stapler anvils changes depending on the extraction site, tumor location and the length of mesocolon (1). Apart from the sites where both anvil placement methods should be used separately, there are cases where both methods can be preferred. Intracorporeal anvil placement technique can be utilized using the eversion method for a suitable disease with a distal placement, while extracorporeal anvil placement can be made after transvaginal or transanal luminal extraction. Here, the main determinants are tumor location and wall invasion, meso length and pelvic anatomy of the patient. The aim of this study is not to compare the two techniques on each patient and suggest the right technique, but to investigate the existing problems of these two techniques and to emphasize that there are two options that can be used in suitable patients.

One of the main difficulties of intracorporeal anvil placement is sending the anvil into the abdomen and placing it into the proximal bowel (7). Teams that sent the anvil using stapler's shaft and placed it to the proximal bowel (8) as well as teams that sent the anvil only through transanal, transcolonic or transvaginal routes and intracorporeally placed it, are reported in the literature in this regard. In our study, while the stapler shaft was generally used to send the anvil into the abdomen, both techniques were used to place it into the colon. It is predicted that this stage may prolong the operation time. However, no difference was found between the two groups in terms of operation time. Additionally, it was determined that the number of surgical procedures that prolong the operation time (combined resections, total colectomy) was high in the intracorporeal group.

Difficulties in extracorporeal anvil placement are anastomosis complications and inadequate resection that may occur due to the extraction of the proximal intestine without resecting. In our study, no difference was found between the two groups in terms of anastomosis complications, pathology parameters, tumor recurrence, and mortality. In a study performed by Park et al. where NOSE (anvil was placed extra-corporeally) and conventional laparoscopic rectal surgery were compared, anastomotic leakage (6.5%) and pathological results were found to be similar (9). It was determined in our study that the anastomotic leakage rate was 8% and similar to that reported in the literature. However, the fact that combined resections are present in our study shows that this rate is in the more acceptable range. In another study where NOSE and conventional laparoscopy were compared and anvil was placed intracorporeally, it was found that there was no difference between the two groups in terms of these criteria (10).

One of the problems encountered in intracorporeal anvil placement is that the anvil transports transcolonic fecal contents into the abdomen, thus increasing the rate of intraabdominal infection in the transanal extraction group. In our study, no difference was found between the two groups in terms of intraabdominal infection and wound infections. Intracorporeal and extracorporeal anvil placement studies showed similar intraabdominal abscess rates, which were in the range of 1-3% (9,11,12). In a meta-analysis that compiled anastomosis techniques used in NOSE surgery in the literature, no difference was found in terms of infectious complications (6).

## CONCLUSION

In NOSE colorectal surgery where circular stapler anastomosis is used, anvil placement techniques are not interchangeable. It is seen that neither method predominates the other in cases where both are suitable.

*Competing interests: The authors declare that they have no conflict of interest.*

*Financial Disclosure: There is not any sources of financial assistance.*

*Ethical approval: Inonu University Ethics Committee (2019/448) gave consent.*

*Ersin Gundogan, ORCID: 0000-0002-3046-9040*

*Cuneyt Kayaalp, ORCID: 0000-0003-4657-2998*

## REFERENCES

1. Guan X, Liu Z, Longo A, et al. International consensus on natural orifice specimen extraction surgery (NOSES) for colorectal cancer. *Gastroenterol Rep (Oxf)* 2019;7:24-31.
2. Wolthuis AM, Fieuws S, Van Den Bosch A, et al. Randomized clinical trial of laparoscopic colectomy with or without natural-orifice specimen extraction. *Br J Surg* 2015;102:630-7.
3. Hisada M, Katsumata K, Ishizaki T, et al. Complete laparoscopic resection of the rectum using natural orifice specimen extraction. *World J Gastroenterol* 2014;20:16707-13.
4. Kayaalp C, Yagci MA, Soyer V. Laparoscopic and natural orifice transluminal restorative proctocolectomy: no abdominal incision for specimen extraction or ileostomy. *Videosurgery Miniinv* 2016; 11: 115-20.
5. Kayaalp C, Yagci MA, Sumer F. Transanal extracorporeal anvil fixation to the proximal colon during laparoscopic rectal resection. *Asian J Endosc Surg* 2015;8:226.
6. Wolthuis AM, Van Geluwe B, Fieuws S, et al. Laparoscopic sigmoid resection with transrectal specimen extraction: a systematic review. *Colorectal Dis* 2012;14:1183-8.
7. Alam AH, Soyer V, Sabuncuoglu MZ, et al. Natural orifice specimen extraction (NOSE) and transanal extracorporeal anvil placement during laparoscopic low anterior resection. *Tech Coloproctol* 2014;18:669-71.
8. Fleshman JW, Brunt LM, Fry RD, et al. Laparoscopic anterior resection of the rectum using a triple stapled

- intracorporeal anastomosis in the pig. Surg Laparosc Endosc 1993;3:119-26
9. Park JS, Kang H, Park SY, et al. Long-term outcomes after Natural Orifice Specimen Extraction versus conventional laparoscopy-assisted surgery for rectal cancer: a matched case-control study. Ann Surg Treat Res 2018;94:26-35.
  10. Xingmao Z, Haitao Z, Jianwei L, et al. Totally laparoscopic resection with natural orifice specimen extraction (NOSE) has more advantages comparing with laparoscopic-assisted resection for selected patients with sigmoid colon or rectal cancer. Int J Colorectal Dis 2014;29:1119-24.
  11. Saurabh B, Chang SC, Ke TW, et al. Natural Orifice Specimen Extraction With Single Stapling Colorectal Anastomosis for Laparoscopic Anterior Resection: Feasibility, Outcomes, and Technical Considerations. Dis Colon Rectum 2017;60:43-50.
  12. Kim HJ, Choi GS, Park JS, et al. Transvaginal specimen extraction versus conventional minilaparotomy after laparoscopic anterior resection for colorectal cancer: mid-term results of a case-matched study. Surg Endosc 2014;28:2342-8.