

ST Segment Elevation Caused by Pericarditis: A Case Report

ST Segment Yükselmesine Neden Olan Akut Perikardit: Olgu Sunumu

Seval Demir Aydın¹, Muhammet Gökhan Turtay¹, Şükrü Gürbüz¹, Hasan Pekdemir², Hakan Oğuztürk¹, Taner Güven¹

¹İnönü University Faculty of Medicine, Department of Emergency Medicine, Malatya, Turkey

²İnönü University Faculty of Medicine, Department of Cardiology, Malatya, Turkey



Keywords

Pericarditis, ST segment elevation, troponin, thrombolytic

Anahtar Kelimeler

Perikardit, ST segment elevasyonu, troponin, trombolitik

Received/Geliş Tarihi : 02.12.2015

Accepted/Kabul Tarihi : 03.02.2016

doi:10.4274/meandros.1886

Address for Correspondence/Yazışma Adresi:

Şükrü Gürbüz MD,
İnönü University Faculty of Medicine,
Department of Emergency Medicine, Malatya,
Turkey

Phone : +90 532 451 28 99

E-mail : sukругurbuz@gmail.com

Presented in: 20th National Emergency Medical Congress.

©Meandros Medical and Dental Journal, Published by Galenos Publishing House.

This is article distributed under the terms of the Creative Commons Attribution NonCommercial 4.0 International Licence (CC BY-NC 4.0).

Abstract

Chest pain is one of the common reasons for admission to the emergency department and an important symptom that can be a precursor of a fatal condition. A simple muscle pain can be a sign of illnesses until myocardial infarction or even aortic dissection, which is more lethal. In this respect, electrocardiogram (ECG) which is of critical importance in the evaluation of patients is a guide for us. However, starting treatments such as thrombolytic therapy that is solely considered according to ECG may be a wrong decision. Therefore, detailed investigations should be made for establishing a diagnosis and treatment plans should be made accordingly. In this paper, we present a 19-year-old male patient who was admitted to our emergency department with chest pain, having ST segment elevation of D2, D3 and aVF in ECG along with troponin elevation and was diagnosed with acute pericarditis.

Öz

Göğüs ağrısı acil servise sık başvuru nedenlerinden biridir ve ölümcül hastalıkların habercisi olması nedeni ile önemli bir semptomdur. Basit bir kas ağrısından miyokard enfarktüsüne ya da daha ölümcül olan aort diseksiyonuna kadar hastalıkların habercisi olabilir. Bu açıdan hastaların değerlendirilmesinde kritik öneme sahip elektrokardiyogram (EKG) bize yol göstericidir. Ancak EKG'ye bakılarak tanı konulup trombolitik tedavi başlamak yanlış tedavi olabilir. Bu yüzden hastaların tanısında detaya inilmeli ve tedavi planı buna göre yapılmalıdır. Bu olgu sunumunda; acil servisimize göğüs ağrısı şikayeti ile başvuran, çekilen EKG'sinde D2, D3 ve aVF derivasyonlarında ST segment elevasyonu ve troponin yüksekliği olan akut perikardit tanısı alan 19 yaşındaki erkek hastayı sunmayı amaçladık.

Introduction

Chest pain is an important symptom among the warning signs of fatal conditions, and particular attention should be paid in the differential diagnosis. Electrocardiogram (ECG) is a guiding method in ruling out fatal conditions and for early diagnosis and treatment. The conditions characterized by ST segment elevation include possibly fatal acute myocardial infarction, left branch block, left ventricular hypertrophy,

and pericarditis. However, chest pain accompanied by ST segment elevation on ECG should primarily suggest the possibility of acute myocardial infarction. ECG and serial monitoring of cardiac enzymes, echocardiography (ECO), radiological investigations, and coronary angiography (CAG) must be performed in the differential diagnosis. ST segment elevation on ECG can also be observed in acute pericarditis, however, thrombolytic therapy is contraindicated in acute pericarditis (1). The aim of the current report was to present a case of acute pericarditis in a patient who presented with ST segment elevation and elevated cardiac enzymes and in whom thrombolytic therapy was contraindicated.

Case Report

A 19-year-old male patient was admitted to the emergency room with the complaint of intermittent chest pain that started one day ago and gradually worsened. The patient reported chest pain and back pain that increased in the supine position. The patient's vital findings and physical examination were normal. Pericardial friction rub was not heard. ECG revealed ST segment elevation in leads D1, D2, aVL, aVF, V3, V4, V5, and V6 (Figure 1). Posteroanterior chest radiograph was normal (Figure 2). Troponin 1 was found to be 10 ng/mL, after which the patient underwent CAG that showed normal findings (Figure 3, 4). The results of the laboratory tests were as follows: aspartate aminotransferase: 184 U/L, lactate dehydrogenase: 715 U/L, creatine kinase (CK): 2190 U/L, CK-MB: 248 U/L, and C-reactive protein (CRP): 11 mg/dL. Other laboratory tests were normal. ECO revealed normal findings other than minimal pericardial effusion. Dynamic computed tomography of the thorax and abdomen performed for the differential diagnosis revealed normal findings. The serial troponin monitoring revealed an elevation in troponin levels up to 34.3 ng/mL. The patient was considered to have acute pericarditis due to the presence of typical chest pain, elevated CRP levels, and minimal pericardial effusion on echo. The patient was transferred to the coronary intensive care unit and non-steroidal anti-inflammatory drugs (NSAIDs) were administered. During the follow-up, cardiac enzyme levels declined and chest pain decreased. The patient was then discharged with full recovery.

Discussion

Chest pain is an important symptom associated with acute coronary syndrome (ACS) and should be considered in the differential diagnosis. The underlying cause of chest pain should be recognized based on ECG, cardiac biomarkers, and the results of imaging methods before instituting any therapy (2).

Acute pericarditis is one of the reasons for chest pain and ECG changes. It is characterized by a substernal chest pain radiating to the back, neck, and shoulder that increases when lying down or breathing and decreases when seated and bending forward (3). The current case had chest pain and back pain that increased when lying down.

Acute pericarditis can manifest with ST segment elevation and PR segment depression on ECG (3). There are reports in the literature on cases with acute pericarditis that had ST segment elevation in leads V2-6, D1, D2, and aVL and normal findings on CAG (4).

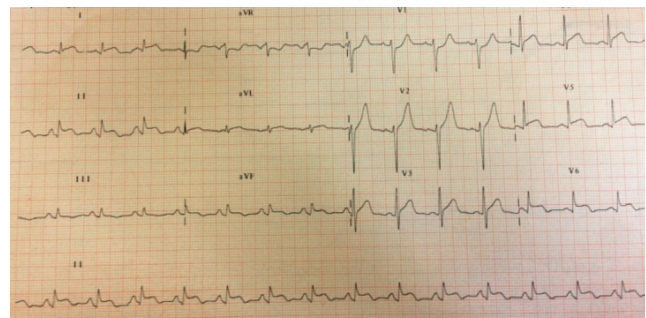


Figure 1. ST segment elevation in leads D1, D2, aVL, aVF, V3, V4, V5, V6

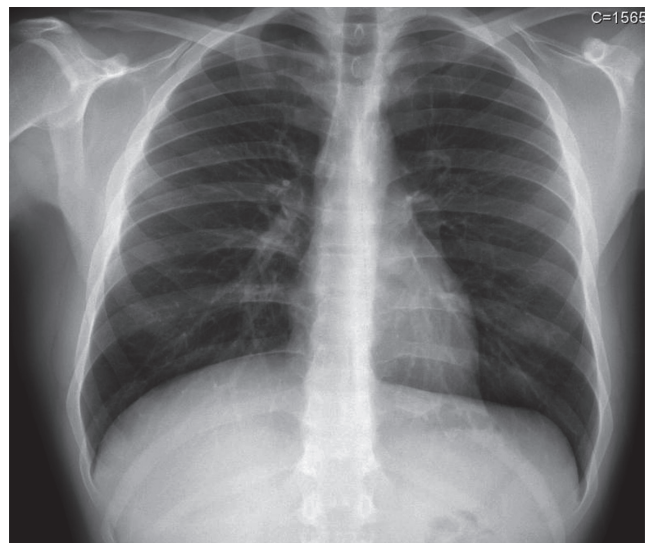


Figure 2. Normal chest radiography findings

The current case also had ST segment elevation on ECG, and CAG revealed normal findings.

The myocardial involvement is manifested by elevated CK-MB and troponin levels (3). Cardiac markers were found to be elevated in the current case. The diagnosis of myocarditis was ruled out due

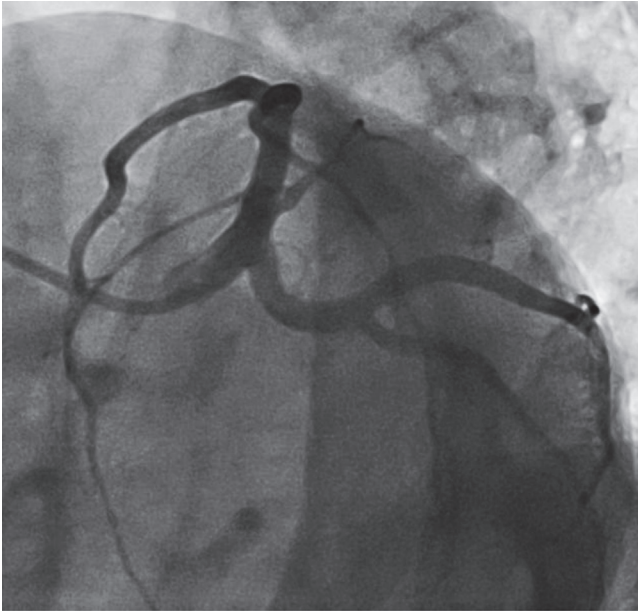


Figure 3. Normally left coronary artery findings in coronary angiography

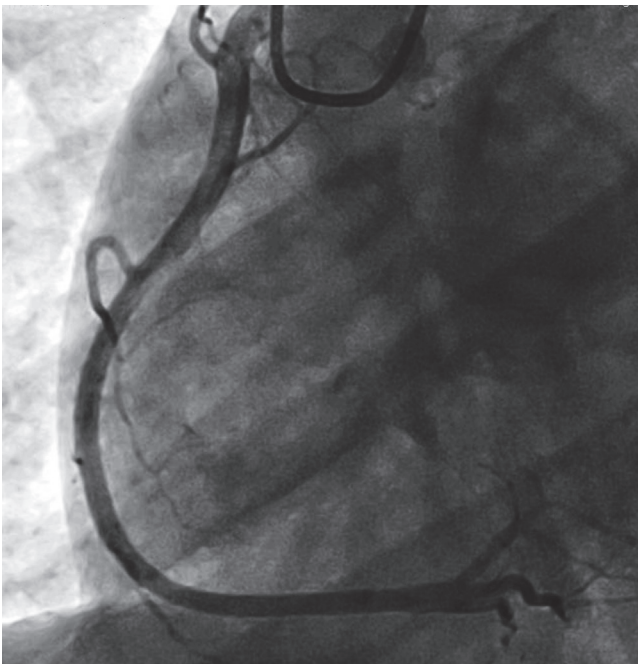


Figure 4. Normally right coronary artery findings in coronary angiography

to normal ventricular function and lack of local or diffuse wall motion abnormality on echo.

Echo represents the most sensitive and specific method in detecting pericardial effusion observed in acute pericarditis. However, pericarditis can occur even in the absence of pericardial fluid collection (5). In the current case, echo revealed normal findings with the exception of minimal pericardial effusion.

Acute pericarditis often exhibits a benign disease course. The treatment is mostly based on the underlying cause. These patients largely benefit from therapies involving NSAIDs (6). The prognosis is mostly based on the underlying reason, however, in contrast with ACS, elevated troponin levels are not an unfavorable prognostic factor in pericarditis (7). The current case also had elevated troponin levels, and the symptoms disappeared with NSAIDs and the patient was discharged with full recovery.

It must be kept in mind that ST segment elevation and elevated troponin levels in patients presenting to the emergency room with chest pain can be a sign for the underlying acute pericarditis, and thrombolytic therapy administered in acute myocardial infarction is contraindicated in pericarditis.

Ethics

Informed Consent: Consent form was filled out by all participants.

Peer-review: Externally and internally peer-reviewed.

Authorship Contributions

Surgical and Medical Practices: H.P., **Concept:** T.G., **Design:** M.G.T., **Data Collection or Processing:** S.D.A., **Analysis or Interpretation:** Ş.G., **Literature Search:** T.G., H.P., S.D.A., H.O., **Writing:** M.G.T.

Conflict of Interest: No conflict of interest was declared by the authors.

Financial Disclosure: The authors declared that this study received no financial support.

References

1. Aronow WS. Myocardial infarction in the elderly: benefits and risks of thrombolytics. *Drug Saf* 2002; 25: 753-8.
2. Schnabel RB, Post F, Blankenberg S. Diagnosis of acute coronary syndrome. *Dtsch Med Wochenschr* 2014; 139(Suppl 1): S9-12.
3. Hooper AJ, Celenza A. A descriptive analysis of patients with an emergency department diagnosis of acute pericarditis. *Emerg Med J* 2013; 30: 1003-8.

4. Inanç M, Akpek M, Inanç MT, Kaya MG. Acute pericarditis during 5-fluorouracil, docetaxel and cisplatin therapy. *Turk Kardiyol Dern Ars* 2012; 40: 532-5.
5. Oh JK, Hatle LK, Seward JB, Danielson GK, Schaff HV, Reeder GS, et al. Diagnostic role of Doppler echocardiography in constrictive perikarditis. *J Am Coll Cardiol* 1994; 23: 154-62.
6. Elmahy H, Abdelbar A, Schmitt M. Striking temporally dynamic ECG changes associated with recurrent chest pain in a case of myopericarditis. *BMJ Case Rep* 2013.
7. Imazio M, Brucato A, Barbieri A, Ferroni F, Maestroni S, Ligabue G, et al. Good prognosis for pericarditis with and without myocardial involvement: results from a multicenter, prospective cohort study. *Circulation* 2013; 128: 42-9.