



## Therapeutic effects of melatonin and quercetin on carbon tetrachloride-induced cardiac damage in rats

### Siçanlarda karbon tetraklorür ile indüklenen kardiyak hasar üzerine melatonin ve quercetin'in tedavi edici etkileri

Hulya Elbe<sup>1</sup>, Mukaddes Esrefoglu<sup>2</sup>, Asli Taslidere<sup>3</sup>, Elif Taslidere<sup>2</sup>, Burhan Ates<sup>4</sup>

<sup>1</sup>Mugla Sıtkı Kocman University, Faculty of Medicine, Department of Histology and Embryology, Mugla, Turkey

<sup>2</sup>Bezmialem Vakif University, Faculty of Medicine, Department of Histology and Embryology, Istanbul, Turkey

<sup>3</sup>İnönü University, Faculty of Medicine, Department of Histology and Embryology, Malatya, Turkey

<sup>4</sup>İnönü University, Faculty of Science and Art, Department of Chemistry, Malatya, Turkey

#### Abstract

**Aim:** Carbon tetrachloride (CCl<sub>4</sub>) is a potent, lipid-soluble toxic agent and produces peroxidative degeneration in many tissues. In this study, antioxidative effects of melatonin and quercetin were evaluated by histological and biochemical methods in CCl<sub>4</sub>-induced cardiac damage.

**Materials and Method:** 35 rats were divided into equally 5 groups: control, olive oil, CCl<sub>4</sub>, CCl<sub>4</sub>+Melatonin, and CCl<sub>4</sub>+Quercetin. At the end of the study hearts tissues were processed by rutin histological and biochemical procedures.

**Results:**The histological appearance of control and olive oil groups were normal. However, histopathological alterations such as vacuolization and necrosis of cardiocytes, vascular congestion, hemorrhage, infiltration and fibrosis were observed in the CCl<sub>4</sub> group. Significant increase in histopathological scoring was detected in CCl<sub>4</sub> group when compared with the control and olive oil groups. Furthermore, histopathological changes were markedly reduced in CCl<sub>4</sub>+Melatonin, and CCl<sub>4</sub>+Quercetin. The tissue MDA levels of CCl<sub>4</sub> group were significantly increased in comparison with the control and olive oil groups. In treatment groups, MDA levels were significantly lower than that of the CCl<sub>4</sub> group. The tissue GSH levels and SOD activities were significantly decreased when compared with the control and olive oil groups. Melatonin and quercetin administrations resulted in significant increases in GSH levels and SOD activities.

**Conclusion:** We concluded that cardiac damage induced by CCl<sub>4</sub> toxicity is prevented by melatonin and quercetin administrations via antioxidative properties.

**Keywords:** Carbon Tetrachloride; Cardiac Damage; Melatonin; Quercetin.

#### Öz

**Amaç:** Karbontetraklorür (CCl<sub>4</sub>) potent, lipidde çözülebilir toksik bir ajandır ve çoğu dokuda peroksidatif değişikliklere neden olur. Bu çalışmada, CCl<sub>4</sub> ile indüklenen kalp hasarında melatonin ve quercetin'in antioksidatif etkileri histolojik ve biyokimyasal yöntemler yoluyla incelendi.

**Gereç ve Yöntem:** 35 adet siçan eşit olarak 5 gruba ayrıldı. Kontrol, zeytinyağı, CCl<sub>4</sub>, CCl<sub>4</sub>+Melatonin ve CCl<sub>4</sub>+Quercetin. Deney sonunda kalp dokuları rutin histolojik ve biyokimyasal prosedürlerden geçirildi.

**Bulgular:** Kontrol ve zeytinyağı gruplarının histolojik görüntüsü normaldi. CCl<sub>4</sub> grubunda ise; kardiyositlerde vakuolizasyon ve nekroz, vasküler konjesyon, hemoraji, infiltrasyon ve fibrozis gibi histopatolojik bulgular gözlemlendi. Kontrol ve zeytinyağı gruplarıyla karşılaştırıldığında, CCl<sub>4</sub> grubunun histopatolojik skorunda anlamlı bir artış tespit edildi. Diğer yandan, histopatolojik değişiklikler CCl<sub>4</sub>+Melatonin ve CCl<sub>4</sub>+Quercetin gruplarında önemli ölçüde geriledi. CCl<sub>4</sub> grubunun doku MDA düzeyleri kontrol ve zeytinyağı grupları ile karşılaştırıldığında anlamlı derecede artmıştı. Tedavi gruplarının MDA düzeyleri CCl<sub>4</sub> grubundan anlamlı derecede düşüktü. Kontrol ve zeytinyağı grupları ile karşılaştırıldığında doku GSH düzeyleri ve SOD aktivitesi anlamlı derecede azalmıştı. Melatonin ve quercetin uygulamaları GSH düzeylerinde ve SOD aktivitesinde anlamlı artışlarla sonuçlandı.

**Sonuç:** CCl<sub>4</sub> toksitesinde oluşan kalp hasarının, antioksidatif özellikleri vasıtasıyla melatonin ve quercetin uygulamaları ile önlenebileceğini düşünmekteyiz.

**Anahtar Kelimeler:** Karbon Tetraklorür; Kardiyak Hasar; Melatonin; Quercetin.

Received/Başvuru: 25.11.2015  
Accepted/Kabul: 23.03.2016

#### Correspondence/İletişim

Hulya Elbe  
Mugla Sıtkı Kocman University,  
Faculty of Medicine,  
Department of Histology and  
Embryology, Muğla, Turkey  
E-mail: hulya.elbe@mu.edu.tr

#### For citing/Atıf için

Elbe H, Esrefoglu M, Taslidere A, Taslidere E, Ates B. Therapeutic effects of melatonin and quercetin on carbon tetrachloride-induced cardiac damage in rats. J Turgut Ozal Med Cent 2016;23(2):171-6.

## INTRODUCTION

It is suggested that oxidative damage induced by reactive oxygen species (ROS) and subsequent cell death is implicated in the pathogenesis of several diseases, including Alzheimer's disease, diabetes mellitus, liver cirrhosis and human hepatocellular carcinoma (1-3). Excessive production of free radicals and oxidative stress can be induced by a variety of factors such as ionizing radiation or exposure to drugs and xenobiotics [e.g. carbon tetrachloride (CCl<sub>4</sub>)] (4). CCl<sub>4</sub> is a common industrial solvent and potent, lipid-soluble toxic agent that, when bound to lipid and protein, produces peroxidative degeneration of many tissues (5, 6). The fundamental structure of the heart of rats and humans is similar, so administration of CCl<sub>4</sub> to rats is an accepted experimental model to produce damage to cardiac and other tissues.

Melatonin (*N*-acetyl-5-methoxytryptamine) is an indoleamine secreted by the pineal gland, retina, and other vertebrate tissues with a daily rhythmical peak in the dark phase (7, 8). Melatonin has been shown to exhibit a variety of physiological functions including the control of seasonal reproduction, thermoregulation, energy metabolism, circadian rhythm regulation and sleep control. It has direct radical scavenging activity and indirect antioxidant effects (8, 9). Quercetin, one of the most widely distributed flavonoids of fruits and vegetables, is capable of radical scavenging, preventing lipid damage and reducing lipid hydroperoxide (10).

The benefit of certain substances containing antioxidants can be evaluated by assessing their protective potency against the CCl<sub>4</sub>-induced alterations in lipid peroxide, and antioxidant status as well as histopathological picture of organs. In this study we evaluated the protective capacity of melatonin and quercetin against oxidative stress-induced by CCl<sub>4</sub>. Therefore the present study was designed to evaluate the probable protective effect of melatonin and quercetin on CCl<sub>4</sub>-induced damage in the heart of Wistar rats. To our knowledge, this is the first microscopic study evaluating the effects of melatonin and quercetin on CCl<sub>4</sub>-induced cardiac damage.

## MATERIALS and METHODS

### Animals

Thirty-five female Wistar albino rats (3-4 months old) weighing 220-240 g obtained from the Experimental Animal Research Center of Inonu University were used in the present study. The animals were housed in individual cages for 10 days in a well ventilated room with a 12: 12-hour light/dark cycle at 21°C. Animals were fed with standard rat chow and tap water *ad libitum*. The experiments were performed in accordance with the Guidelines for Animal Research from National Institute of Health and were approved by the Committee on Animal Research at Inonu University, Malatya, Turkey.

### Experimental design

Rats were divided into 5 groups each of containing 7 rats as follows: Control group: (administered by 5%

ethanol, 1 ml/day/ip), Olive oil group (administered by olive oil, 0.5 ml/every other day/ip), CCl<sub>4</sub> group (administered by 0.5 ml/kg CCl<sub>4</sub> dissolved in 0.5 ml/kg olive oil, during 10 days/every other day/ip), CCl<sub>4</sub>+Melatonin (CCl<sub>4</sub>+M) (10 mg/kg/day/ip melatonin injected 24 hours after administration of CCl<sub>4</sub>, during 10 days) CCl<sub>4</sub>+Quercetin (CCl<sub>4</sub>+Q) group (25 mg/kg/day/ip quercetin injected 24 hours after administration of CCl<sub>4</sub>, during 10 days). Melatonin and quercetin were prepared by dissolving in 5% ethanol. CCl<sub>4</sub> was prepared by dissolving in olive oil. At the end of the study, the rats were sacrificed by ketamine anesthesia and hearts were removed. One part of the samples were used for histopathological examination whereas the others were used for evaluation of tissue oxidative stress parameters by biochemical methods.

### Histopathological evaluations

The heart tissues were fixed in 10% formalin and embedded in paraffin. Paraffin blocks were cut at 5 µm and stained with hematoxylin-eosin (H-E) and Masson's trichrome. The sections were examined for the alterations including vacuolization and necrosis of cardiocytes, vascular congestion, hemorrhage, infiltration and fibrosis indicating cardiac injury. Each alterations was scored as follows: 0= normal, 1= mild, 2= moderate and 3= severe, with a maximum score of 18. Samples were examined using a Leica DFC280 light microscope and a Leica Q Win Image Analysis system (Leica Micros Imaging Solutions Ltd., Cambridge, UK).

### Biochemical evaluations

Tissues were homogenized (PCV Kinematica Status Homogenizator) in ice-cold phosphate buffered saline (pH 7.4). The homogenate was sonified with an ultrasonifier (Bronson sonifier 450) by 3 cycles (20-s sonications and 40-s pause on ice). The homogenate was centrifuged (15.000 xg, 10 min, 4 °C) and cell-free supernatant was subjected to enzyme assay immediately. SOD (Cu, Zn-SOD) activity in the supernatant fraction was measured using xanthine oxidase/cytochrome c method where 1 unit (U) of activity is the amount of enzyme needed to cause half-maximal inhibition of cytochrome c reduction (11). The amount of SOD in the extract was determined as U of enzyme mg<sup>-1</sup> protein, utilizing a commercial SOD as the standard. The formation of 5-thio-2-nitrobenzoate (TNB) is followed spectrophotometrically at 412 nm (12). The amount of GSH in the extract was determined as nmol/mg protein utilizing a commercial GSH as the standard. The analysis of lipid peroxidation was carried out as described with a minor modification (13). The reaction mixture was prepared by adding 250 µL homogenate into 2 ml reaction solution (15% trichloroacetic acid: 0.375% thiobarbituric acid: 0.25 N HCl, 1:1:1, w/v) and heated at 100°C for 15 min. The mixture was cooled to room temperature, centrifuged (10.000 g for 10 min) and the absorbance of the supernatant was recorded at 532 nm. 1,1,3,3-tetramethoxypropane was used as MDA standard. MDA results were expressed as nmol mg<sup>-1</sup> protein in the homogenate. Protein levels of the tissue samples were measured by the Bradford method (14). The absorbance measurement was taken at 595 nm using a UV-VIS

spectrophotometer. Bovine serum albumin (BSA) was used as protein standard.

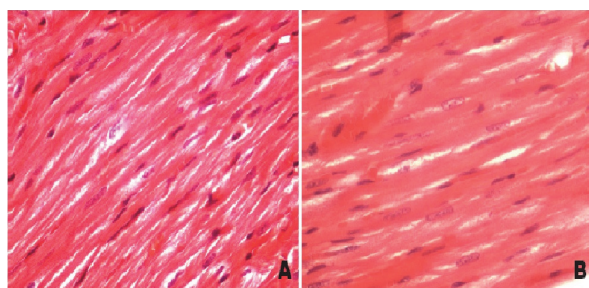
### Statistical analysis

Statistical analysis was carried out using the SPSS for Windows version 13.0 (SPSS Inc., Chicago, Ill., USA) program. All data are expressed as arithmetic mean±Standard error (SE). Normality for continued variables in groups were determined by the Shapiro Wilk test. Since the variables didn't show normal distribution Kruskal-Wallis and Mann Whitney U tests were used for comparison of variables among the studied groups.  $p < 0.05$  was regarded as significant.

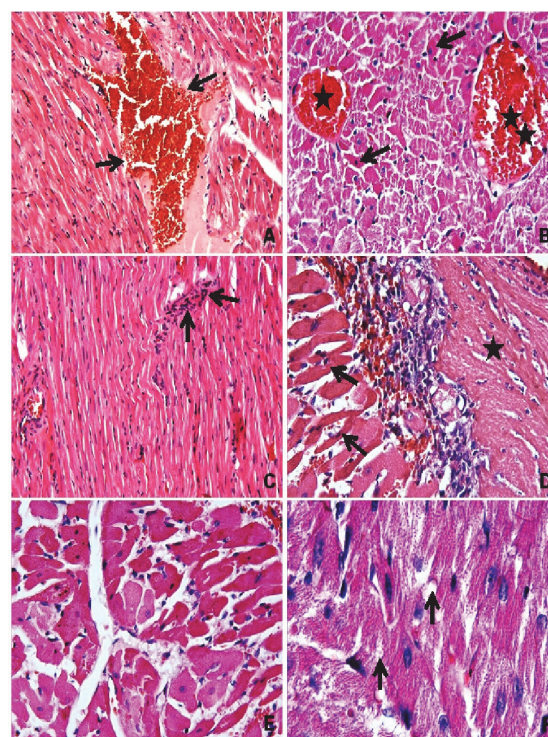
## RESULTS

### Histopathological findings

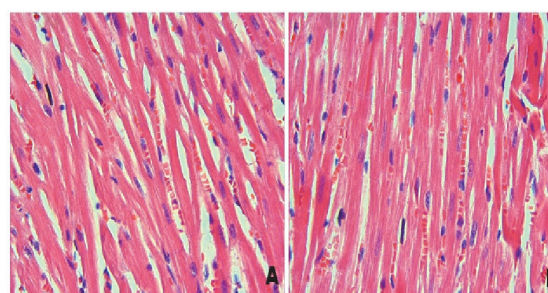
The sections from control and olive oil groups were normal in histological appearance (Figs. 1A, B). The mean histopathological damage scoring (MHDS) was  $1.28 \pm 0.42$  and  $2.71 \pm 0.52$  in control and olive oil groups, respectively. However; vacuolization and necrosis of cardiocytes with infiltration, vascular congestion, hemorrhage and fibrosis of heart tissue were observed in the rats exposed to  $CCl_4$  alone (Fig. 2). MHDS was  $8.14 \pm 0.67$  in the  $CCl_4$  group. Significant increase in histopathological scoring was detected in  $CCl_4$  administered group compared with the control and olive oil groups ( $p < 0.005$ , for both). Histopathological changes were markedly reduced in rats treated with melatonin and quercetin (Figs. 3A, B). MHDSs were  $3.85 \pm 0.34$  in  $CCl_4$ +Melatonin and  $4.85 \pm 0.55$  in  $CCl_4$ +Quercetin groups. MHDSs of  $CCl_4$  and those of  $CCl_4$ +Melatonin and  $CCl_4$ +Quercetin groups were significantly different ( $p < 0.005$ ,  $p < 0.01$ , respectively). There was no significant difference between treatment groups ( $p > 0.05$ ). MHDSs of all of the groups were summarized in Table 1.



**Figure 1.** Photomicrographs of normal heart tissues. **A.** Control group. H-E; X 40. **B.** Olive oil group. H-E; X 40.



**Figure 2.** Photomicrographs of heart tissues in  $CCl_4$  group. **A.** Hemorrhage (arrow), H-E; X 10. **B.** Hemorrhage (asterisks) and necrotic cells with eosinophilic cytoplasm, H-E; X 20. **C.** Inflammatory cells (arrows), H-E; X 20. **D.** Necrotic cells with eosinophilic cytoplasm (arrows) and fibrosis (asterisks), H-E; X 40. **E.** Necrotic cells with eosinophilic cytoplasm, H-E; X 40. **F.** Vacuolization (arrows), H-E; X 100.



**Figure 3.** Photomicrographs heart tissues of treatment groups. Histopathological findings were reduced in these groups. **A.**  $CCl_4$ +Melatonin group. H-E; X 40. **B.**  $CCl_4$ +Quercetin group. H-E; X 40.

**Table 1.** The mean histopathological damage score (MHDS) of all groups.

	Control	Olive Oil	$CCl_4$	$CCl_4$ +Melatonin	$CCl_4$ +Quercetin
MHDS	$1.28 \pm 0.42$	$2.71 \pm 0.52$	$8.14 \pm 0.67^a$	$3.85 \pm 0.34^{b,c}$	$4.85 \pm 0.55^{b,d,e}$

Data are expressed mean±SE of seven animals.

<sup>a</sup>  $p < 0.005$  vs control group and olive oil group, <sup>b</sup>  $p < 0.005$  vs control group

<sup>c</sup>  $p < 0.005$  vs  $CCl_4$  group,

<sup>d</sup>  $p < 0.05$  vs olive oil group

<sup>e</sup>  $p < 0.01$  vs  $CCl_4$  group.



### Biochemical findings

Mean tissue MDA level of CCl<sub>4</sub> group was significantly increased in comparison with control group and olive oil group (p<0.005, for both). However, mean tissue MDA levels of CCl<sub>4</sub>+Melatonin group and CCl<sub>4</sub>+Quercetin group were significantly lower than that of CCl<sub>4</sub> group (p<0.005, p<0.01, respectively). On the other hand, mean tissue GSH level and SOD activity were significantly decreased when compared with the control

and olive oil groups (p<0.005, p<0.05, respectively). Melatonin administration resulted in a significant increase in mean cardiac GSH level (p<0.01) and SOD (p<0.005) activity. Quercetin administration also caused significant increases in GSH levels (p<0.05) and SOD activities (p<0.005). No significant difference between treatment groups was detected (p>0.05). Biochemical results of all of the groups were summarized in Table 2.

**Table 2.** The mean levels of tissue oxidant-antioxidant parameters.

	MDA (nmol/mg)	SOD (U/mg)	GSH (nmol/mg)
Control	97.51±8.79	12.45±0.56	2.20±0.15
Olive Oil	96.92±7.04	11.25±0.59	2.14±9.99
CCl <sub>4</sub>	269.29±22.44 <sup>a</sup>	5.66±0.47 <sup>e</sup>	1.81±7.71 <sup>a</sup>
CCl <sub>4</sub> +Melatonin	116.12±12.14 <sup>b</sup>	9.13±0.92 <sup>b</sup>	2.96±0.29 <sup>c</sup>
CCl <sub>4</sub> +Quercetin	161.03±18.70 <sup>c,d</sup>	8.11±0.63 <sup>b</sup>	3.12±0.2 <sup>f</sup>

Data are expressed mean±SE of seven animals.

<sup>a</sup>p <0.005 vs control group and olive oil group,

<sup>b</sup>p <0.005 vs CCl<sub>4</sub> group

<sup>c</sup>p <0.01 vs CCl<sub>4</sub> group,

<sup>d</sup>p <0.05 vs CCl<sub>4</sub>+Melatonin group

<sup>e</sup>p <0.05 vs control group and olive oil group,

<sup>f</sup>p <0.05 vs CCl<sub>4</sub> group

## DISCUSSION

Various environmental toxicants and clinically useful drugs can cause severe tissue toxicity by superoxides and ROS. One of the frequently studied of the environmental toxicants is CCl<sub>4</sub> (15). Although liver is considered to be the primary target of CCl<sub>4</sub> toxicity, it also causes free radical generation in other tissues such as heart, kidneys, lung, brain and testis (6, 16, 17). CCl<sub>4</sub>-induced formation of free radicals and related reactive species leads to loss of myocardial structural integrity and depression of cardiac functions resulting in cardiotoxicity and cardiac failure (18). In the present study, using light microscopy, CCl<sub>4</sub> administration resulted in various histopathological alterations including vacuolization, necrosis, infiltration and fibrosis. In addition, marked vascular congestion with focal hemorrhage was seen in the myocardium of CCl<sub>4</sub>-induced group. To our knowledge, the effects of antioxidants on CCl<sub>4</sub>-induced cardiotoxicity was rarely studied. However, our findings coincided with the previous studies. Eshaghi et al. (18) observed necrosis and infiltration and also Al-Rasheed et al. (19) detected fibrosis and massive degeneration in CCl<sub>4</sub>-induced cardiotoxicity. The vacuolization might be explained by expansion of cytoplasmic membranous components caused by intracellular water and electrolytes redistribution.

The majority of previous studies showed that antioxidants can protect body against CCl<sub>4</sub> induced oxidative stress (20, 21). Aranda et al. (22) and Kus et al. (23) suggested that melatonin has a powerful antioxidant and free radical scavenging capacity in preventing CCl<sub>4</sub>-induced toxicity. On the other hand, strong antioxidant property of quercetin helps to neutralise the free radicals produced by CCl<sub>4</sub>, and hence protects the organs against oxidative stress (24, 25). In the present study, melatonin and quercetin significantly

reduced oxidative damage and prevented histopathological changes associated with CCl<sub>4</sub> administration. There was significant reduction in the vascular congestion among cardiomyocytes. There was also marked decrease in the necrosis of cardiomyocytes represented by less number of pyknotic and karyolytic nuclei compared with the CCl<sub>4</sub>-induced group. To our knowledge, effects of melatonin and quercetin on CCl<sub>4</sub>-induced cardiotoxicity were not studied so far. Al-Rasheed et al. (19) also observed melatonin reduced fibrosis and massive degeneration in CCl<sub>4</sub>-induced cardiac damage. Similar beneficial capacity of other antioxidants against CCl<sub>4</sub> cardiotoxicity have been reported. Karadeniz et al. (17) detected that panax ginseng has beneficial effects on CCl<sub>4</sub>-induced cardiotoxicity. Eshaghi et al. (18) also reported that Cornus Mas Fruit extract has beneficial effect in preventing CCl<sub>4</sub>-induced infiltration and degeneration of myofibrillar tissue. According to other cardiotoxicity studies melatonin is effective in inhibiting histopathological changes in doxorubicin and cyclosporin-induced cardiac damage (26- 29).

MDA, a major reactive aldehyde that appears during the peroxidation of biological membrane polyunsaturated fatty acids is an important marker of membrane damage (30). The oxidative damage induced by CCl<sub>4</sub> is characterized by a significant increase in tissue MDA levels (31). In our study the mean cardiac MDA levels of CCl<sub>4</sub> group were higher than those of the other groups. These findings are similar to other CCl<sub>4</sub>-induced cardiotoxicity studies (17, 18, 27). Treatment with melatonin and quercetin significantly lowered MDA levels. These results suggests that melatonin and quercetin protect membranes against CCl<sub>4</sub>-induced oxidative stress.

To prevent the damage caused by free radicals, tissues have developed an antioxidant defense system that

includes enzymatic activities including superoxide dismutase and glutathione peroxidase (32, 33). In present study we observed that mean cardiac GSH level and SOD activity of CCl<sub>4</sub> group were significantly reduced. Karadeniz et al. (17) and Eshaghi et al. (18) also found antioxidative enzyme activities reduced in CCl<sub>4</sub>-induced cardiotoxicity. Melatonin and quercetin significantly increased GSH levels and SOD activities. Previous experimental studies have shown that Panax Ginseng and Cornus Mas Fruit extract also increase GSH levels and SOD activities (17, 18). Oz et al. (27) found melatonin effective in increasing cardiac GSH level in doxorubicin-induced cardiotoxicity.

## CONCLUSION

As a conclusion, our study supports the antioxidant and free radical scavenging effects of melatonin and quercetin in reducing cardiotoxic effects of CCl<sub>4</sub>. We detected beneficial effects of melatonin and quercetin in protecting membranes and we observed them to be effective in supporting cellular antioxidant defence system. To our knowledge, this is the first microscopic study evaluating the effects of melatonin and quercetin on CCl<sub>4</sub>-induced cardiotoxicity.

## REFERENCES

1. Behl C. Alzheimer's disease and oxidative stress implications for novel therapeutic approaches. *Prog Neurobiol* 1999;57:301-23.
2. Das J, Roy A, Sil PC. Mechanism of the protective action of taurine in toxin and drug induced organ pathophysiology and diabetic complications: a review. *Food Funct* 2012;3:1251-64.
3. Major GN, Collier JD. Repair of DNA lesion O<sup>6</sup>-methylguanine in hepatocellular carcinogenesis. *J Hepatobiliary Pancreat Surg* 1998;5:355-66.
4. Jayakumar T, Sakthivel M, Thomas PA, Geraldine P. *Pleurotus ostreatus*, an oyster mushroom, decreases the oxidative stress induced by carbon tetrachloride in rat kidneys, heart and brain. *Chem Biol Interact* 2008;176:108-20.
5. Atawia RT, Esmat A, Elsherbiny DA, El-Demerdash E. Telmisartan ameliorates carbon tetrachloride-induced acute hepatotoxicity in rats. *Environ Toxicol* 2016 Mar 1.
6. Simile MM, Banni S, Angioni E, Carta G, De Miglio MR, Muroli MR. 5-Methyl thioadenosine administration prevents lipid peroxidation and fibrogenesis induced in rat liver by carbon tetrachloride intoxication. *J Hepatol* 2001;34:386-94.
7. Gilgun-Sherki Y, Rosenbaum Z, Melamed E, Offen D. Antioxidant Therapy in acute nervous system injury: current state. *Pharmacol Rev* 2002;4:271-84.
8. Nishida S. Metabolic effects of melatonin on oxidative stress and diabetes mellitus. *Endocrine* 2005;27(2):131-5.
9. Srinivasan V, Pandi-Perumal SR, Maestroni GJM, Esquifino AI, Hardeland R, Cardinali DP. Role of melatonin in neurodegenerative diseases. *Neurotox Res* 2005;7(4):293-318.
10. Dias AS, Porawski M, Alonso M, Marroni N, Collado PS, González-Gallego J. Quercetin decreases oxidative stress, NF-κB activation, and iNOS overexpression in liver of streptozotocin-induced diabetic rats. *J Nut* 2005;135:2299-304.
11. McCord JM, Fridovich I. Superoxide dismutase. An enzymatic function for erythrocyte hemocuprein. *J Biol Chem* 1969;244:6049-55.
12. Theodorou P, Akerboom M, Sies H. Assay of glutathione, glutathione disulfide and glutathione mixed disulfides in biological samples. *Methods Enzymol* 1981;77:373-83.
13. Buege AJ, Aust SD. Microsomal lipid peroxidation. *Methods Enzymol* 1978;52:302-10.
14. Bradford MM. A rapid and sensitive method for the quantitation of microgram quantities of protein utilizing the principle of protein-dye binding. *Anal Biochem* 1976;72:248-54.
15. Olagunju JA, Adeneye AA, Fagbohunka BS, Bisugac NA, Ketikuc AO, Benebod AS. Nephroprotective activities of the aqueous seed extract of *Carica papaya* Linn. in carbon tetrachloride induced renal injured Wistar rats: a dose and time dependent study. *Biology and Medicine* 2009;1(1):11-9.
16. Ozturk F, Ucar M, Ozturk IC, Vardi N, Batcioglu K. Carbon tetrachloride-induced nephrotoxicity and protective effect of betaine in Sprague-Dawley rats. *Urology* 2003;62:353-6.
17. Karadeniz A, Yıldırım A, Karakoc A, Kalkan Y, Celebi F. Protective effect of panax ginseng on carbon tetrachloride induced liver, heart and kidney injury in rats. *Revue Méd Vét* 2009;160(5):237-43.
18. Eshaghi M, Zare S, Banihabib N, Nejati V, Farokhi F, Mikailiet P. Cardioprotective effect of cornus mas fruit extract against carbon tetrachloride induced-cardiotoxicity in albino rats. *J Basic Appl Sci Res* 2012;2(11):11106-14.
19. Al-Rasheed NM, Faddah LM, Mohamed AM, Mohammad RA, Al-Amin M. Potential impact of silymarin in combination with chlorogenic acid and/or melatonin in combating cardiomyopathy induced by carbon tetrachloride. *Saudi J Biol Sci* 2014;21:265-74.
20. Ozturk F, Gul M, Ates B, Ozturk IC, Cetin A, Vardi N. Protective effect of apricot (*Prunus armeniaca* L.) on hepatic steatosis and damage induced by carbon tetrachloride in wistar rats. *Br J Nutr* 2009;102(12):1767-75.
21. Ozturk IC, Ozturk F, Gul M, Ates B, Cetin A. Protective effects of ascorbic acid on hepatotoxicity and oxidative stress caused by carbon tetrachloride in the liver of wistar rats. *Cell Biochem Funct* 2009;27(5):309-15.
22. Aranda M, Albendea CD, Lostalé F, López-Pingarrón L, Fuentes-Broto L, Martínez-Ballarín E. In vivo hepatic oxidative stress because of carbon tetrachloride toxicity: Protection by melatonin and pinoline. *J Pineal Res* 2010;49:78-85.
23. Kus I, Ogeturk M, Oner H, Sahin S, Yekeler H, Sarsilmaz M. Protective effects of melatonin against carbon tetrachloride-induced hepatotoxicity in rats: A light microscopic and biochemical study. *Cell Biochem Funct* 2005;23:169-74.
24. Zhao X, Zhang X. Comparisons of cytoprotective effects of three flavonoids against human hepatocytes oxidative injury induced by hydrogen peroxide or carbon tetrachloride in vitro. *Journal of Medicinal Plants Research* 2009;3(10):776-84.
25. Vieira EK, Bona S, Cangeri Di Naso F, Porawski M, Tieppo J, Marroni NP. Quercetin treatment ameliorates systemic oxidative stress in cirrhotic rats. *ISRN Gastroenterology* 2011;2011:604071.
26. Demir F, Narin F, Akgun H. Doksorubisin ile oluşturulmuş deneysel kardiyotoksikite üzerine

- melatoninin etkisi. *Cocuk Sagligi ve Hastaliklari Dergisi* 2004;47:260-8.
27. Oz E, Erbas D, Surucu HS, Duzgun E. Prevention of doxorubicin-induced cardiotoxicity by melatonin. *Mol Cell Biochem* 2006;282:31-7.
  28. Rezzani R, Rodella LF, Bonomini F, Tengattini S, Bianchi R, Reiter RJ. Beneficial effects of melatonin in protecting against cyclosporine A-induced cardiotoxicity are receptor mediated. *J Pineal Res* 2006;41:288-95.
  29. Balli E, Mete UO, Tuli A, Tap O, Kaya M. Effect of melatonin on the cardiotoxicity of doxorubicin. *Histol Histopathol* 2004;19:1101-8.
  30. Vaca CE, Wilhelm JM, Harms-Rihdsahl M. Interaction of lipid peroxidation product with DNA. *Gen Toxicol* 1988;195:137-49.
  31. Ganie SA, Haq E, Hamid A, Qurishi Y, Mahmood Z, Zargar BA. Carbon tetrachloride induced kidney and lung tissue damages and antioxidant activities of the aqueous rhizome extract of podophyllum hexandrum. *BMC Complement Altern Med* 2011;28:11:17.
  32. Mates JM, Perez-Gomez C, Castro I. Antioxidant enzymes and human diseases. *Clinical Biochemistry* 1999;32:595-603.
  33. Rahman K. Studies on free radicals, antioxidants and co-factors. *Clinical Interventions* 2007;2(2):219-36.