



Bilateral Knee Osteonecrosis After Intraarticular Concomitant Local Anesthetic and Corticosteroid Injection: A Case Report

Gökay Görmeli¹, Cemile Ayşe Görmeli², Muharrem Ucar³, Reşit Sevimli¹, Şükrü Gürbüz⁴

¹Inönü University School of Medicine, Department of Orthopaedics and Traumatology, Malatya, Turkey

²Inönü University School of Medicine, Department of Radiology, Malatya, Turkey

³Inönü University School of Medicine, Department of Anaesthesiology and Reanimation, Malatya, Turkey

⁴Inönü University School of Medicine, Department of Emergency Medicine, Malatya, Turkey

Abstract

Osteoarthritis is the most common form of joint diseases that represents the most notable basis of disability. Osteoarthritis is characterized by degeneration of the articular cartilage, osteophyte formation, and subchondral changes. Conservative treatment can be preferred if articular cartilage damage is not extensive. One of the non-operative preferred modality by the clinicians is the intraarticular injection therapy with local anesthetics, corticosteroids, or combination of both. The current literature and our experience indicate that intraarticular injections have positive effects for patient satisfaction. Intraarticular corticosteroid injections provide short term reduction in osteoarthritis pain. Although these drugs reduce pain and disability, they also have side effects such as chondrocyte damage that causes early osteoarthritis or avascular necrosis. We aim to present a case who developed bilateral knee avascular necrosis in a short time due to intraarticular injection of both corticosteroid and local anesthetics.

Key Words: Intraarticular Injections; Corticosteroid; Knee Osteoarthritis.

Lokal Anestezik ve Kortikosteroidin Ekleme Birlikte Enjeksiyonu Sonrası Gelişen Bilateral Diz Osteonekrozu: Olgu Sunumu

Özet

Osteoartrit maluliyetin en önemli etkenlerinden biri olarak karşılaşılabileceğimiz, en sık eklem hastalıkları formudur. Osteoartrit, eklem kırıkdağının dejenerasyonu, osteofit formasyonu ve subkondral kistler ile karakterizedir. Eklem kırıkdağının geniş olmadığı durumlarda konservatif tedavi tercih edilebilir. Klinisyenler tarafından tercih edilen konservatif tedavi yöntemlerinden biri de lokal anestezik, kortikosteroid veya bunların her ikisinin birlikte kullanıldığı eklem içi enjeksiyonlardır. Mevcut literatür ve bizim deneyimlerimiz, eklem içi enjeksiyonların hasta memnuniyeti için olumlu etkilere sahip olduğunu göstermektedir. Eklem içi steroid uygulanımı osteoartritli hastalarda kısa dönemli ağrıyı giderir. Bu ilaçların ağrı ve maluliyeti azaltıcı etkisi olmasına rağmen kondrosit hasarına bağlı erken osteoartrit veya avasküler nekroz gibi yan etkileri de olmaktadır. Biz kortikosteroid ve lokal anestezik maddenin eklem içi enjeksiyonu sonrasında kısa dönem içerisinde her iki dizde avasküler nekroz gözlenen bir olguyu sunmayı amaçladık.

Anahtar Kelimeler: Eklem İçi Enjeksiyon; Kortikosteroid; Diz Osteoartriti.

INTRODUCTION

Osteoarthritis (OA) is the most common form of joint diseases which is characterized by the degeneration of the articular cartilage, osteophyte formation, subchondral erosion due to chondrocyte damage, and subchondral bone remodeling (1). Obesity, bone mass, trauma, joint instability and deformity, and trauma are common factors in OA, especially for the hip and knee joints (2).

Conservative treatment for the knee OA can be separated as non-pharmacological and pharmacological modalities. The non-pharmacological modalities are patient education and self-management, weight loss, exercises, walking supports (crutches), bracing, and shoe modification. Pharmacologic therapies can be summarized as paracetamol, non-steroidal anti-inflammatory drugs, and slow-acting drugs such as glucosamine and chondroitin sulfate. If orally

administered drugs are ineffective, intraarticular (IA) injection (corticosteroids, viscosupplements, blood-derived products) is the last nonoperative modality that can be preferred (3-4).

It is now generally accepted that osteoarthritis of the knee begins with the destruction of chondrocytes. Destruction of the chondrocytes is the final result of abnormal biomechanical, biochemical, and genetic factors. IA CS and local anesthetic therapies can cause the destruction of these cells and damaged chondrocytes may lead to osteonecrosis or early knee OA (5). We here report a case with osteonecrosis who had both IA CS and local anesthetic injection that caused bilateral necrosis for both knees.

CASE REPORT

A 54-year-old woman complained of bilateral knee pain without a history of trauma or any systemic disorder that might have caused joint pain. She had a history of both

IA CS and local anesthetic injection one month before being referred to our clinic. Physical examination revealed tenderness in the medial knee joint. There was a full of range of motion for both knees with no instability. Mc murray, varus stres, valgus stres, anterior drawer, posterior drawer, and lachmann tests were negative in physical examination. There was no hematome and patellar ballotman test was also negative. In addition, plain radiographs revealed no degenerative changes, suggesting Kellgren-Lawrence grade 1. The femorotibial angle was 173° for right knee and 168° on standing radiographs. Laboratory findings were within normal limits. Magnetic resonance imaging (MRI) revealed a diffuse area of bone oedema that was hypointense on T1-weighted and hyperintense on T2-weighted images. We diagnosed the patient with osteonecrosis in the light of the MRI results (Figure 1, 2).

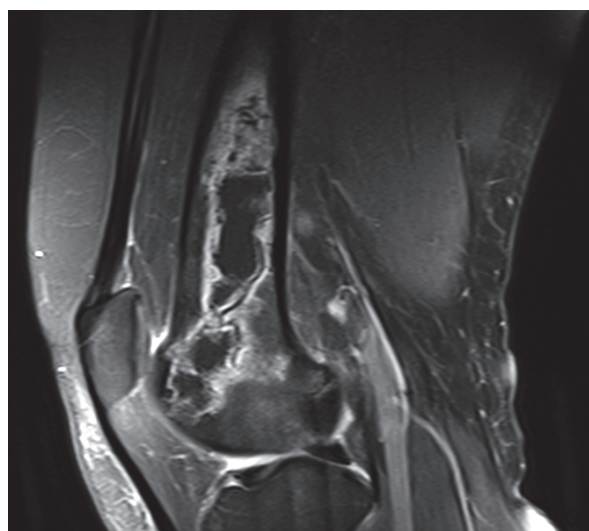


Figure 1. Knee osteonecrosis on coronal T2-weighted images after intraarticular corticosteroid and local anesthetic injection.

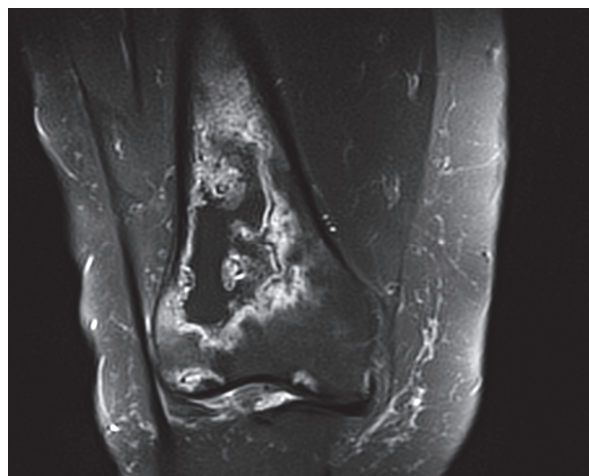


Figure 2. Knee osteonecrosis on sagittal T2-weighted images after intraarticular corticosteroid and local anesthetic injection.

DISCUSSION

Local anesthetics have been used intra-articularly for many years for perioperative pain control and ambulatory settings. Local anesthetics can be injected alone or with other pharmaceuticals for pain control and to minimize narcotic use as part of a multimodal pain control algorithm. Use of intra-articular local anesthetics has been shown to improve postoperative pain scores and reduce narcotic consumption and narcotic-related side effects, such as respiratory depression, sedation, and constipation (6). In the clinic, local anesthetics are routinely injected into knees, shoulders, and other joints for both diagnostic and therapeutic purposes, often combined with other agents such as corticosteroids.

In recent years, some in vivo and invitro studies concluded that local anesthetics such as lidocaine, bupivacaine, and ropivocaine have chondrotoxic effects for human and animal chondrocytes (7, 8). This affect would be due to its supression of ATP dependent potassium channels (9). Chondrocyte dysfunction and death is a key characteristic of early osteoarthritis. IA injection of these anesthetics results in decrease of the chondrocyte metabolism, increase of chondrocyte apoptosis, and necrosis and cartilage degradation. Karpie et al. concluded that cytotoxic effects of lidocaine are dose- and time-dependent on bovine articular chondrocytes so low-dose lidocaine may be tolerated by chondrocytes (10). However, in our case, osteonecrosis occurred with only one dose of IA lidocaine injection. So, we think the chondrocyte damage due to local anesthetics is not dose dependent especially when administered with steroids.

Corticosteroids have been shown to clinically reduce symptoms of pain for osteoarthritis and inflammatory arthritis by suppression of synovial inflammation. But there are some studies that have shown negative effects of steroids on articular cartilage. After the intra-articular injection of hydrocortisone in rabbit knees, Mankin et al. detected decrease in protein synthesis (11). An increased release of degradation products of aggrecan after methylprednisolone injections were demonstrated by Robion et al. (12). Also chondrocyte apoptosis in steroid- treated human articular cartilage were shown by Nakazawa et al. (13). Therefore, we do not prefer IA steroid injections except for advanced OA in our clinic. Although this therapy reduces pain for a short time period, it causes chondrocyte apopitosis, necrosis, and even early OA. Injections of corticosteroid and local anesthetics combinations cause increased damage to chondrocytes. In an in-vitro and ex vivo study, Farkas et al. have concluded that the combination of corticosteroid and local anesthetics has an increased adverse effect on articular chondrocytes (13, 14). In an in-vitro study, Seshadri et al. have shown a dose- and time-dependent decrease in chondrocyte viability after exposure to clinically relevant doses of methylprednisolone. They have also put forward that combination of methylprednisolone and lidocaine was toxic with virtually no cells surviving after treatment. In

our case, concomitant IA injection of corticosteroid and local anesthetics caused immediate cell death soon after followed by the avascular necrosis (15, 16).

As a result, due to chondrocyte damage, we don't prefer using intraarticular local anesthetics or corticosteroids for joint diseases. Especially using both local anesthetics and corticosteroids causes increased chondrocyte damage and avascular necrosis as it was the case in our patient.

REFERENCES

1. Martel-Pelletier J, Boileau C, Pelletier JP, Roughley PJ. Cartilage in normal and osteoarthritis conditions. *Best Pract Res Clin Rheumatol* 2008;22:351-84.
2. D. T. Felson. "Epidemiology of hip and knee osteoarthritis" *Epidemiologic Reviews* 1988;10:1-28.
3. Zhang W, Nuki G, Moskowitz RW, Abramson S, Altman RD, Arden NK et al. OARSI recommendations for the management of hip and knee osteoarthritis: part III: Changes in evidence following systematic cumulative update of research published through January 2009. *Osteoarthritis Cartilage* 2010;18:476-99.
4. Kon E, Filardo G, Drobnic M, Madry H, Jelic M, van Dijk N, Della Villa S. Non-surgical management of early knee osteoarthritis. *Knee Surg Sports Traumatol Arthrosc* 2012;20:436-49.
5. Seshadri V, Coyle CH, Chu CR. Lidocaine potentiates the chondrotoxicity of methylprednisolone. *Arthroscopy* 2009;25:337-47.
6. Busch CA, Shore BJ, Bhandari R, et al. Efficacy of periarticular multimodal drug injection in total knee arthroplasty: a randomized trial. *J Bone Joint Surg Am* 2006;88:959-63.
7. Chu CR, Izzo NJ, Coyle CH, Papas NE, Logar A. The in vitro effects of bupivacaine on articular chondrocytes. *J Bone Joint Surg Br* 2008;90:814-20.
8. Dragoo JL, Korotkova T, Kanwar R, Wood B. The effect of local anesthetics administered via pain pump on chondrocyte viability. *Am J Sports Med* 2008;36:1484-88.
9. Olschewski A, Olschewski W, Brau ME, Hempelmann G, Vogel V, Safranov BV. Effect of bupivacaine on ATP dependent potassium channels in rat cardiomyocytes. *British Journal of Anesthesia* 1999;82:435-8.
10. Karpie JC, Chu CR. Lidocaine exhibits dose- and time-dependent cytotoxic effects on bovine articular chondrocytes in vitro. *Am J Sports Med* 2007;35:1621-7.
11. Mankin HJ, Conger KA. The acute effects of intra-articular hydrocortisone on articular cartilage in rabbits. *J Bone Joint Surg Am* 1966;48:1383-88.
12. Robion FC, Doizé B, Bouré L. Use of synovial fluid markers of cartilage synthesis and turnover to study effects of repeated intra-articular administration of methylprednisolone acetate on articular cartilage in vivo. *J Orthop Res* 2001;19:250-58.
13. Nakazawa F, Matsuno H, Yudoh K, Watanabe Y, Katayama R, Kimura T. Corticosteroid treatment induces chondrocyte apoptosis in an experimental arthritis model and in chondrocyte cultures. *Clin Exp Rheumatol* 2002;20:773-81.
14. Farkas B, Kvell K, Czömpöly T, Illés T, Bárdos T. Increased chondrocyte death after steroid and local anesthetic combination. *Clin Orthop Relat Res* 2010;468:3112-20.
15. Maricar N, Callaghan MJ, Felson DT, O'Neill TW. Predictors of response to intra-articular steroid injections in knee osteoarthritis--a systematic review. *Rheumatology (Oxford)* 2013;52:1022-32.
16. McArthur BA, Dy CJ, Fabricant PD, Valle AG. Long term safety, efficacy, and patient acceptability of hyaluronic acid injection in patients with painful osteoarthritis of the knee. *Patient Prefer Adherence* 2012;6:905-10.

Received/Başvuru: 15.12.2014, Accepted/Kabul: 08.01.2015

Correspondence/İletişim

Gökay GÖRMELİ
İnönü Üniversitesi Tıp Fakültesi, Ortopedi ve Travmatoloji
Anabilim Dalı, MALATYA, TÜRKİYE
E-mail: ggormeli@yahoo.com

For citing/Atıf için

Gormeli G, Gormeli CA, Ucar M, Sevimli R, Karakaplan M, Gurbuz S. Bilateral knee osteonecrosis after intraarticular concomitant local anesthetic and corticosteroid injection: a case report. *J Turgut Ozal Med Cent* 2015;22:201-3 DOI: 10.7247/itomc.2014.2510