



Doxycycline Induced Esophageal Ulcer: The Report of Two Cases

Yasir Furkan Cagin¹, Yahya Atayan¹, Mehmet Ali Erdogan¹, Cumali Cetin², Gursel Ak³,
Firat Dagtekin⁴, Murat Aladag¹

Department of ⁴Internal Medicine and Division of ¹Gastroenterology, Inonu University Faculty of Medicine, Malatya, Turkey

²Department of Infectious Diseases and Clinical Microbiology, State Hospital, Malatya, Turkey

³Clinic of Internal Medicine, Sevgi Private Hospital, Malatya, Turkey

Abstract

It has been established that drugs can induce esophageal mucosal injury. Doxycycline induced esophageal injury has contributed to most of drug induced esophageal injuries. In this study, two cases were presented. Two females who were 27 and 30 years old, applied to our hospital with complains of an acute onset odynophagia, dysphagia and retrosternal pain after using doxycycline for their genital system infection. Endoscopic examination detected semicircular deep ulceration at the middle esophagus. Their symptoms improved after 3 days of initiation of pantoprazole and liquid sucralfate following discontinuation of doxycycline. Drug induced esophageal injury is a common condition. Use of drug should be investigated in patients with similar symptoms.

Key Words: Doxycycline, esophagus injury, dysphagia

(Rec.Date: June 28, 2014 Accept Date: September 11, 2014)

Corresponding Author: Yasir Furkan Cagin, Division of Gastroenterology, Inonu University, Faculty of Medicine, Malatya, Turkey

E-mail: yafur@hotmail.com

Introduction

Drugs can induce esophageal injury through systemic and local actions. Drugs can induce esophageal injury through both systemic and local actions. It usually is observed in young people without any esophageal disease [1]. The kinds of drug causing direct esophageal injury can be coarsely separated into antibiotics, anti-inflammatory agents, and others. Tetracyclines are the most common antibiotics to induce esophagitis, especially doxycycline [2-5]. In this report, a patients who developed esophageal ulcers after taking doxycycline for pelvic inflammatory disease (PID) was presented.

Cases

Informed consents were taken from all patients.

Case 1: 100 mg doxycycline twice a day was prescribed to a 30 years old female patient who admitted to obstetrics and gynecology outpatient clinic with the diagnosis of genital infection. The complaints of sudden onset odynophagia, dysphagia and pain in the center of the chest were started after the use of doxycycline in the third day of doxycycline use. The patient was admitted to Internal Medicine Outpatient Clinic of our hospital with these complaints. She expressed in her history that she received drug just before bedtime. Physical examination and the patient's biochemistry, ECG and chest X-ray were normal. There was no history of esophageal disease, smoking or alcohol. There was no history of drug use such as aspirin or iron preparations. 10 cm, long fragile deep ulcerated lesion with irregular borders starting at the middle 1/3 esophagus and extending parallel to the long axis of the esophagus was detected in the esophago-gastro-duodenoscopic examination (Figure 1). Lesion was thought to be caused by doxycycline. Doxycycline was stopped immediately, pantoprazole and sucralfate suspension treatment was started. The patient's complaints began to decline from the third day. Lesions were healed without any sequel in the control endoscopic examination 3 weeks later.

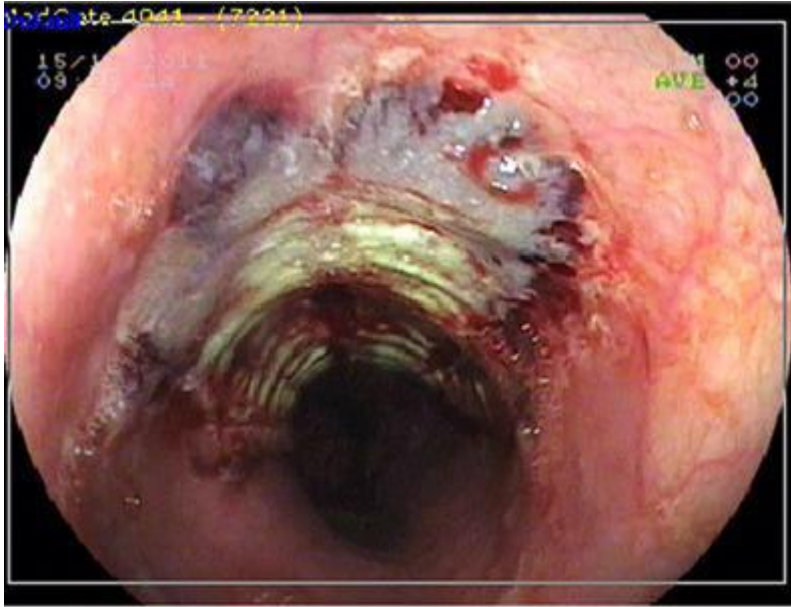


Figure 1. Fragile deep ulcerated lesion with irregular borders at the middle 1/3 esophagus.

Case 2: 100 mg doxycycline twice a day was prescribed to a 27 years old female patient who admitted to obstetrics and gynecology outpatient clinic with the diagnosis of genital infection. The patient was admitted to our clinic with the complaints of odynophagia, dysphagia and pain in the center of the chest which started two days after doxycycline use. The patient stated that she took pill with little water. There was no other etiological factor in the patient who doesn't smoke or take alcohol. There was no feature in her physical and laboratory exam. 3 cm long semicircular ulcerated lesion with irregular borders covering 2/3 of the lumen in mid-esophagus was detected in the esophago-gastro-duodenoscopic examination (Figure 2). Lesion was thought to be caused by doxycycline. Doxycycline was stopped immediately, pantoprazole and sucralfate suspension treatment was started. The patient's complaints declined dramatically in two days. Lesions were healed without any sequel in the control endoscopic examination 15 days later.

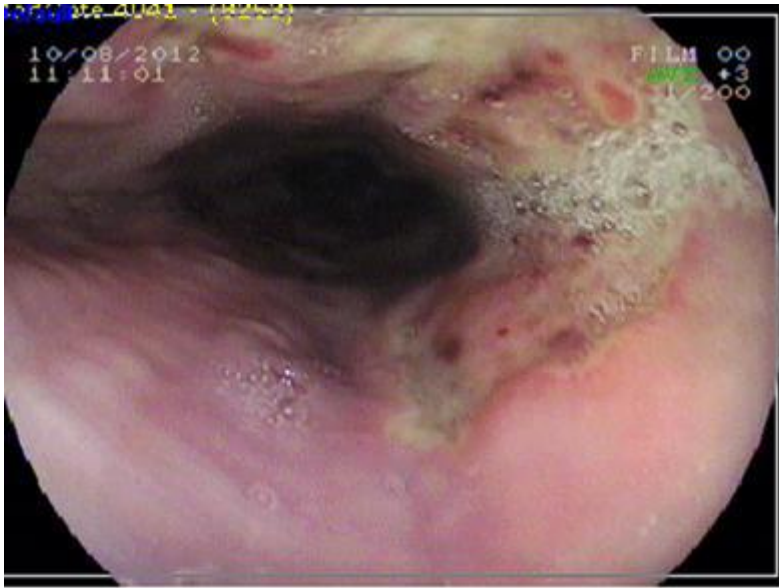


Figure 2. Semicircular ulcerated lesion with irregular borders covered by exudate at the middle 1/3 esophagus.

Discussion

Drug-induced esophageal ulcer is a common condition usually seen in young people without any esophageal disease [1]. Although more than 100 drugs are known to cause this disease, the exact prevalence of these drugs is not available. Doxycycline, tetracycline, oxytetracycline, minocycline, clindamycin and penicillin constitute more than half of the cases [2-5]. Lesions especially occur where esophageal strictures are localized areas [6]. Factors related to medication, patients and esophagus are reported to be effective in mucosal damage [6-9]. Factors related to drugs are chemical structure, solubility, contact time and gelatin coat. Chemical content of doxycycline is acidic, and it gives damage to the mucosa by lowering the pH of saliva and water. It increases contact time by reducing the salivation. It is also reported that it causes mucosal damage by inhibiting protein synthesis [7]. In both cases, the drug was taken with a little water before going to bed and this knowledge is consistent with the literature. Factors related to patient are considered as taking the drug with little water and before bedtime [7,9,10]. It is recommended taking drug with at least 100 ml of water and in standing or sitting position [10,11]. Factors related to esophagus are thought to be esophageal motility disorders and anatomical or pathological strictures (atrial enlargement)

[6-8]. Symptoms can develop between a few hours and 10 days in doxycycline induced esophageal ulcers [11]. Symptoms are odynophagia (94%), heartburn (80%) and dysphagia (54%) relatively [11]. In both cases, the most common symptom is odynophagia. Typical patient history is usually not enough for diagnosis, and the gold standard is endoscopy. Biopsy findings are nonspecific. Ulcers observed in endoscopic examination vary in size, depth and number. Ulcer localization is mostly (66%) the middle part of the esophagus [7,11]. Mid-esophageal localization and variability in the size, depth and number of the ulcers are compatible with literature in the endoscopic examination of both cases. First step of the treatment is discontinuation of the drug. Nevertheless, with adequate training regarding taking enough water (at least 100 mL) and the timing of the drug, the drug may be continued [11]. In addition, the proton pump inhibitors are given together with the prokinetic drugs. However, benefits of antacids, antisecretory drugs and PPIs in patients without gastroesophageal reflux are controversial [11]. There has been no data showing the benefits of acid suppression except for sucralfate [11]. We preferred to stop the drug and giving sucralfate suspension with the PPI in our patients. Although symptoms relieved within one week in the majority of patients complete resolution of symptoms lasts 10-14 days [12-15]. In both cases, the symptoms decreased with in the first 3 days of the treatment.

As a result, it is possible to make general comments on doxycycline. Drugs, especially drugs with ulcerogenic potential, should be taken with plenty of water and the patient should not sleep immediately after drug use. These should be recommended to all patients. Complications may be prevented by warning the patient. All tablets and capsules should be taken with 100-120 ml of water. Pharmaceutical companies can develop safe drug formulations instead of the capsule and these complications can be reduced by making prospectus with several warnings written.

Conflict of interest: The authors declare no conflict of interest.

References

1. Fernandopulle ANR, Navarathne NMM. Oesophageal injury suspected to be due to doxycycline ingestion. Ceylon Med J. 2011;56(4):162-3.
2. Yılmaz Ö, Bilgiç Y, Bilen Y, Okçu N. Doxycycline induced esophageal injury. Türkiye Klinikleri J Med Sci. 2008;28(4):569-71.
3. Fauci AS, Braunwald E, Isselbacher KJ, Wilson JD. Diseases of the Esophagus. In: Longo D, Fauci A, Kasper D, Hauser S, Jameson J, Loscalzo J, eds, Harrison's principles of internal medicine. 14th edition. McGraw-Hill, Boston, Vol 2, 1998:1595.

4. Goldman L, Bannet JC. Diseases of the Esophagus. In: Cecil RL, Goldman L, Bennett JC, eds, Textbook of medicine. 21st edition. Saunders, Philadelphia, Vol 1, 2002;667.
5. McPhee ST, Papadakis MA. Pill-induced esophagitis. In: McPhee SJ, Papadakis M, Rabow MW, eds, Current medical diagnosis and treatment. 50th edition. McGraw Hill Professional, San Francisco, California, 2011;574-57.
6. Saçıkara M, Nazlıgöl Y, Kızılcıca G, Bulur O. Doksisisiklin özofajiti: İki olgu nedeniyle literatürün gözden geçirilmesi. Dicle Tıp Dergisi. 2010;37(3):297-9.
7. Shelat VG, Seah M, Lim KH. Doxycycline induced acute erosive oesophagitis and presenting as acute dysphagia. J Assoc Physicians India. 2011;59(1):57-9.
8. Akbayır N, Alkım C, Erdem L, Sakız D, Sökmen HM. A case report of doxycycline induced esophageal and gastric ulcer. Turk J Gastroenterol. 2002;13(4):232-5.
9. Öztürk S, Berçin S, Kırtak N. Doksisisikline bağlı gelişen özofajit ve ülser. Tıp Araştırmaları Dergisi. 2011;9(3):195-7.
10. Malekzadeh R. Doxycycline induced esophageal ulcer. Med J Islam Repub Iran. 1988;2(1):33-5.
11. Al-Mofarreh MA, Al Mofleh IA. Esophageal ulceration complicating doxycycline therapy. World J Gastroenterol. 2003; 9(3):609-11.
12. Tahan V, Sayrak H, Bayar N, Erer B, Tahan G, Dane F. Doxycycline induced ulceration mimicking esophageal cancer. Cases Journal. 2008;1:144.
13. Ramirez Ramos A, Valladares G, Barreda Costa C. Esophageal ulcers induced by doxycycline. Evaluation of 4 cases. Acta Gastroenterol Latinoam. 1981;11(2):309-13.
14. Huizar JF, Podolsky I, Goldberg J. Doxycycline induced esophageal ulcers. Rev Gastroenterol Mex. 1998;63(2):101-5.
15. Segelnick SL, Weinberg MA. Recognizing doxycycline-induced esophageal ulcers in dental practice: a case report and review. J Am Dent Assoc. 2008;139(5):581-5.