

Emergency surgical treatment of a percutaneous closure device complication in a patient with transfemoral transcatheter aortic valve implantation

Transfemoral transkateter aort kapak implantasyonu yapılan bir hastada perkütan kapatma cihazı komplikasyonunun acil cerrahi tedavisi

Nevzat Erdil , Barış Akça , Mehmet Cengiz Çolak 

Department of Cardiovascular Surgery, Medicine Faculty of İnönü University, Malatya, Turkey

Transfemoral, transsubclavian, transapical, and direct aortic access routes have been suggested for transcatheter aortic valve implantation (TAVI).^[1] Earlier, open surgical access was routinely used to introduce large sheaths and catheters. Transfemoral access route was the most widely used and also associated with vascular complications more frequently.^[2,3] Subsequently, percutaneous techniques have emerged as the new standard, resulting in a less invasive, fully percutaneous procedure. The aim of this case presentation is to share the management of Perclose proglide-based vascular closure failure in patient with transfemoral TAVI.

Case- A 64-year-old woman with chest pain and functional dyspnea Class III was referred to our institution with severe aortic stenosis. Transthoracic echocardiography revealed a mean aortic pressure gradient of 49 mmHg and aortic valve area of 0.65 cm² according to the continuity equation. The aortic annulus diameter which was measured using transesophageal echocardiography was 24 mm. There was no critical stenosis of the coronary arteries. The logistic EuroSCORE and Society of Thoracic Surgeons scores were calculated as 27% and 8.5%, respectively. The heart team decided to perform TAVI through the transfemoral access route.

After the successful deployment of a 26 mm CoreValve (Medtronic, Minneapolis, MN, USA) in to the aortic annulus, arteriogram for femoral closure to check the vessel patency revealed an unexpected occlusion with contrast dye in the common femoral artery (CFA) (Figure 1a, b). Radiological intervention such as thrombectomy or balloon dilatation was not considered due to the risk of rupture. Emergency surgery was decided for vascular repair. The CFA exploration

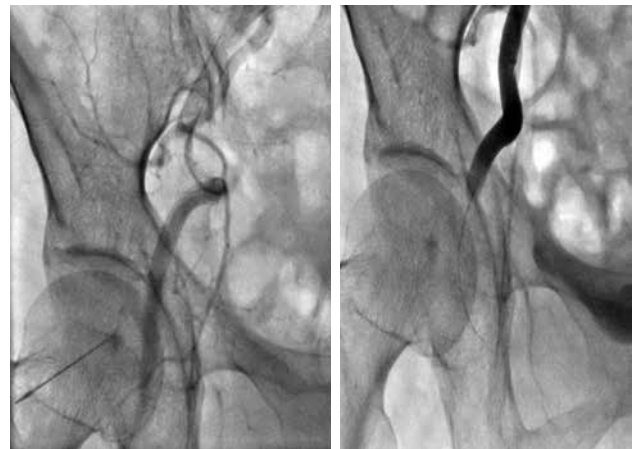


Figure 1. Arteriogram revealed the occluded common femoral artery with contrast dye.

Received: March 22, 2018 Accepted: March 30, 2018 Published online: June 11, 2018

Correspondence: Barış Akça, MD. İnönü Üniversitesi Tıp Fakültesi Kalp ve Damar Cerrahisi Anabilim Dalı, 44280 Malatya, Turkey.
e-mail: dr.baris.akca@yandex.com.tr

Citation:

Erdil N, Akça B, Çolak MC. Emergency surgical treatment of a percutaneous closure device complication in a patient with transfemoral transcatheter aortic valve implantation. Damar Cer Derg 2019;28(2):130-131.

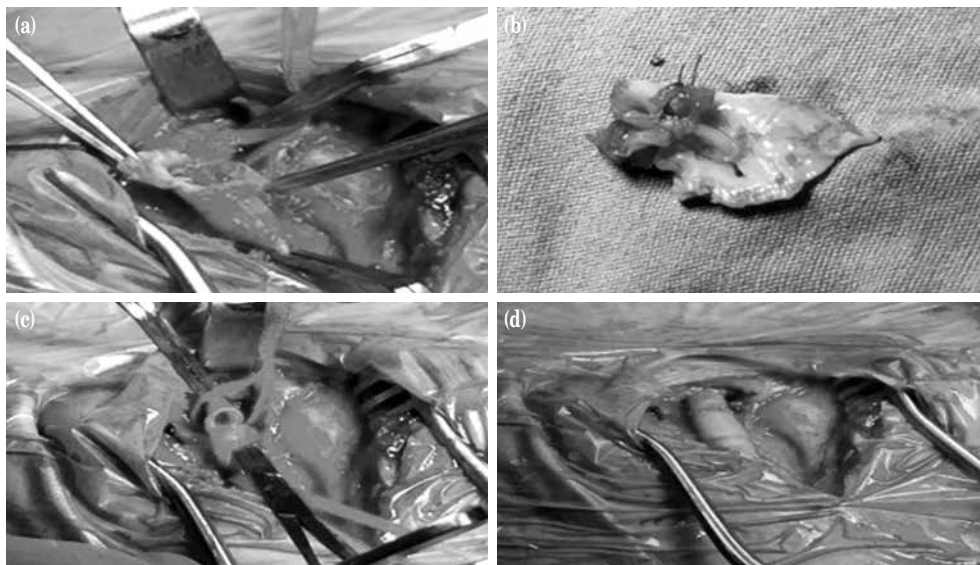


Figure 2. Common femoral artery exploration revealed the sutured walls of artery and occlusion by percutaneous closure device (a) also inner view of sutured arterial walls (b), occluded segment of artery was excised (c) and repaired with end to end anastomosis (d).

revealed the sutured walls of artery and occlusion by closure device (Figure 2a, b). The occluded segment of artery was excised and repaired with end-to-end anastomosis technique (Figure 2c, d). The postoperative course was uneventful and discharged after four days.

In conclusion, currently, fully percutaneous transcatheter aortic valve implantation procedure is the new standard with relatively small diameter introducers; however, vascular closure device failure can lead to serious complications and emergency surgery.

Declaration of conflicting interests

The authors declared no conflicts of interest with respect to the authorship and/or publication of this article.

Funding

The authors received no financial support for the research and/or authorship of this article.

REFERENCES

1. Ramlawi B, Anaya-Ayala JE, Reardon MJ. Transcatheter aortic valve replacement (TAVR): access planning and strategies. *Methodist DeBakey Cardiovasc J* 2012;8:22-5.
2. Akça B, Erdil N, Hidayet Ş, Çolak MC, Battaloğlu B. Unexpected contralateral femoral artery atheromatous plaque embolism after TAVI. *J Clin Anal Med* 2017;8(Suppl 1):20-2.
3. Cengiz Çolak M, Erdil N, Akça B, Dişli O, Erkul G, Özdemir R, et al. Yüksek riskli aort darlığı olan hastalarda transkateter aortik kapak implantasyonu sonrası vasküler komplikasyonlar. *Damar Cer Derg* 2015;24:166-71.