

Double-Rooted Maxillary Primary Canine: A Case Report and Literature Review

Cigdem Guler

Inonu University Faculty of Dentistry Department of Pediatric Dentistry, Malatya

Abstract

Primary teeth have fewer abnormalities with respect to size and morphology when compared to permanent teeth. Double-rooted primary canines are extremely rare dental anomaly. The present report describes seven years old Caucasian male child with double-rooted maxillary primary canine. This unusual root anatomy could lead to endodontic and extraction complications, as well as problems in permanent tooth eruption. In this case report, double-rooted maxillary right primary canine was restored with compomer and followed up 12 months. Any problems were not observed.

Key Words: Double-rooted primary canine, Root anomaly, Primary teeth

Introduction

The dental literature contains many articles on dental anomalies. Most of these articles report anomalies of the permanent dentition, because a smaller number of anomalies occur in the primary dentition than in the permanent dentition (1).

Primary teeth have fewer abnormalities with respect to size and morphology when compared to permanent teeth. Few primary teeth have additional roots and those that do are usually primary molars (2). Primary canines are normally single rooted. Double-rooted primary canines are an extremely rare dental anomaly, only a few cases of which have been reported since 1941 (1-19). Although the etiology of this anomaly is unknown, it has been suggested that it may be the result of an ingrowth of tissue from Hertwig's epithelial root sheath (9, 13-15, 19).

The present report describes a case of double-rooted maxillary primary canines.

Case Report

A seven years old Caucasian male child was brought to the Department of Paediatric Dentistry, Atatürk University, Erzurum, Turkey for treatment of pain in the maxillary right primary second molar. The child's medical history included no systemic disorders, allergies and trauma. He had no siblings. An intra-oral examination revealed a mixed dentition with multiple carious lesions. Periapical radiographs demonstrated a unilateral double-rooted maxillary right primary canine (Figure 1). The canine appeared to have distinct mesial and distal roots. Clinical examination showed the crown of this tooth to be normal in shape and size. In addition, this tooth has been carious lesion. The patient's other primary canines were single-rooted. Maxillary right primary second molar was performed pulpectomy and it was restored with stainless steel crown. All carious teeth restored with a colored

compomer. Double-rooted maxillary right primary canine was restored with compomer (Figure 2). Patient was followed up 12 months (Figure 3).

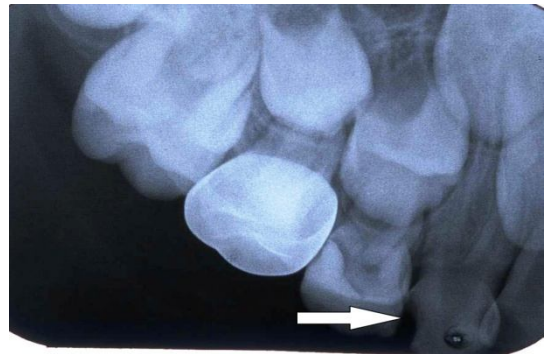


Figure 1. The periapical radiograph shows a double-rooted maxillary right primary canine.

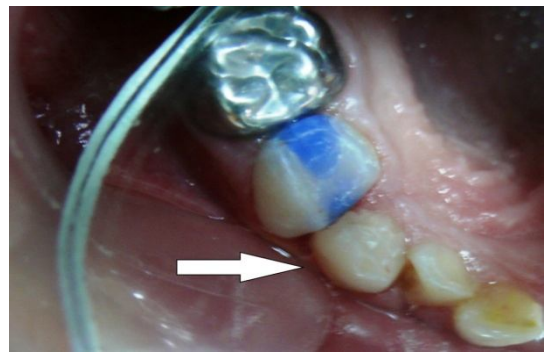


Figure 2. Intra-oral photograph of double-rooted maxillary right primary canine.

Discussion

This case report describes unilateral double-rooted maxillary primary canine. Double-rooted primary canines are an extremely rare dental anomaly. The prevalence of double-rooted primary canines appears to be higher in the maxilla than the mandibula, and this

anomaly occur more frequently in black, and male children, and bilaterally (Table 1).

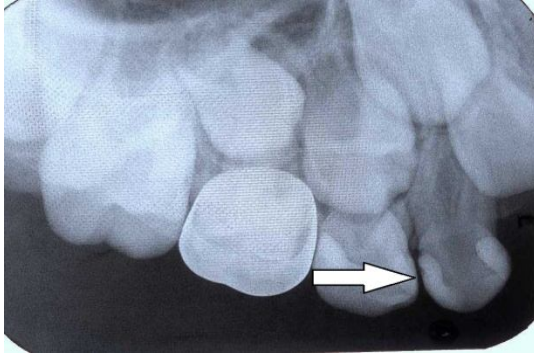


Figure 3. The periapical radiograph shows a double-rooted maxillary right primary canine after 12 months of treatment.

Our case was white male children, and double-rooted primary canine was located in the maxillary arch. In our case however, all four primary canines were

present, but only maxillary right primary canine was double-rooted.

The etiology of teeth with supernumerary roots is poorly understood. Several authors have postulated theories for the occurrence of this phenomenon. It has been demonstrated that bifurcation of roots may be relate to an ingrowth of Hertwig's epithelial root sheath (9, 13-15, 19).

In addition, the above data bring to mind the act that trauma or other disturbances during morpho-differentiation may affect root form and size in later periods.

Other researchers have suggested that fusion or gemination may be related to the clinical presentation of supernumerary roots (2). Such abnormalities may be genetically determined, or associated with environmentally induced cellular changes (2).

Table 1. Characteristics of the previously reported cases.

Authors	Year	Location of canine	Age (year)	Sex	Race
Takano (5)	1941	Mandibular Right	9	M	Japanese
Kurosu et al (6)	1968	Maxillary Right	8	F	Japanese
		Maxillary Left	8	M	Japanese
		Mandibular Right	8	M	Japanese
Yasunaga et al (3)	1978	Bilateral Maxillary and Bilateral Mandibular	6	M	Japanese
Hata et al (7)	1979	Bilateral Mandibular	4	M	Japanese
Mochuziki et al (2)	2001	Bilateral Maxillary and Bilateral Mandibular	6	M	Japanese
Brown (8)	1975	Bilateral Maxillary	4	F	Not reported
Kelly (9)	1978	Bilateral Maxillary	5	F	Black
Krolls and Donahue (10)	1980	Bilateral Maxillary	5	F	Black
Chow (11)	1980	Bilateral Maxillary	5	M	Black
Bryant and Bowers (4)	1982	Bilateral Maxillary and Bilateral Mandibular	5	M	Caucasian
Bimstein and Bystrom (12)	1982	Bilateral Maxillary	5	M	Black
Jones and Hazelrigg (13)	1987	Bilateral Maxillary	5	M	Black
Saravia (14)	1991	Bilateral Maxillary	4	F	Black
Hayutin and Ralstrom (15)	1992	Maxillary Right	4	F	Black
		Maxillary Right	1	M	Black
Winkler and Ahmad (16)	1997	Maxillary left	4	F	Pueblo
Orhan and Sari (17)	2006	Maxillary left	11	M	Caucasian
		Maxillary right	4	M	Caucasian
		Bilateral maxillary	6	M	Caucasian
Atac and Cetinguc (1)	2005	Bilateral maxillary	6	M	Caucasian
		Bilateral maxillary	6	M	Caucasian
Paulson et al (18)	1985	Bilateral maxillary	9	M	Black
Ott and Ball (19)	1996	Bilateral maxillary	8	M	Black
		Bilateral maxillary	4	M	Black
		Bilateral Maxillary and Bilateral Mandibular	8	M	Black
Present case	2012	Maxillary right	7	M	Caucasian

In the present case, however, there was no history of trauma and he had no siblings. Thus, double-rooted primary canine in the present case could not be attributed to a specific cause. This unusual root anatomy could lead to endodontic and extraction

complications, as well as problems in permanent tooth eruption (17). During exodontic procedures, the clinician should make sure that the crown of the permanent tooth is not trapped in the interradicular area of the primary tooth as this could cause accidental

removal of the developing permanent tooth (16). The clinician also should inspect extracted anomalous primary teeth to ensure that all roots have been retrieved (1). In our case patient was followed up 12 months and no problems were observed.

Double-rooted primary canines are extremely rare dental anomaly. This unusual root anatomy could lead to endodontic and extraction complications, as well as problems in permanent tooth eruption. In this case report, double-rooted maxillary right primary canine was restored with compomer and followed up 12 months. Any problems were not observed. The clinicians should be carefully for root anomalies.

References

1. Atac AS, Cetinguc A. Primary maxillary bilateral birooted canines: report of two cases. *Journal Of Hacettepe Faculty Of Dentistry* 2005; 29 (2): 24-8.
2. Mochizuki K, Ohtawa Y, Kubo S, Machida Y, Yakushiji M. Bifurcation, birooted primary canines: a case report. *Int J Paediatr Dent* 2001; 11: 380-5.
3. Yasunaga M, Tagashira N, Miura K, Inoue T. A case report; Bilateral bifurcation of the maxillary and mandibular deciduous cuspids. *Japanese Journal of Pediatric Dentistry* 1987; 16: 224-9.
4. Bryant RHJ, Bowers DF. Four birooted primary canines: report of case. *ASDC Journal Dent Child* 1982; 49: 441-2.
5. Takano H. Supernumerary rooted primary mandibular right canine. *Shika Geppo* 1941; 21: 48-50.
6. Kurosu K, Hattori R, Sugiyama J. Anomalies of the deciduous teeth. *Shikai Tenbo* 1968; 31: 505-17.
7. Hata Y, Itoh T, Nishimura Y, Uchida N, Mamiya M. An interesting case of lower bilateral bifurcated root canines in deciduous dentition. *Kanagawa Shigaku* 1979; 14: 177-83.
8. Brown CK. Bilateral bifurcation of the maxillary deciduous cuspids. *Oral Surg Oral Med Oral Pathol* 1975; 40: 817.
9. Kelly JR. Birooted primary canines. *Oral Surg Oral Med Oral Pathol* 1978; 46: 872.
10. Krolls SO, Donahue AH. Double-rooted maxillary primary canines. *Oral Surg Oral Med Oral Pathol* 1980; 49: 379.
11. Chow MH. Bilateral double-rooted maxillary primary canines an abbreviated case report. *Oral Surg Oral Med Oral Pathol* 1980; 50: 219.
12. Bimstein E, Bystrom EB. Birooted bilateral maxillary primary canines. *ASDC Journal Dent Child* 1982; 49: 217-8.
13. Jones JE, Hazelrigg CO. Birooted primary canines. *Oral Surg Oral Med Oral Pathol* 1987; 63: 499-500.
14. Saravia ME. Bilateral birooted maxillary primary canines: report of two cases. *ASDC Journal Dent Child* 1991; 58: 154-5.
15. Hayutin DJ, Ralstrom CS. Primary maxillary bilateral birooted canines: Report of two cases. *ASDC Journal Dent Child* 1992; 59: 235-7.
16. Winkler MP, Ahmad R. Multirooted anomalies in the primary dentition of Native Americans. *J Am Dent Assoc* 1997; 128: 1009-11.
17. Orhan AI, Sari S. Double-rooted primary canines: a report of three cases. *J Indian Soc Pedod Prev Dent* 2006; 24 (4): 204-8.
18. Paulson RB, Gottlieb LJ, Sciulli PW, Schneider KN. Double-rooted maxillary primary canines. *ASDC Journal Dent Child* 1985; 52: 195-8.
19. Ott NW, Ball RN. Birooted primary canines: report of three cases. *Pediatr Dent* 1996; 18: 328-30.

Corresponding Author

Assist. Prof. Dr. Cigdem GULER
Inonu University Faculty of Dentistry
Department of Pediatric Dentistry
MALATYA
e-mail: cigdem_zehir@yahoo.com