

# Cone beam computed tomographic findings in unicystic ameloblastoma of the mandible

Sachin Ram G, Vidya Ajila, Shruthi Hegde, Subhas Babu G, Jasmine Shanthi Kamath, Devika S Pillai

Department of Oral Medicine and Radiology A B Shetty Memorial Institute of Dental Sciences Nitte Deemed to Be University, Mangalore ,India

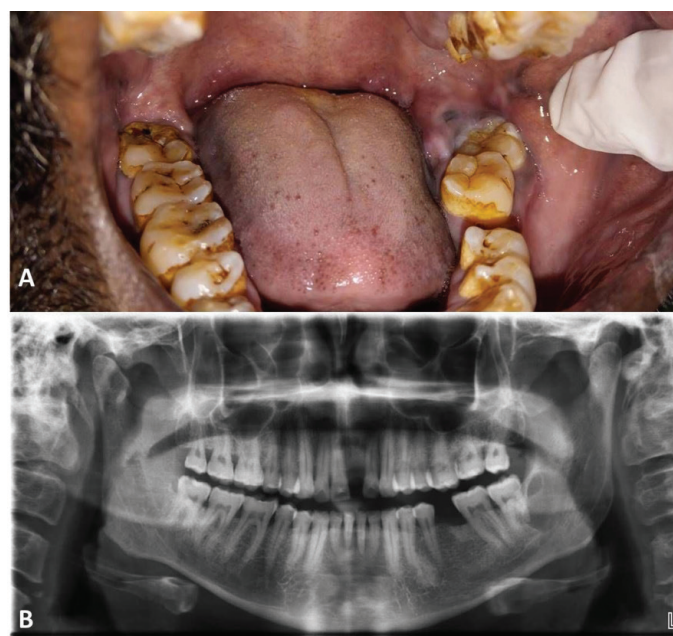## Dear Editor,

Ameloblastomas are one of the commonly encountered odontogenic tumours (1). Ameloblastomas are of the following types namely peripheral, solid or multicystic, unicystic, desmoplastic, and malignant (1,2). Unicystic ameloblastoma is a rare variant of ameloblastoma and accounts for around 6% of all ameloblastomas (1). Clinically and radiographically, it resembles a cyst but on histopathological examination has features of ameloblastoma (1). Cases with multilocular radiolucency and histopathology of unicystic ameloblastomas were earlier termed as cystic ameloblastomas. However, this term is no longer used; instead, the lesions are termed as unicystic ameloblastoma (1). The present case describes unicystic ameloblastoma of the posterior mandible in a 42 years old male patient.

A 42 years-old-male reported to our department with complaint of pain in the lower left back tooth region last 15 days. He gave history of a fall two weeks previously followed by continuous, throbbing, diffuse pain in the area of the lower jaw and on the right side of the face, radiating till the right ear. There was mild swelling and difficulty in eating and wide opening of the mouth. He consulted a dental practitioner who prescribed antibiotics and advised a panoramic radiograph. Panoramic radiograph showed a well- defined radiolucent lesion approximately 2x4 cms in size located distal to the mandibular left third molar. He was then referred to our institution.

Extraoral examination showed no abnormalities. On intraoral examination, a bluish white swelling approximately 1x1cms in size was present from distal and lingual to the crown of the mandibular left third molar. On palpation, the swelling was soft in consistency and non-tender. The third molar appeared to be displaced buccally due to the swelling (Figure 1A). The second and

third molars were vital on electric pulp testing. Panoramic radiograph showed a well-defined radiolucency approximately 3x4 cms in size distal to the mandibular left third molar. Superiorly the radiolucency extended to the alveolar crest and inferiorly, it surrounded the distal root of the third molar with evidence of root resorption. Medially the swelling was along the distal surface of the third molar and laterally extended around 4 cm distal to the third molar. There were no calcifications or loculations within the radiolucency (Figure 1B).



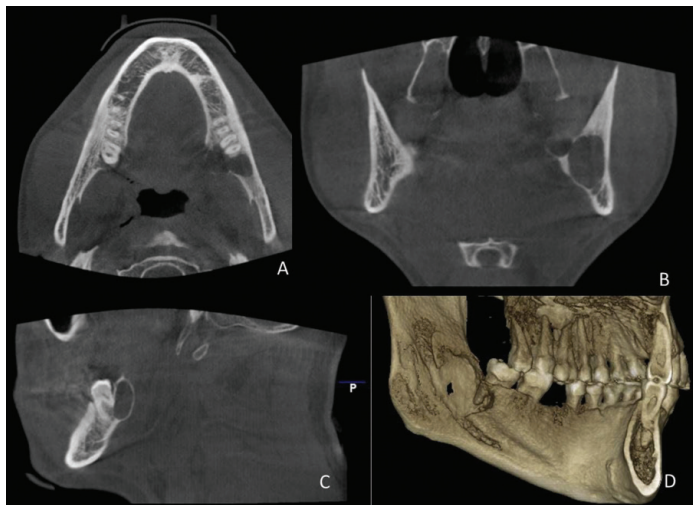
**Figure 1A.** Intraoral examination showed a bluish white swelling distal and lingual to the crown of the mandibular left third molar causing buccal displacement of the tooth,

**1B.** Panoramic radiograph showing well defined radiolucency 3x4 cms in size distal to the mandibular left third molar.

Received: 07.11.2017 Accepted: 27.12.2017

Corresponding Author: Vidya Ajila, Department of Oral Medicine and Radiology A B Shetty Memorial Institute of Dental Sciences Nitte University, Mangalore ,India, E-mail: ajila\_v@yahoo.com

The extent of the lesion was evaluated using Cone beam computed tomography. Axial sections showed lingual cortical plate expansion and perforation in 38 region. Coronal section showed well defined multilocular radiolucent lesion in the mandibular left third molar region. There was no evidence of root resorption in the mandibular left second molar (Figure 2).



**Figure 2.** Cone beam computed tomography showing well defined multilocular radiolucency with lingual cortical expansion and perforation.

Based on the clinical and radiographic features a provisional diagnosis of ameloblastoma was given. Surgical excision of the lesion was done. Histopathology showed presence of cystic lumen lined by ameloblastomatous epithelial lining of variable thickness and a fibrocellular connective tissue capsule. The epithelium showed proliferation at places within the lining and also into the connective tissue wall in the form of ameloblastomatous islands. A final diagnosis of unicystic ameloblastoma was made.

Unicystic ameloblastoma was first described by Robinson and Martinez in 1977 (3,4,5). It is traditionally considered to be less aggressive with a lower recurrence rate (5).

Currently, three mechanisms are proposed for development of unicystic ameloblastoma. The first theory states that reduced enamel epithelium in a developing tooth undergoes ameloblastic changes; the second is that ameloblastoma develops in a preexisting odontogenic cyst such as dentigerous, and the third theory mentions that a solid ameloblastoma may get converted to a unicystic variant by cystic degeneration (4,5).

The age of occurrence of UA is dependent on the association with an impacted tooth. Lesions with an impacted tooth occur around 20 years earlier with an average of 16 years as against 35 years for other lesions (4). The posterior mandible is the commonest site as was seen in our case (4). The male female ratio is 1:1.8 in cases not associated with an impacted tooth (1).

UA is usually asymptomatic, except for large lesions which can cause expansion of the jaws. (2). Radiographically, unicystic ameloblastomas are mainly unilocular

although multilocular variants have been reported. Various radiographic patterns have been described in literature such as unilocular, scalloped macromultilocular, pericoronal, interradicular and periapical expansile.

Unicystic ameloblastoma differs from multicystic ameloblastomas. The differences between unicystic and multicystic ameloblastomas is summarized in Table 1.

**Table 1.** Table showing the comparison of unicystic ameloblastoma and solid ameloblastoma. (1,6,10)

Features	Unicystic Ameloblastoma	Solid Ameloblastoma
Age	Associated with impacted tooth: Average 16 yrs. Not associated with impacted tooth: Average 35 yrs.	33-44 years
Male : Female ratio	1.6:1 (Associated with impacted tooth) 1:1.8 (Not associated with impacted tooth)	1.3:1
Site	Mandibular molar and the ascending ramus	Mandibular molar and the ascending ramus
Association with impacted tooth	52 to 100%.	15-40%
Radiographic features	Six radiographic patterns from unilocular to multilocular. Unilocular variant is more common. Unilocular: Multilocular Ratio: 13:3 (With impaction) Unilocular: Multilocular Ratio: 8:7 (Without impaction)	63-90% cases are multilocular often with a soap-bubble appearance
Histopathology	Monocystic lesion with a large cystic cavity and lining of ameloblastic cells.	Islands, strands of tumor epithelium with a central mass of polyhedral cells surrounded by a layer of cuboidal or columnar cells resembling pre-ameloblasts.
Treatment	Conservative surgical treatment- enucleation or curettage Mural type should be treated like solid ameloblastoma	Wide local excision and reconstruction or Conservative treatment : enucleation and curettage
Recurrence rate	25% (Lowest for intraluminal, plexiform type)	55-90% (1) : 15-25% after radical treatment 75-90% after conservative treatment. (7)

Diagnosis of unicystic ameloblastoma is by histopathology (4). The histopathological picture can be of simple cystic type, intraluminal and mural types. Management of UA varies accordingly. The management of ameloblastoma is dependent on factors such as clinical type, location in the jaws, age of patient; associated morbidity and availability for follow up examinations (6,7). Although conservative management has been advocated for most cases of UA, the mural variant is associated with high recurrence and should be treated like a solid ameloblastoma (2) Based on their study results, Girradi et al. (7) have recommended surgical resection for solid multicystic, desmoplastic and invasive and mural invasive unicystic ameloblastomas, and enucleation for luminal and intraluminal unicystic ameloblastomas while others recommend that curettage should be done only for unicystic ameloblastomas of the anterior mandible (8). They also found that tumor size greater than 6 cm or tumor invasion to soft tissues or adjacent anatomical structures were associated with early recurrence (8). Repeated recurrences were associated with malignant transformation with common sites of metastasis being the lung followed by the cervical lymph nodes, brain and bone (9).

In conclusion, the rapid increase in size of the lesion over a short period was the important feature of this case. Such feature in an innocuous unilocular radiolucency should always raise suspicion of an ameloblastoma rather than an odontogenic cyst.

## REFERENCES

1. Chaudhary Z, Sangwan V, Pal US, Sharma P. Unicystic ameloblastoma: a diagnostic dilemma. *Natl J Maxillofac Surg* 2011;2(1):89-92
2. Hsu MH, Chiang ML, Chen JK. Unicystic ameloblastoma. *Journal of Dental Sciences* 2014; 9: 407: e411
3. Nagalaxmi V, Sangmesh M, Maloth KN, Kodangal S, Chappidi V, Goyal S. Unicystic mural ameloblastoma: an unusual case report. *Case Rep Dent* 2013;2013:957418.
4. Philipsen HP, Reichart PA. Unicystic ameloblastoma. A review of 193 cases from the literature. *Oral Oncol* 1998;34(5):317-25
5. Deore SS, Dandekar RC, Mahajan AM, Patil R, Prakash N. Plexiform unicystic ameloblastoma: a rare variant of ameloblastoma. *Case Rep Dent* 2014;2914:146989.
6. Dandriyal R, Gupta A, Pant S, Baweja HH. Surgical management of ameloblastoma: conservative or radical approach. *Natl J Maxillofac Surg*. 2011;2(1):22-7.
7. Giraddi GB, Arora K, Saifi AM. Ameloblastoma: A retrospective analysis of 31 cases. *J Oral Biol Craniofac Res*. 2017;7(3):206-11.
8. Yang R, Liu Z, Gokavarapu S, Peng C, Ji T Cao W, Recurrence and cancerisation of ameloblastoma: multivariate analysis of 87 recurrent craniofacial ameloblastoma to assess risk factors associated with early recurrence and secondary ameloblastic carcinoma. *Chin J Cancer Res* 2017;29(3):189-95.
9. Lin Y, He JF, Li ZY, Liu JH. Ameloblastoma with varied sites of metastasis: report of two cases and literature review. *J Craniomaxillofac Surg* 2014;42(5):e301-4.