

A rare foreign body during colonoscopy: Headpiece of enema kit

Mehmet Patmano¹, Durmus Ali Cetin¹, Tufan Gumus¹, Sumeyra Yildirim²

¹Sanliurfa Training and Research Hospital, Department of General Surgery, Sanliurfa, Turkey

²Sanliurfa Training and Research Hospital, Department of Gastroenterology, Sanliurfa, Turkey

Copyright © 2018 by authors and Annals of Medical Research Publishing Inc.

Dear Editor;

Colonoscopy is procedure that is used to assess rectum and other colonic segments via anus. Colonoscopy is used in the diagnosis and management of many disorders including intestinal polyps, colon cancer, and inflammatory bowel diseases. Foreign body in colon can also removed via colonoscopy. Foreign body in rectum is a rarely seen condition (1,2). It has become increasingly more common in emergency departments with increasing incidence of its complications (3). Most cases with rectal foreign body are men including homosexuals, elders, and patients with mental disability or victims of sexual assault in particular (4). The patients are prescribed rectal enema preparations in addition to polyethylene glycol solutions, sodium phosphate preparations and oral purgative solutions for bowel preparation before colonoscopy. In this case report, it was aimed to present a rare foreign body encountered during elective colonoscopy in a 55-years old woman.

A 55-years old woman presented to our outpatient clinic with chronic constipation. The patient had no comorbid condition other than hypertension. She had no family history of colon cancer. The physical examination was found to be normal. In laboratory examinations, fecal occult blood test was found to be positive. Thus, colonoscopy was scheduled to the patient. Oral purgative solutions and rectal enema were prescribed to the patient for bowel preparation. The colonoscopy was performed under sedation in our endoscopy unit. During colonoscopy, green, plastic headpiece of enema kit (Fleet enema ®) was detected in rectum (Figure 1). It was removed using foreign body snare. No complication was recorded during procedure. After procedure, it was found that one of enemas was applied without removing headpiece by his daughter.

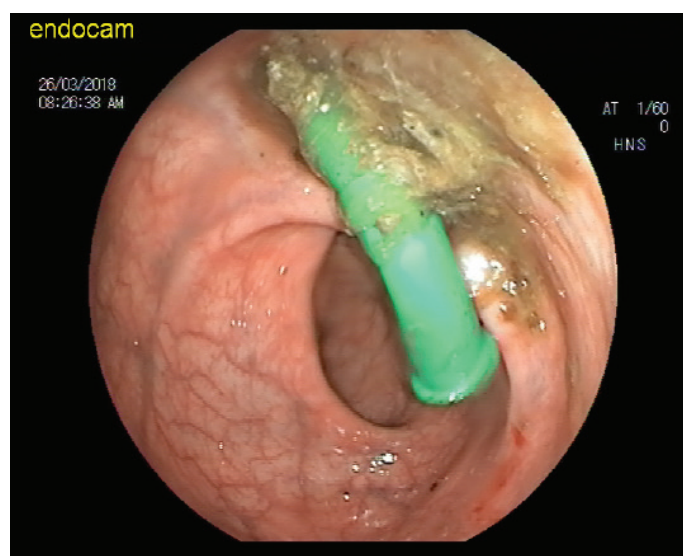


Figure 1. Plastic head piece of enema

Colonoscopy is an interventional method used in the treatment and management of colon and rectum diseases. Bowel preparation is a prerequisite for successful colonoscopy examination. Oral purgative solutions and rectal enemas are commonly preferred for bowel preparation. The enema preparations supplied by pharmacy and applied by patients or their relatives should be described accurately. It has been observed that there is an increase in cases with rectal foreign body. The patients are generally middle-aged men or homosexual individuals. It is more common among European community than Asia (1,2,5). The etiology includes several reasons. In a study on 76 patients by Kurer et al., it was found that 48.7% used foreign body for sexual purposes and 25% used for hemorrhoid disease or relieving anal itching while remaining patients were subjected to

Received: 11.06.2018 Accepted: 15.07.2018 Available online: 18.07.2018

Corresponding Author: Mehmet Patmano, Sanliurfa Training and Research Hospital, Department of General Surgery, Sanliurfa, Turkey
E-mail: mpatmano@yahoo.com

assault or trauma. In our patient, rectal foreign body was due to inaccurate use of enema prescribed. A better anamnesis can be obtained by adequate communication and assurance. The most prominent symptoms are pain and fullness at anal region (4,6). Our patient had no symptoms. During physical examination, digital rectal and perianal examinations are particularly important in patients presenting with foreign body. Plain abdominal radiographs of computerized tomography scan can be used in suspicious perforation. The localization of foreign body is important for therapeutic approach. In cases without suspicious perforation, foreign body removal with anal dilations should be attempted under sedation, if possible, in objects at the level of rectal ampulla or digital rectal examination (7). Foreign bodies at more proximal levels, rigid sigmoidoscopy is successful in diagnosis and localization but it is inadequate for removal. Flexible rectosigmoidoscopy is successful in both diagnosis and treatment (8,9). We removed headpiece of enema by using snare. We think that this rare, preventable case developed due to inaccurate applications should be kept in mind and endoscopy team should more careful.

In conclusion, we think that healthcare staff in endoscopy unit and pharmacy staff supplying drugs should be more careful when informing patients and their relatives about use of preparations for bowel preparation, particularly in illiterate patients with lower socioeconomic levels.

Competing interests: The authors declare that they have no competing interest.

Financial Disclosure: There are no financial supports

REFERENCES

1. Narjis Y, Rabbani K, Hakkou K, et al. Foreign body of rectum: An unusual case. *J Emerg Trauma Shock* 2010;3:306
2. Kurer MA, Davey C, Khan S, et al. Colorectal foreign bodies: a systematic review. *Colorectal Dis* 2010;12:851-61.
3. Pinto A, Micle V, Pinto F, et al. Rectal foreign bodies: imaging assessment and medicolegal aspect. *Semin Ultrasound CT MR* 2015;36:88-93.
4. Atilla K, Sökmen S, Astarcioglu H, et al. Rectal foreign bodies: a report of four cases. *Ulus Travma Acil Cerrahi Derg* 2004;10:253-6.
5. Safioleas M, Stanatakos M, Safioleas C, et al. The management of patients with retained foreign bodies in the rectum: from surgeon with respect. *Acta Chir Belg* 2009;109:325-5.
6. Boopathy V, Palaniswamy M. A giant complex rectosigmoid bezoar with multiple foreign bodies: a first of its kind. *BMJ Case Rep* 2014;2014.
7. Arıkan S, Akıncı M, Gülen M. Rectal Foreign Bodies and Treatment. *J Colon Rectum Diseases* 1998;8:38-40.
8. Singasporewalla RM, Tan DE, Tan TK. Use of endoscopic snare to extract a large rectosigmoid foreign body with review of literature. *Surg Laparosc Endosc Percutan Tech* 2007;17:145-8.
9. Van der Wouden EJ, Westerveld BD. Extraction of a rectal foreign body using a custom-made giant snare. *Endoscopy* 2010;42:122.