

Comparison of glutathion-s-transferase A-4 expression values between lumbar spinal canal stenosis and lumbar discal hernia patients

Tayfun Cakir¹, Seyho Cem Yucetas²

¹Erzincan Binali Yıldırım University, Faculty of Medicine, Department of Neurosurgery, Erzincan, Turkey

²Adiyaman University, Faculty of Medicine, Department of Neurosurgery, Adiyaman, Turkey

Copyright © 2019 by authors and Annals of Medical Research Publishing Inc.

Abstract

Aim: To compare the glutathione s-transferase α -4 (GSTA4) isoenzymes expression values in patients with lumbar spinal canal stenosis (LSCS) due to ligamentum flavum (LF) hypertrophy with patients no evidence of LF hypertrophy.

Material and Methods: 27 LF specimens were obtained from patients with LSCS and 27 LF specimens were obtained from patients with lumbar discal hernia (LDH). Firstly these LF samples were analyzed histologically to identify the fibrosis and elastin degradation values. Then GSTA4 isoenzyme values were measured and compared.

Results: The mean LF thickness was significantly higher in the LSCS group than in the LDH group (6.72 ± 0.86 and 3.1 ± 0.7 mm, respectively, $p < 0.005$). Average elastin degradation degree was significantly higher in the LSCS group than LDH group (4.4 ± 0.50 vs. 0.18 ± 0.1 , respectively, $p < 0.001$). And average fibrosis degree was significantly higher in the LSCS group than LDH group (4.41 ± 0.17 vs. 0.96 ± 0.11 , respectively, $p < 0.001$). And significantly higher expression of GSTA4 isoenzyme was observed in the LF samples obtained from patients with LSCS compared with controls (144.1 ± 11.16 vs 51.75 ± 21.53 , respectively, $p = 0.009$).

Conclusion: Our findings in this study suggest that there is a relationship between LF hypertrophy and GSTA4 isoenzyme expression.

Keywords: Ligamentum flavum hypertrophy; glutathione s transferase; spinal stenosis

INTRODUCTION

Lumbar spinal canal stenosis (LSCS) which causes narrowing of the spinal canal and compression of neural structures is a common finding in spine imaging of the population (1,2). As known ligamentum flavum (LF) hypertrophy is one of the most common causes of LSCS (1,3). And after widespread use of magnetic resonance imaging (MRI), the importance of LF hypertrophy gradually increased. To date, many histopathological and biochemical studies have been performed to reveal the mechanism of LF hypertrophy. Especially presence of increased fibrosis and elastin degradation had been mentioned in the hypertrophied LF tissues (4-6). In addition many immunological and biochemical studies tried to explain the causes of LF hypertrophy. Nevertheless, according to the previous studies, the detailed molecular

mechanism underlying LF hypertrophy has not been entirely understood (7-9). As known in the fibrotic tissues, epithelium injury is balanced by some mechanisms that restore normal epithelial structure and function (7). Furthermore in cases of fibrosis, usually this balance deteriorates and excessive epithelial damage occurs in the tissues (7,8). Some xenobiotics and their metabolites have been blamed for this situation. Namely toxic effects of xenobiotics and their metabolites must be neutralized by some enzymes such as glutathione s-transferases (GSTs) (4,8). The GSTs participate in detoxification of xenobiotics by conjugation with glutathione (3,4,9). In particular glutathione s-transferase α -4 (GSTA4) is thought to be related in tissue and cell defense against oxidative stress (8,9). So here we investigated GSTA4 expression values in patients with LSCS due to LF

Received: 14.09.2019 Accepted: 19.11.2019 Available online: 09.01.2020

Corresponding Author: Tayfun Cakir, Erzincan Binali Yıldırım University, Faculty of Medicine, Department of Neurosurgery, Erzincan, Turkey E-mail: tayfuncakir198375@gmail.com

hypertrophy by comparing with patients with no evidence of LF hypertrophy. We tried to prove the hypothesis that high levels of GSTA4 expression are positively correlated with LF hypertrophy and LSCS. According to our best knowledge this is the first study to reveal the relationship between GSTA4 isoenzymes and LF hypertrophy.

MATERIAL and METHODS

Patients

This study included 54 individuals who referred with complaints of low back and/or leg pain and underwent lumbar magnetic resonance imaging (MRI) (1.5-Tesla scanner MRI, MagnetomAera, SIEMENS) between 2013 to 2016 years in Kars Kafkas University Medical Faculty Hospital. All experimental procedures were carried out with the approval of the ethics committee of the Erzincan BinaliYıldırım University Medical Faculty (session number: 2013/32-3).

Patients with a history of previous lumbar spine surgery, spondylolisthesis, and history of malignancy, spinal trauma, arthritis, congenital spinal anomalies, discitis, scoliosis, and osteomyelitis were excluded.

2 groups of patients were created in the study. 27 LF specimens were obtained from patients with LSCS (<10 mm canal width) and underwent total or unilateral wide laminectomy and 27 LF specimens were obtained from patients underwent hemipartial laminectomy due to one sided LDH without findings of LSCS on MRI.

Sample collection

The whole layer of the LF samples were obtained during surgical intervention from all patients and these samples were thoroughly cleaned from epidural adipose tissues.

Measurement of spinal canal diameter and LF

For all the patients LF thickness and antero-posterior diameter of the spinal canal from posterior rim of vertebral body to anterior rim of the lamina and LF thickness where it was seen along its entire length was measured on the axial T1-weighted image that was perpendicular to the axis of the spinal canal and parallel to the laminae, within the preceding 8 weeks at most on the MRI (SIEMENS, AEREA, 1.5 Tesla) (Figure 1).

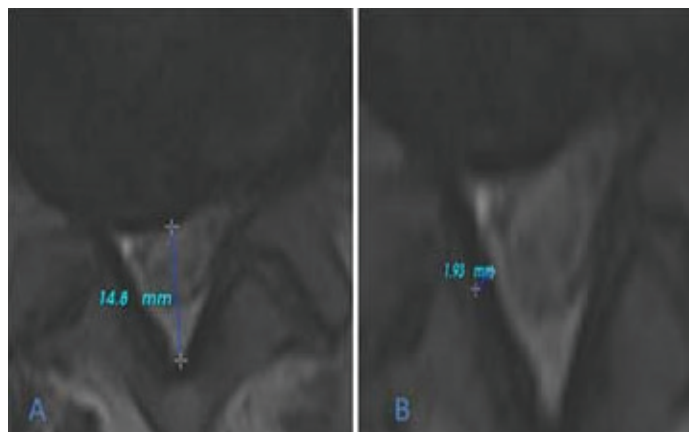


Figure 1. Measurement of anteroposterior diameter of the spinal canal (A) and measurement of the LF thickness (B)

Measurements were repeated three times by both of the authors with the help of a radiologist who was blinded for this study. The average of the repeated measurements was used as the final value.

Histological Analysis

LF specimens were fixed in 4% neutral formalin, decalcified with ethylenediaminetetraacetic acid and then embedded in paraffin for histological analysis by an experienced pathologist.

Masson's trichrome stain

The amount of LF fibrosis was graded according to the rating system presented by Sairyo et al.(10). According to the this grading system, normal tissues showing no fibrotic region indicate grade 0, fibrosis at the < 25% of the tissues indicate grade 1, fibrosis between 25% and 50% indicate grade 2, fibrosis between 50% and 75% indicate grade 3 and fibrosis > 75% indicate grade 4.

Hematoxylin-eosin stain

The amount of LF elastin degradation was also graded according to the scoring system presented by Sairyo et al. (10). Normal tissues showing no elastin degradation indicate grade 0, elastin degradation at < 25% of the entire area indicate grade 1, elastin degradation between 25% and 50% indicate grade 2, elastin degradation between 50% and 75% indicate grade 3 and more than %75 elastin degradation indicate grade 4.

Immunohistologic analysis

Tissue fragments were cut on a microtome, deparaffinized in xylene and rehydrated in alcohol solutions. After electrophoresis, proteins were transferred to a polyvinylidenedifluoridemembrane (Millipore, StQuentin, Yvelines, France). After blocking the nonspecific binding sites, membranes were incubated with a solution of anti-rabbit GSTA4 serum (1:100) (rabbit anti- GSTA4; Sigma-Aldrich products, Merck KGaA, Darmstadt, Germany). For the internal control, glyceraldehyde-3-phosphate dehydrogenase (GAPDH) was used (GAPDH Monoclonal Antibody (6C5), ThermoFisher Scientific US). Imaging Densitometer GF670 and molecular analysis software (Bio-Rad, SAFC Bioscience, Sigma-Aldrich) were used for each sample, and the average was used as the final density. The density is presented as the mean±standard deviation (arbitrary units).

Statistical Analysis

Data were expressed as the mean and range. The Mann-Whitney U test was used to evaluate the differences in the degree of LF elastin degradation, fibrosis and mean optical density (OD) between the 2 groups. A p value of less than 0.05 was considered statistically significant. All data were analyzed using SPSS version 12 statistical analysis software (SPSS Inc, Chicago, IL).

RESULTS

Demographic Data

The mean age of the LSCS group was 53.6 years (range from 37 to 79), the mean weight 87.8 kg (range from 54 to 99.2) and the mean height was 166.1 cm (range from

157.5 to 184). 15 of the patients in this group were males and 12 of them were females.

The mean age of the patients of the LDH group was 50.3 years (range from 31 to 61), the mean weight 88.9 kg (range from 55 to 102) and the mean height was 162.8 cm (range from 151 to 179). 17 of the patients in this group were males and 10 of them were females.

There were no significant differences in age (p=0.140), sex (p=0.431), weight (p=0.61), height (p=0.513) between the groups. Participant characteristics are presented in Table 1.

MRI findings

In the LSCS group, mean anteroposterior diameter of spinal canal was 9.4 mm (range 6.4-11) and mean LF thickness was 6.72±0.86 mm (range, 4.9 to 9.9).

In the LDH group mean anteroposterior diameter of spinal canal was 18.7 mm (range 13.1-29.8) and mean LF thickness was 3.1±0.7mm (range, 2.0 to 6.4). There were significant differences between the groups about the LF thickness (p <0.005) and spinal canal width (p<0.001).

Elastin Degradation and Fibrosis of the LF

Average elastin degradation degree was significantly higher in the LSCS group than LDH group (4.4±0.50 vs. 0.18±0.1, respectively, p< 0.001) (Figure 2).

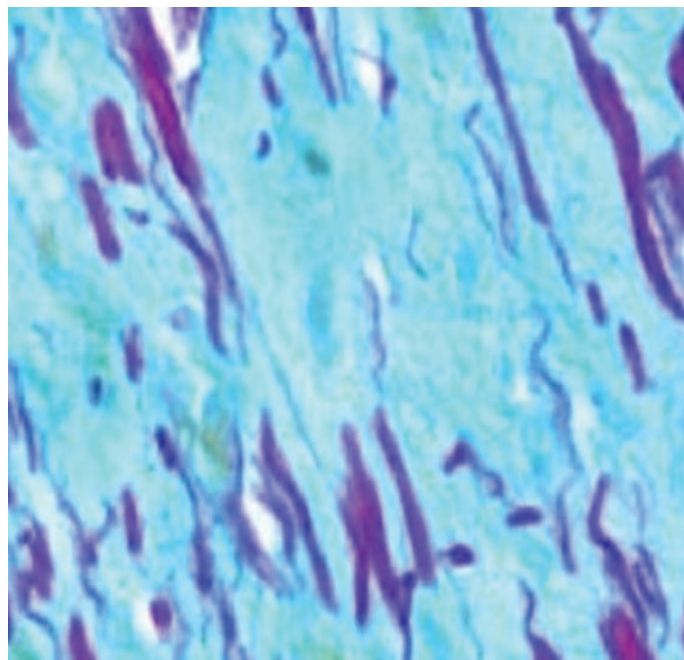


Figure 2. Grade of elastin degradation of the ligamentum flavum was seen very high in a patient operated due to LSCS, irregularly arranged, ruptured, swollen elastic fibers were seen (grade 4, elastin degradation)

And average fibrosis degree was significantly higher in the LSCS group than LDH group (4.41±0.17 vs. 0.96±0.11, respectively, p< 0.001) (Figure 3).

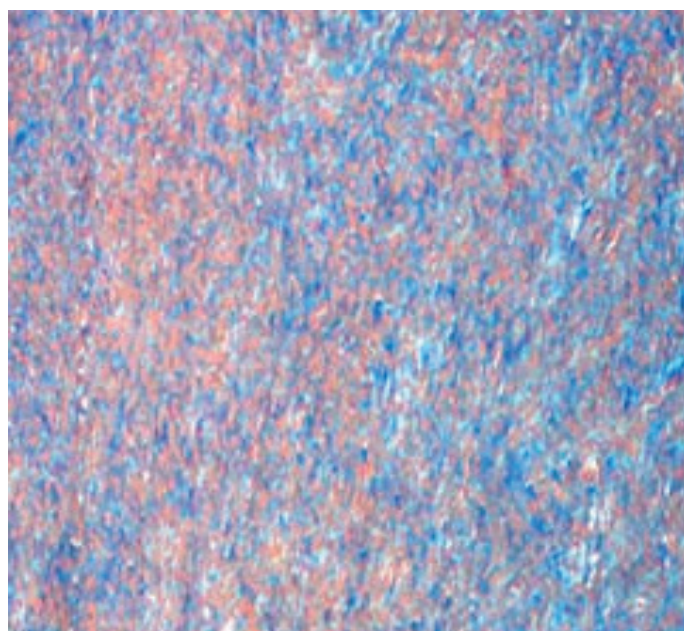


Figure 3. Grade of fibrosis of the LF was seen very high in a patient operated due to LSCS, most of the area of LF was stained a blue color, indicating the disarranged fibrous tissues, fibrous cartilage and ossification of the fibrous tissues (grade 4)

Table 1. Patients demographics and histological findings

	Patients with LDH (n=30)	Patients with LSCS (n=30)
No.(Male/Female)	27(16/11)	27(17/10)
Age	50.3 (range 31.0-61.0)	53.6(range 37.0-79.0)
Sex(F/M)	12(44.4%)/15(55.6%)	10(37%)/17(66%)
Weight	88.9 (range 55-102)	87.8(range 54-99.2)
Height	162.8(range 151-179)	166.1(range 157.5-184)
Operation level (number of patients)	L4-L5 (n=27)	(L4-L5 (n=27)
LF thickness,mm	3.1±0.7 (range 2.0–6.4)	6.72±0.86 (range 4.9–9.9)
Anteroposterior diameter of spinal canal,mm	18.7 (range 13.1-29.8)	9.4 (range 6.4-11)
Mean grade of elastin degradation	0.18 ± 0.1	4.4 ± 0.50
Mean grade of fibrosis	0.96 ± 0.11	4.41 ± 0.17
Mean OD of GSTA4	51.75 ± 21.53	144.1 ± 11.16

lumbar discal herni(LDH)
lumbar spinal canal stenosis(LSCS)
ligamentum flavum(LF)
optical density(OD)

GSTA4 expression

Gelatin zymography of the LF cell culture supernatants showed an increase in GSTA4 activity (average OD=144.1±11.16) in the LF samples obtained from LSCS group. But in the LDH group fewer GSTA4 values (average OD=51.75±21.53) were found (Figure 4).




Figure 4. GSTA4 and GAPDH expressions of all the patients

DISCUSSION

LSCS is a common disease which is generally associated with pain, weakness or numbness in the legs, calves or buttocks in addition to low back pain (11,12). According to the previous studies osteoproliferation of the lamina and facet joints, disc protrusion and LF hypertrophy have been known as the main causes of LSCS. But many studies have emphasized that LF hypertrophy is one of the most effective causes of LSCS. As the LF thickens, the spinal canal begins to narrow, neural structures become trapped within the canal and symptoms appear (13). Hansson et al. (14) in the study which they investigated the causes of spinal canal narrowing in the LSCS disease stated that especially ventral protrusion of the LF is the most common cause creating neural structures compression in the lumbar spinal canal. Amudong et al. (1), found that the average thickness of the hypertrophic LF was more than 5 mm in the LSCS patients. Also they saw increased fragility, partly calcified LF tissues, fibrosis, and elastin degradation in the hypertrophied LF samples histologically. Park et al. (15) found that the average thickness of the LF was 4.44 mm in patients with hypertrophy and 2.44 mm in patients without hypertrophy. Similar to the previous studies, in our study, LF thickness was significantly higher in the LSCS group. And fibrous tissue increase and excessively elastin degradation were found in the hypertrophic LF specimens obtained from LSCS group in accordance with previous studies. (16,17,18). Actually repeated mechanical stretching due to instability has been reported as the main reason for regional scar formation, fibrosis, and elastin degradation of the LF (1,10,11,12,15). But the exact mechanism underlying LF hypertrophy has yet to be elucidated (1,10). It is widely believed that many biochemical and genetic mechanisms may also exist for LF hypertrophy. As a sample Amudong et al. (1) found that

TGF- β expression was closely related to hypertrophy of the LF. Nakamura et al. (19) identified that Angiotensin-Like Protein 2 was a key mediator linked to LF degeneration and hypertrophy. Yan et al. (20) showed that increased insulin-like growth factor-1 promotes the synthesis of collagen I and collagen III via the mTORC1 signaling pathway, and causes LF hypertrophy, and LSCS disease. In our present study, we found statistically higher GSTA4 activity in the LSCS group. As known GSTs are a complex multigene family of detoxification enzymes and they play a central role in the defense against intracellular toxicants of diverse xenobiotics and oxidative stress (3, 21). GSTs are divided into classes such as alpha, pi, mu, theta, and each class has its own isoenzymes. Previous studies have shown that particularly α -class of glutathione transferase isozymes have a more important role in regulating oxidative stress by catalyzing conjugation of 4-hydroxynonenal (4-HNE) and facilitating its exclusion out of the cells (22,23). Ronis et al. (21) demonstrated that deletion of GSTA4 gene resulted in increased progression of fibrosis in liver tissues. Also Luo et al. (23) reported that GSTA4 inhibited fibrosis and tissue proliferation in smooth muscle cells. Further, according to the study of Luo et al., increase in functions of GSTA4 enzymes helped to maintain the smooth muscle cells quiescent status and inhibit their proliferation and fibrosis. And Xu et al. (24) identified that overexpression of human GSTA4 in carotid artery prevented neointima formation after carotid allograft in rabbits.

According to all these results it has been understood that GSTA4 tends to increase in the case of tissue proliferation. This is the 1st study on the relationship between LF hypertrophy and GSTA4 enzyme. We are of the opinion that these findings in this present study will shed light on new treatment methods about LSCS.

CONCLUSION

This study showed that elastin degradation and increased fibrosis were closely associated with LF hypertrophy similar to the many previous histological studies. In addition, our findings suggest that increased expression of GSTA4 is related with LF hypertrophy in patients with LSCS. This finding may serve as a target for novel strategies and be an important place in the prevention and treatment of LSCS, which is a common disease in the elderly population that decreases the quality of life.

Competing interests: All procedures were carried out with the approval of the ethics committee of the Erzincan Binali Yildirim University Medical Faculty.

Financial Disclosure: There are no financial supports.

Ethical approval: All experimental procedures were carried out with the approval of the ethics committee of the Erzincan Binali Yildirim University Medical Faculty (session number: 2013/32-3).

Tayfun Cakir ORCID: 0000-0002-9979-9291

Seyho Cem Yucetas ORCID: 0000-0001-6421-724X

REFERENCES

1. Amudong A, Muheremu A, Abudouexiti T. Hypertrophy of the ligamentum flavum and expression of transforming growth factor beta. *J Int Med Res* 2017; 45:2036-41.
2. Melancia JL, Francisco AF, Antunes JL. Spinal stenosis. In *Handbook of clinical neurology* 2014;119,541-9.
3. Awasthi YC, Ramana KV, Chaudhary P, et al. Regulatory roles of glutathione-S-transferases and 4-hydroxynonenal in stress-mediated signaling and toxicity. *Free Radical Biology and Medicine* 2017;111, 235-43.
4. Gokpınar D, Ozlece H K, Akyüz O, et al. Lomber Spinal Stenozda Ligamentum Flavum Hipertrofinin Transforming Growth Factor Beta-1 İle İlişkisi. *Journal of Contemporary Medicine* 2017;7:13-6.
5. Habig WH, Pabst MJ, Fleischner G, et al. The identity of glutathione S-transferase B with ligandin, a major binding protein of liver. *Proc Natl AcadSci* 1974;71:3879-82.
6. Karagianni P, Rallis D, Fidani L, et al. Glutathion-S-Transferase P1 polymorphisms association with broncopulmonary dysplasia in preterm infants. *Hippokratia* 2013;17:363-7
7. Yoshida M, Shima K, Taniguchi Y, et al. Hypertrophied ligamentum flavum in lumbar spinal canal stenosis. Pathogenesis and morphologic and immunohistochemical observation. *Spine* 1992;17:1353-60.
8. McMillan DH, van der Velden JL, Lahue KG, et al. Attenuation of lung fibrosis in mice with a clinically relevant inhibitor of glutathione-S-transferase π . *JCI Insight* 2016;2:85717.
9. Mazzetti AP, Fiorile MC, Primavera A, et al. Glutathione transferases and neurodegenerative diseases. *Neurochem Int* 2015;82:10-8.
10. Sairyo K, Biyani A, Goel VK, et al. Lumbar ligamentum flavum hypertrophy is due to accumulation of inflammation related scar tissue. *Spine* 2007;32:340-7.
11. Ishimoto Y, Yoshimura N, Muraki S, et al. Associations between radiographic lumbar spinal stenosis and clinical symptoms in the general population: the Wakayama Spine Study. *Osteoarthritis and Cartilage* 2013;21:783-8.
12. Yüçetas SC, Çakır T. Decreased catalase expression is associated with ligamentum flavum hypertrophy due to lumbar spinal canal stenosis, *Medicine* 2019;98:15192.
13. Saito T, Yokota K, Kobayakawa K, et al. Experimental mouse model of lumbar ligamentum flavum hypertrophy. *PloS one* 2017;12:0169717.
14. Hansson T, Suzuki N, Hebelka H, et al. The narrowing of the lumbar spinal canal during loaded MRI: the effects of the disc and ligamentumflavum. *European Spine J* 2009;18:679-86.
15. Park JB, Kong CG, Suhl KH, et al. The increased expression of matrix metalloproteinases associated with elastin degradation and fibrosis of the ligamentum flavum in patients with lumbar spinal stenosis. *ClinOrthopSurg* 2009;1:81-9.
16. Gopinathan P. Lumbar spinal canal stenosis-special features. *journal of orthopaedics* 2015;12:123.
17. Zhang K, Sun W, Liu XY, et al. Hypertrophy and fibrosis of the ligamentum flavum in lumbar spinal stenosis is associated with increased expression of LPA and LPAR1. *Clinical spine surgery*, 2017;30:189-91.
18. Sun C, Tian J, Liu X, et al. MiR-21 promotes fibrosis and hypertrophy of ligamentumflavum in lumbar spinal canal stenosis by activating IL-6 expression. *Biochemical and biophysical research communications*, 2017;490:1106-11.
19. Nakamura T, Okada T, Endo M, Kadomatsu T, et al. Angiopoietin-like protein 2 induced by mechanical stress accelerates degeneration and hypertrophy of the ligamentum flavum in lumbar spinal canal stenosis. *PloS one*, 2014;9:85542.
20. Yan B, Huang M, Zeng C, et al. Locally Produced IGF-1 Promotes Hypertrophy of the LigamentumFlavum via the mTORC1 Signaling Pathway. *Cellular Physiology and Biochemistry*, 2018;48:293-303.
21. Ronis M, Mercer K, Engi B, et al. Global Deletion of Glutathione S-Transferase A4 Exacerbates Developmental Nonalcoholic Steatohepatitis. *The American journal of pathology*, 2017;187:418-30.
22. Ramsay EE, Dilda PJ. Glutathione S-conjugates as prodrugs to target drug-resistant tumors. *Frontiers in pharmacology* 2014;5:181.
23. Luo J, Chen G, Liang M, et al. Reduced Expression of Glutathione S-Transferase $\alpha 4$ Promotes Vascular Neointimal Hyperplasia in CKD. *Journal of the American Society of Nephrology*, 2018;29:505-17.
24. Xu Y, Gong B, Yang Y, et al. Adenovirus-mediated overexpression of glutathione-s-transferase mitigates transplant arteriosclerosis in rabbit carotid allografts. *Transplantation* 2010;89:409-16.