

Fatal systemic juvenile xanthogranuloma with multiple central nervous system lesions

 Tumay Bekci¹,  Serdar Aslan¹,  Ismet Mirac Cakir¹,  Muhammet Bulut²

¹Department of Radiology, Faculty of Medicine, Giresun University, Giresun, Turkey

²Department of Pediatrics, Faculty of Medicine, Giresun University, Giresun, Turkey

Copyright@Author(s) - Available online at www.annalsmedres.org

Content of this journal is licensed under a Creative Commons Attribution-NonCommercial 4.0 International License.



Dear Editor,

Juvenile xanthogranuloma (JXG) is a rare and benign proliferative disease of histiocytes (1). Its systemic form is rarer and while the condition is benign, prognosis is poor (1). Extra-cutaneous involvement of JXG can be seen in the eyes, lungs, liver, spleen, adrenals, gonads, kidneys, bowels, retroperitoneum, and rarely, central nervous system (CNS) (1,2). In current literature, systemic JXG cases with multiple CNS lesions with fatal outcome are very rare. The purpose of this case study is to present magnetic resonance imaging (MRI) findings of an 18-month-old patient with JXG who presented with multiple CNS lesions and later developed skin lesions. To the best of our knowledge, there are no reports in the literature of cases where skin lesions developed after presentation of isolated CNS lesions.

CASE

An 18-month-old female infant was brought to our hospital by her family with a complaint of generalized seizure lasting 30 minutes. The patient's physical examination and laboratory findings were normal. Levetiracetam (2x120 mg) was started and seizure was controlled. Subsequently a brain CT was performed for seizure etiology. CT showed peripherally hypodense lesions in both cerebral hemisphere and in cerebellum (Figure 1). Brain MRI demonstrated peripheral hyperintense and central isointense lesions on T1-weighted (T1W) MRI images, and peripheral hypointense and central hyperintense lesions on T2-weighted (T2W) MRI images with surrounding vasogenic edema in the white matter of hemispheres and in the cerebellum. Lesions showed well contrast enhancement following intravenous contrast media administration (Figure 2). Infectious etiology tests including PPD skin test for tuberculosis, CMV/EBV PCR and galactomannan antigen test for fungal manifestations were all normal. Cerebrospinal fluid analysis, abdominal ultrasonography,

and bone survey were normal. Electroencephalogram was normal. As a result of stereotactic brain biopsy from cerebellar lesion, histopathological examination of the lesion showed intense histiocytic proliferation and granulomatous inflammation. The patient was placed on Vinblastine (2 mg/m²i.v) and with a diagnosis of isolated CNS involvement of JXG. Steroid treatment was started because of edema surrounding brain lesions. Numerous skin lesions measuring 0.5 mm and in the shape of round papules were found on hairy skin at the sixth month of the diagnosis. Unfortunately, the patient died during this period due to sepsis after subsequent pneumococcal infection.

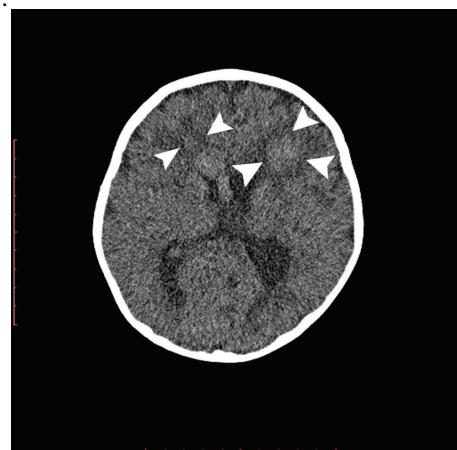


Figure 1. Brain CT showed peripherally hypodense lesions (arrowheads)

Cutaneous forms of JXG without extra systemic involvement are a benign clinical entity, generally followed with monitoring and usually regressing spontaneously (3-7). In extra-systemic involvement, many organs are affected, primarily the eyes. In addition to being isolated, CNS involvement can also present simultaneously with skin lesions (4). However, the literature reports no cases

Received: 21.05.2020 Accepted: 17.06.2020 Available online: 25.06.2021

Corresponding Author: Tumay Bekci, Department of Radiology, Faculty of Medicine, Giresun University, Giresun, Turkey

E-mail: tmybkc@gmail.com

in which a patient developed cutaneous lesions after detection of CNS lesions. CNS lesions may present alone or with multiplicity and are seen between 5 months to 5 years of age, unlike the cutaneous form which is diagnosed in the first year of life or can be congenital (1).

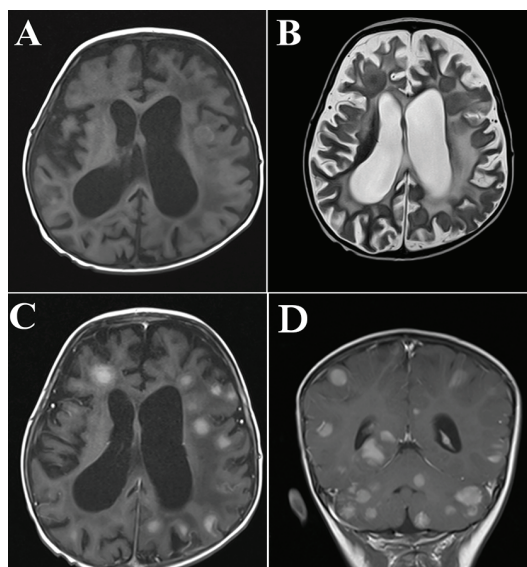


Figure 2. Brain MRI demonstrated peripheral hyperintense, central isointense lesions on T1-weighted MRI images (A) and peripheral hypointense, central hyperintense lesions on T2-weighted MRI images (B) with surrounding vasogenic edema in the white matter. Lesions showed well-contrast enhancement on axial (C) and coronal images (D) following intravenous contrast media administration

The most frequent symptoms associated with CNS involvement are seizures and focal CNS deficits (2). Patients who referred with complaints of Parinaud's syndrome, left facial palsy, significant memory loss, and pollakiuria have been reported in the literature (2). In our report, the patient was referred to our hospital with an initial clinical presentation of seizure. During etiological investigation, multiple CNS lesions were found via MRI. In the sixth month after initial diagnosis, lesions were found on hairy skin; this characteristic makes our study a first in the literature.

Reported areas of CNS involvement of JXG include ventricular, sellar, cerebellopontine angle, intraparenchyma, dural-cortical interface and skull base (4). With multiple lesions, there may be difficulty in the definitive diagnosis with other possibilities including meningioma, xanthoastrocytoma, schwannomas, ependymomas, ganglioglioma, glioma, sarcoidosis, lymphoma, and tuberculosis granulomas (4). Infectious agents may be excluded with specific laboratory tests. In this case report, we excluded infectious reasons with specific laboratory tests. However, brain neoplasms don't have specific markers. Here, recognizing the imaging findings of JXG plays a significant role in definitive diagnosis. Lesions are isointense in T1W MRI images and, following contrast administration, are well-enhanced. Peripheral vasogenic brain edema generally accompanies the lesions.

Our patient had multiple isointense lesions on T1W images with peripheral edema and well-enhancement following contrast media administration (4). Lesions showed restricted diffusion on DWI. Although the literature reports similar imaging results existing in JXG patients, there is great overlap with imaging findings of other diseases, therefore definitive diagnosis requires biopsy (3,4). For reachable and solitary intracranial lesions, surgery is the first step in treatment of CNS lesions of JXG; with full resection, reported prognosis is favorable (3). However, for lesions that cannot be fully resected, and lesions that are multifocal, progressive or surgically unreachable, adjuvant therapy including steroids and chemotherapy is needed (3). Therapy for our patient began with Vinblastine due to multiple lesions. Unfortunately, our patient died on the sixth month due to fatal coursing of the disease.

CNS involvement of JXG is a rare clinical entity with poor outcome. Timely diagnosis and management are crucial. For clinicians and radiologists, knowledge about CNS involvement imaging features and clinical presentations of JXG is essential.

REFERENCES

1. Ladha MA, Haber RM Giant Juvenile Xanthogranuloma: Case Report, Literature Review, and Algorithm for Classification. *J Cutan Med Surg* 2018;22:488-94.
2. Wang B, Jin H, Zhao Y et al. The clinical diagnosis and management options for intracranial juvenile xanthogranuloma in children: based on four cases and another 39 patients in the literature. *Acta Neurochir* 2016;158:1289-97.
3. Su J, Chen N, Yue Q et al. Multimodal MRI features of an intracranial juvenile Xanthogranuloma. *Childs Nerv Syst* 2019;35:871-74.
4. Pérez PT, Zabala AB, Guezala MA et al. Intracerebral juvenile xanthogranuloma: an infrequent involvement of hystiocytosis in children. *Childs Nerv Syst* 2018;34:1445-6.
5. Meshkini A, Shahzadi S, Zali A et al. Systemic juvenile xanthogranuloma with multiple central nervous system lesions. *J Cancer Res Ther* 2012;8:311.
6. Pagura L, de Prada I, López-Pino MA, et al. Isolated intracranial juvenile xanthogranuloma. A report of two cases and review of the literature. *Childs Nerv Syst* 2015;31:493-8.
7. Ferguson SD, Waguespack SG, Langford LA, et al. Fatal juvenile xanthogranuloma presenting as a sellar lesion: case report and literature review. *Childs Nerv Syst* 2015;31:777-84.