

# Controlled ovarian hyperstimulation with gonadotropins for Clomiphene Citrate resistant Polycystic ovary syndrome leads to a higher risk of ovarian hyperstimulation syndrome

 Serhat Ege

Department of Gynecology and Obstetrics, Science Healty University, Gazi Yasargil Training and Research Hospital, Diyarbakir, Turkey

Copyright@Author(s) - Available online at [www.annalsmedres.org](http://www.annalsmedres.org)

Content of this journal is licensed under a Creative Commons Attribution-NonCommercial 4.0 International License.



## Abstract

Ovarian hyperstimulation syndrome (OHSS) caused by controlled ovarian hyperstimulation, although usually regressing spontaneously, may occasionally occur with clomiphene citrate, typically with gonadotropin, which sometimes results in serious complications. 25-year-old patient was followed up in our hospital due to OHSS. Since our patient was Clomiphene Citrate (CC) resistant Polycystic ovary syndrome (PCOS), follitropin alpha was started. Firstly, treatment started from 75 IU rFSH. Increased to 150 IU on day 15, if no improvement in the ovaries. Due to the development of two 18 mm follicles on the 21<sup>st</sup> day and the E<sub>2</sub> value being 773 pg/mL, human chorionic gonadotropin (hCG) was applied and insemination was performed. Patients with CC resistant PCOS represent a challenge for reproductive medicine. We propose a calculated low-dose stimulation strategy with step-up according to ovarian response in gonadotropins protocols. If the treatment period is extended and the dose is increased; Even if the follow-up values are normal, the patient should be closely monitored to avoid OHSS.

**Keywords:** Clomiphene citrate resistance; infertility; OHSS; PCOS

## INTRODUCTION

Polycystic ovary syndrome (PCOS) is a heterogeneous, multifactorial disease affecting 10% of the female population of reproductive age. The main features of PCOS include ovulatory dysfunction, hyperandrogenism, and polycystic ovary images in ultrasonography (1,2). Clomiphene Citrate (CC) resistance, which is seen in about 15 to 40% of women with PCOS, is defined as ovulation failure after taking 150 mg CC daily for five days per cycle for at least three cycles (3). Patients who received 150 mg CC during three cycles and had ovulation insufficiency were included in this study.

Ovarian hyperstimulation syndrome (OHSS) is the most serious complication of controlled ovarian hyperstimulation. OHSS is cystic enlargement of the ovaries and a fluid shift from the intravascular space to the third space due to increased capillary permeability. Its occurrence is dependent on the administration of human chorionic gonadotropin (hCG) after an exaggerated ovarian response to gonadotropin stimulation.

The syndrome is relatively common, occurring in up to 5% of women undergoing in vitro fertilization or intrauterine insemination (IUI) procedures (4).

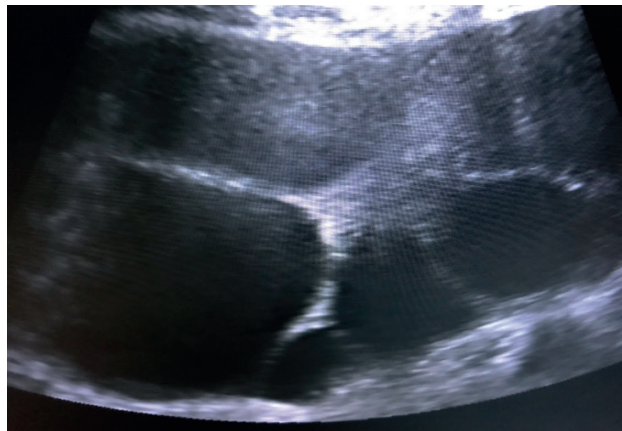
## CASE REPORT

Twenty five year-old patient was followed up in our hospital due to OHSS. Since our patient was CC resistant PCOS, follitropin alpha was started. Firstly, treatment started from 75 IU rFSH (Gonal-F 900 pen, Serono, Geneva, Switzerland) Upon no development in ovaries, it was increased to 150 IU on the 15<sup>th</sup> day. Due to the development of two 18 mm follicles on the 21<sup>st</sup> day and the E<sub>2</sub> value being 773 pg/mL, hCG (Ovitrelle, single-dose, subcutaneous) was applied and insemination was performed. The patient's weight was 85 kg and height was 163 cm, blood pressure 100/60 mmHg, pulse rate 100 beats/min,  $\beta$ -hCG 24778 IU/L, (CRL 6 W ) hemoconcentration of 39.8 %, hemoglobin of 13.6 g/dL, leucocytosis of  $10 \times 10^3/\mu\text{L}$ . The patient showed a medium and late form of OHSS (revealed bilaterally enlarged multicystic ovaries and amount of ascites (Figure 1).

**Received:** 30.04.2020 **Accepted:** 08.06.2020 **Available online:** 25.06.2021

**Corresponding Author:** Department of Gynecology and Obstetrics, Science Healty University, Gazi Yasargil Training and Research Hospital, Diyarbakir, Turkey **E-mail:** [serhatege782@gmail.com](mailto:serhatege782@gmail.com)

Immediately after admission, infusion therapy was started, consisting of normal saline-infusion 0.9% 1000 ml (Pharmacia) and low-molecular weight heparin 5000 IU 2 × 1 per day. Patient stayed at hospital three days. Body weight, abdominal circumference, intake and outputs, ultrasonography, and laboratory studies were monitored strictly daily. Renal function was not disturbed and there were no serious changes in serum electrolytes.



**Figure 1.** Ultrasonographic examination revealed bilaterally enlarged multicystic ovaries

## DISCUSSION

Patients with PCOS constitute the most difficult population in the management of infertility. The factors that increase the success rates in the treatment of PCOS infertility are: pretreatment changes in life style, dietetic and psychological support, a detailed evaluation of the couple and the appropriate selection of the treatment protocol, a wide-spectrum approach to maintaining ovarian and endometrial synchronization in the management of the cycle, and well-developed laboratory conditions to support embryonic quality (5). Despite close monitoring during ovarian stimulation and rigid guidelines and criteria for canceling cycles, OHSS still occurs. Clinical manifestations of OHSS can be classified into three forms. In mild forms of OHSS the ovaries are enlarged, while in moderate forms there is additional accumulation of ascites with mild abdominal distension. Its severe form in ~0.5% of stimulated cycles (6) is characterized by hemoconcentration, thrombosis, oliguria, pleural effusion, rarely pericardial effusion, and respiratory distress (7).

OHSS caused by controlled ovarian hyperstimulation, although usually regressing spontaneously, may occasionally occur with clomiphene citrate, typically with gonadotropin, which sometimes results in serious complications (8). The frequency of OHSS increases with hCG. The symptoms are more severe and continue longer if pregnancy is successful. Pregnant patients continue the ovarian luteinization process with hCG production. Although the pathophysiology of this syndrome is not fully known, the underlying mechanism responsible for the clinical manifestations of OHSS appears to be an increase in capillary permeability of mesothelial surfaces (9). Some vasoactive substances such as vascular endothelial

growth factor (VEGF), cytokines (IL-2, IL-6 and IL-8), tumor necrosis factor-alpha (TNF-alpha) and ovarian renin are thought to increase, gonadotropin-activated angiotensin system, It can lead to increased vascular permeability and extravascular fluid accumulation in OHSS (10,11).

Failure of CC to induce ovulation or CC resistance is unpredicted- able and foremost unexplain able event. Some studies have shown that it is more prevalent in obese, insulin-resistant, and hyperandrogenic patients; a genetic predisposition has been mentioned (12).

Controlled ovarian hyperstimulation with gonadotropins for artificial reproductive techniques leads to a higher risk of OHSS for patients affected by PCOS, because of a higher sensibility and exaggerated response to gonadotropins (13). Physicians can reduce the risk of OHSS by monitoring FSH therapy to use this medication cautiously, and by withholding hCG medication (14). Another study Gülerman et al. showed that, administration of GnRH antagonist and coasting in women at high risk of developing OHSS were equally effective in preventing OHSS (15). In this study, an antagonist was not given prophylactically.

## CONCLUSION

The starting dose of gonadotropins was individually calculated depending on patients' age, Body mass index, ovarian reserve, ovarian response in previous cycles, and diagnostic criteria of PCOS. Therefore, it is important to give recommendations for the dosage and the preferred stimulation-protocol to avoid OHSS. In this study, although the E<sub>2</sub> values were normal and only 2 mature follicles developed, OHSS occurred with pregnancy. When using gonadotropins in CC resistant PCOS patients, there is no such thing as preventing the risk of OHSS completely. The important thing is to identify patients at risk with well-known approaches. In CC resistant PCOS patients, prolonging the treatment process and increasing the dose further increases the possibility of OHSS. Even if the follow-up values are normal, the patient should be closely monitored to avoid OHSS.

*Conflict of interest: The authors declare that they have no competing interest.*

*Financial Disclosure: There are no financial supports.*

## REFERENCES

1. Azziz R, Woods K, Reyna R, et al. The prevalence and features of the polycystic ovary syndrome in an unselected population. *J Clin Endocrinol Metab* 2004;89:2745-9.
2. Bednarska S, Siejka A. The pathogenesis and treatment of polycystic ovary syndrome: What's new? *Adv Clin Exp Med* 2017;26:359-67.
3. Brown J, Farquhar C, Beck J, et al. Oral anti-oestrogens and medical adjuncts for subfertility associated with anovulation. *Cochrane Database Syst Rev* 2005;1:CD002249.

4. Neulen J, Yan Z, Raczek S, et al. Human chorionic gonadotropin-dependent expression of vascular endothelial growth factor/vascular permeability factor in human granulosa cells: importance in ovarian hyperstimulation syndrome. *J Clin Endocrinol Metab* 1995;80:1967-7.
5. Kalem M, Kalem Z, & Gurgan T. Problems and Complications During the Treatment of Infertility in Women with Polycystic Ovary Syndrome. *Gynecol Obstet Reprod Med* 2016;22:113-24.
6. Navot D, Bergh PA, Laufer N. Ovarian hyperstimulation syndrome in novel reproduction technologies: prevention and treatment. *Fertil Steril* 1992;58:249-61.
7. Bergh PA, Navot D. Ovarian hyperstimulation syndrome: A review of pathophysiology. *J Assist Reprod Genet* 1992;9:429-38.
8. Whelan JG, 3rd, Vlahos NF. The ovarian hyperstimulation syndrome. *Fertil Steril* 2000;73:883-96.
9. Polishuk WZ, Schenker JG. Ovarian overstimulation syndrome. *Fertil Steril* 1969;20:443-50.
10. Rizk B, Aboulghar M, Smitz J, et al. The role of vascular endothelial growth factor and interleukins in the pathogenesis of severe ovarian hyperstimulation syndrome. *Hum Reprod Update* 1997;3:255-66.
11. Delbaere A, Bergmann PJM, Gervy-Decoster C, et al. Prorenin and active renin concentrations in plasma and ascites during severe ovarian hyperstimulation syndrome. *Hum Reprod* 1997;12:236-40.
12. Abd Elgafor I. Efficacy of combined metformin-letrozole in comparison with bilateral ovarian drilling in clomiphene-resistant infertile women with polycystic ovarian syndrome. *Arch Gynecol Obstet* 2013;288:119-23.
13. Cupisti S. Komplikation bei Ovulations induktion. Das ovarielle Überstimulationssyndrom. *Geburtshilfe Frauenheilkd* 2012;72:798-801
14. Yildizhan R, Adali E, Kulusari A, et al. Ovarian Hyperstimulation Syndrome with pleural effusion: A case report. *Cases J* 2008;1:323
15. Gulerman C, Yilmaz, N, Sargin Oruc, et al. Coasting Versus GnRH Antagonist Salvage for the Prevention of Ovarian Hyperstimulation Syndrome. *Gynecol Obstet Reprod Med* 2016;19:176-9.