

# Kaposi's Sarcoma After Liver Transplantation from a Donor with a History of Ventriculoperitoneal Shunt and Craniotomy for Primary Central Nervous System Lymphoma: Report of a Case

BURAK ISIK<sup>1</sup>, SEZAI YILMAZ<sup>1</sup>, VEDAT KIRIMLIOGLU<sup>1</sup>, HALE KIRIMLIOGLU<sup>2</sup>, MEHMET YILMAZ<sup>1</sup>, GOKHAN SOGUTLU<sup>1</sup>, CENGİZ ARA<sup>1</sup>, and DANIEL KATZ<sup>3</sup>

Departments of <sup>1</sup>Surgery and <sup>2</sup>Pathology, Inonu University Medical School, Genel Cerrahi AD, Malatya 44280, Turkey

<sup>3</sup>Department of Surgery, University of Iowa Hospitals and Clinics, Iowa City, IA, USA

## Abstract

The transplantation of organs from donors who have undergone shunt surgery or craniotomy for a malignant central nervous system (CNS) tumor is controversial. We report a case of Kaposi's sarcoma (KS) developing as a result of immunosuppression in the recipient of a liver transplant from a donor who underwent craniotomy and ventriculoperitoneal shunt surgery for primary CNS lymphoma. Polymerase chain reaction assay did not isolate human herpes virus-8 in the Kaposi lesions. To our knowledge, this is the only case ever reported of KS developing after liver transplantation from a donor with lymphoma. Thus, with appropriate screening to exclude possible dissemination, patients with a history of high-grade primary CNS lymphoma treated by ventriculoperitoneal shunt and craniotomy may be accepted as donors.

**Key words** Donor · Kaposi's sarcoma · Lymphoma

## Introduction

The critical shortage of donor organs has led to the retrieval of organs from expanded or marginal donors such as those with malignant central nervous system (CNS) tumors. Malignant CNS tumors are rare and not absolute contraindications for organ donation. However, according to the recent European guidelines, patients with primary CNS lymphomas or other high-grade malignant CNS tumors should not be considered for organ donation.<sup>1</sup>

It has also been suggested that there would be an increasing risk of transmission of the malignancy if either craniotomy or shunt surgery were performed.<sup>2</sup> Because there are so few reports on the transmission of malignancy to recipients after the transplantation of organs from such donors, the subject is controversial.<sup>3–7</sup>

Kaposi's sarcoma (KS) is one of the most frequent malignant tumors arising de novo in immunodepressed patients.<sup>8</sup> Extrahepatic KS has been reported in 2.8% of hepatic transplant recipients,<sup>9</sup> and tends to be cutaneous in a solid organ transplant setting.<sup>9,10</sup> An association between KS and lymphoma has also been reported in transplant patients.<sup>10,11</sup> However, we were unable to find any report of KS in the recipient of a transplant from a donor with CNS lymphoma.

We report a case of KS arising as a result of immunosuppression in the recipient of a liver transplant from a donor with primary CNS lymphoma. We also discuss the suitability of organs from donors with CNS malignancies in an effort to help transplant surgeons decide whether to accept or refuse such organs.

## Case Report


The donor was a 62-year-old woman admitted for the investigation of severe headaches and deteriorating mental status. Cranial computed tomography (CT) scan showed hydrocephalus and a contrast-enhancing intracranial mass in the posterior fossa. She underwent an emergency ventriculoperitoneal shunt, followed 13 days later by a craniotomy and partial resection of the tumor. Histologically, the tumor was diagnosed as a high-grade, large-B cell lymphoma. Postoperatively, the patient's neurological state deteriorated to brain death. CT scans of the chest, abdomen, and pelvis, performed to detect possible metastasis of the CNS lymphoma in the potential donor, were normal. The family consented for organ

Reprint requests to: S. Yilmaz

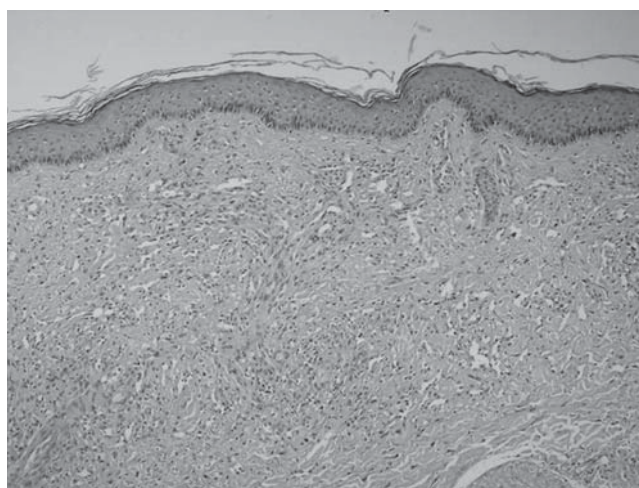
Received: January 8, 2007 / Accepted: March 29, 2007

donation and the patient was taken to the operating room for organ retrieval. Laparotomy revealed normal intraabdominal findings, including the liver, both kidneys, spleen, peritoneum, and lymph nodes. The pathological findings of the lungs and mediastinum were also normal. Intraoperative ultrasonography of the liver and both kidneys showed no abnormality, and frozen sections of the liver and cytological examination of the peritoneal fluid demonstrated no pathological findings. On the basis of these findings and the results of preoperative laboratory examinations, including peripheral complete blood count, chest X-ray, and CT scan of the chest, abdomen, and pelvis, we considered the tumor to be a primary CNS lymphoma. Thus, her liver and both kidneys were retrieved for transplantation.

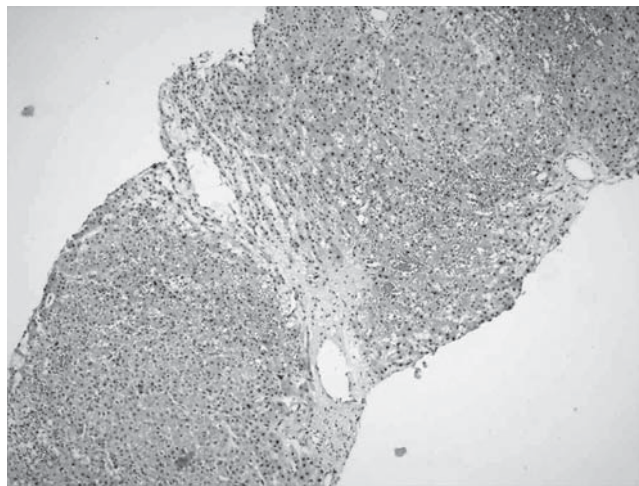
The recipient was a 48-year-old man who underwent orthotopic liver transplantation (OLT) for decompensated chronic liver disease secondary to hepatitis B infection. Before the OLT, the patient was seropositive (immunoglobulin G) for Epstein–Barr virus, cytomegalovirus, and herpes simplex virus, and seronegative for human immunodeficiency virus. The immunosuppressive regimen consisted of tacrolimus and prednisolone, and hepatitis B immunoglobulin and lamivudine were given as prophylaxis against hepatitis B virus infection. The patient presented 22 months after the OLT with cutaneous lesions in the neck, both legs, back, and abdomen, suggestive of KS (Fig. 1). A skin biopsy confirmed this diagnosis (Fig. 2). Human herpesvirus 8 (HHV-8) was not isolated from the Kaposi lesions by polymerase chain reaction assay. We ruled out the presence of visceral lesions anywhere in the body by conducting a thorough work-up. The tacrolimus was progressively decreased and finally withdrawn, following which, the liver graft function deteriorated. The patient suffered two attacks of acute cellular rejection, confirmed by biopsies, during the next 4 months. To manage each of these attacks, steroid pulse therapy was given, starting with a loading dosage of 5 mg orally, followed by a maintenance dosage of 2–3 mg/day. The sirolimus target blood level was 10–20 ng/ml initially, and then 5–10 ng/ml after 3 months. We also treated the patient with concomitant ganciclovir therapy. During the next 4 months, the lesions persisted, but they did not multiply or grow. However, 26 months after the OLT, a physical examination revealed leg edema, ascites, pleural effusion, a weight gain of 6 kg, and jaundice. A liver biopsy revealed mild sinusoidal congestion around the central vein. A second biopsy, done 2 weeks later, showed mild perivenular hepatocyte atrophy and fibrosis with centrilobular hemorrhagic necrosis (Fig. 3). Histological examination revealed venous outflow obstruction, although venography showed a patent inferior vena cava and hepatic veins (Fig. 4). The subsequent clinical course, including graft failure, seemed to



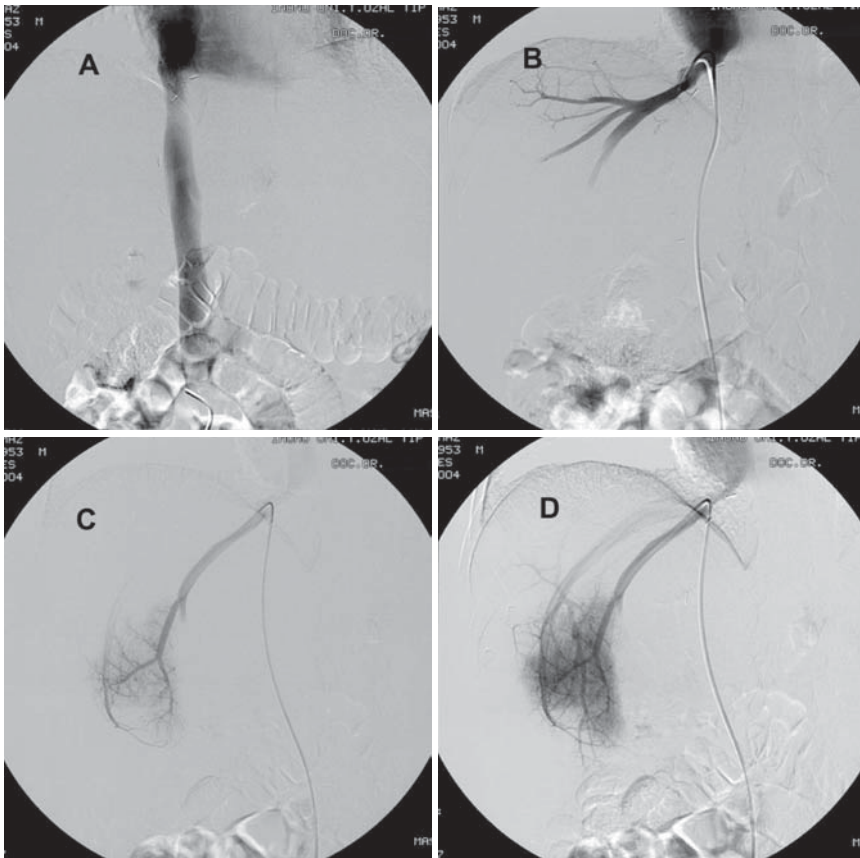
**Fig. 1.** Initial cutaneous lesions of Kaposi's sarcoma



**Fig. 2.** Histopathological appearance of the cutaneous lesions of Kaposi's sarcoma



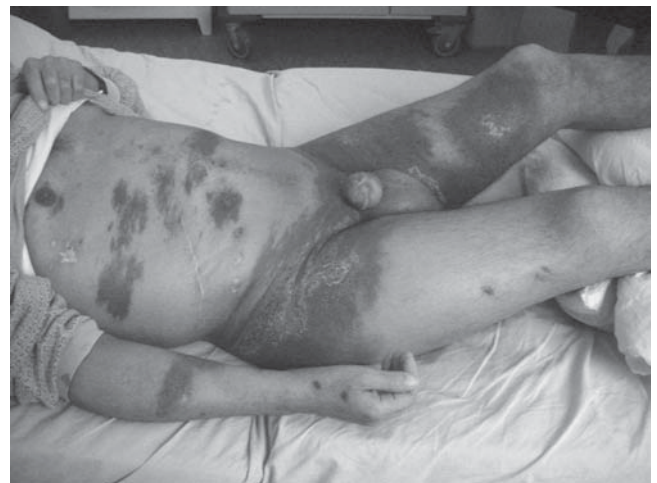**Fig. 3.** Histological findings of centrilobular hemorrhagic necrosis and mild pericentral fibrosis



**Fig. 4.** Venography confirmed patency of the inferior vena cava (A), and right (B, C) and middle (D) hepatic veins

be related to the rejection process that occurred after the reduction in immunosuppression therapy to combat the KS. We gave the patient diuretic treatment consisting of furosemide 120mg and spironolactone 100mg daily, but there was no weight loss or decrease in ascites, which required frequent paracentesis. The serum bilirubin level increased to 19.4mg/dl and the patient became comatose with poor coagulation function. An urgent re-OLT was performed 28 months after the original OLT and the patient recovered uneventfully. The histological examination of the explanted liver revealed sub-massive parenchymal necrosis and hemorrhagic areas, but no KS lesions.

The immunosuppressive regimen after the second OLT consisted of sirolimus, mycophenolate mofetil, and prednisolone; however, within 11 months, the cutaneous lesions had begun to grow and multiply again (Fig. 5). Immunosuppressant therapy was subsequently stopped and a thorough workup again ruled out the presence of visceral lesions. His clinical condition progressively deteriorated and he died of multiple organ failure in the intensive care unit, 12 months after re-OLT. His family refused to consent for an autopsy.



**Fig. 5.** The cutaneous lesions of Kaposi's sarcoma grew progressively and multiplied

## Discussion

Donors with a malignant CNS tumor account for 1%–4% of the organ donor pool.<sup>3,4,7,12</sup> Despite the consensus that these organs should not be transplanted because of

the risk of cancer transmission,<sup>5,13,14</sup> the incidence of donor-related tumors is in fact extremely low.<sup>3-7</sup> The donor-related tumor death rate is also low, particularly when compared with the waiting-list mortality,<sup>15</sup> which would be increased further by the exclusion of donors with a malignant CNS tumor. Guidelines for the use of organs from donors with malignant CNS tumors were prepared recently in Europe on the basis of the Cincinnati Transplant Tumor Registry.<sup>1,16</sup> These guidelines advise that organs from donors with a high-grade malignant CNS tumor, including primary lymphoma, should not be used, and that organs from donors with a low-grade malignant CNS tumor should be used only in very special or emergency situations. However, the Cincinnati Transplant Tumor Registry itself recognized a bias in its recruitment and acknowledged that the number of malignant CNS tumors actually transmitted is extremely small.<sup>4</sup> Moreover, there is insufficient information and experience of organ transplants from donors with primary CNS lymphoma. The guidelines also did not take into account the donor organ shortage and deaths on the waiting list. Recent data show no differences in survival rates between recipients of organs from donors with cancer and recipients of organs from donors without cancer.<sup>17</sup> Although malignant CNS tumors were once thought not to metastasize outside the CNS, it is now established that they occasionally do; at an estimated incidence of 0.4%–2.3%.<sup>18,19</sup> Moreover, this incidence seems to be increasing with improved treatment strategies and prolonged patient survival.

The risk of transmission of malignancy may be increased if craniotomy or shunt surgery has been performed for the following reasons: A major craniotomy opens up direct, vascular, and lymphatic pathways for extracranial spread, whereas internal shunting procedures provide a route for tumor dissemination. Major surgery and shunts allow cancer cells to access areas outside the CNS, and the extended survival of some patients treated effectively by aggressive multimodality therapy may allow these cells to become clinically evident. Overt spread via the shunt has been reported to occur 5 months to 3 years after shunt placement.<sup>2,3</sup> However, we do not know the incidence of microscopic spread via shunts and not all shunts transmit malignant cells. If the neoplasm is not in communication with the cerebrospinal fluid, malignant cells will not spread along the shunt. Cases of successful transplantation of abdominal organs from donors with a ventriculoperitoneal shunt or a history of craniotomy have been reported.<sup>20</sup> The pattern, timing, and incidence of spread appear to be the same, with or without a shunt.<sup>12</sup> The safe interval from the time of CNS lymphoma diagnosis and intervention until the time of organ procurement is as yet undefined; however, on the basis of this case, we suggest within 2 weeks.

Systemic dissemination of primary CNS lymphoma is rare, even if the disease is in an advanced stage, because the CNS is an immunological sanctuary. Neoplastic lymphocytes may be eradicated systemically by an intact immune system, but they find relative protection within the CNS. The strikingly high incidence of primary CNS lymphoma in patients with acquired immunodeficiency syndrome (AIDS), and others receiving immunosuppressant therapy, warrants serious investigation because these patients are not candidates for organ donation. Conversely, patients with an intact immune system may be considered for organ donation because it is unlikely that neoplastic lymphocytes would be present in their systemic circulation.

Our patient's clinical course was complicated by the development of KS after an OLT from a donor with lymphoma. Interestingly, in the general population, as many as 37% of patients with KS have other primary malignancies, particularly lymphomas.<sup>21</sup> According to one report, 26% of AIDS patients with non-Hodgkin's lymphoma also had KS.<sup>22</sup> An association of tumors was also reported in transplant patients.<sup>10,11</sup> In the Cincinnati Transplant Tumor Registry, 8 of 356 patients with KS also had lymphomas.<sup>23</sup> To the best of our knowledge, the development of KS after OLT from a donor with lymphoma has never been reported before. HHV-8, also known as KS-associated herpes virus, has been associated with all forms of KS.<sup>24</sup> The overall HHV-8 seroprevalence in liver-transplant recipients and donors was reported to be 2.5% and 3.3%, respectively.<sup>25</sup> However, we did not detect HHV-8 in the Kaposi lesions on our patient. Several different treatments for KS have been proposed. One of the main approaches for transplant-related KS is to reduce or discontinue immunosuppression therapy, which is usually associated with regression of the lesions. However, this approach is of course difficult for liver transplant recipients for whom graft loss resulting from a reduction in immunosuppression would mean death unless retransplantation was performed.<sup>23,26</sup> Our patient survived for another 14 months after conversion from tacrolimus to sirolimus and ganciclovir therapy, but then experienced the same scenario. Different treatments for KS together with reduction in immunosuppression have been proposed, including radiation therapy or chemotherapy.<sup>27</sup>

Recipients of grafts harvested from donors with malignant CNS tumors must be followed up closely for 2 years after transplantation. Donor-related malignancy in the recipient of an organ from donors with malignant CNS tumors after 17 months of follow-up has never been described.<sup>4,16</sup> The danger of inadvertently transmitting tumors from donor to recipient needs to be viewed in perspective: compared with the benefits of organ transplantation, the risk of malignancy transmis-

sion seems low. In most reported cases the risks were not appraised adequately and it is likely that appropriate predonor evaluation was not done. With appropriate screening for possible lymphoma dissemination, patients with high-grade primary CNS lymphoma and a history of ventriculoperitoneal shunt and craniotomy may be accepted as donors.

*Acknowledgments.* We thank Professors Yaman Tokat and Alper Demirbas for their critical review and helpful suggestions.

## References

1. Select Committee of Experts on the Organisational Aspects of Cooperation in Organ Transplantation. Council of Europe. International Consensus Document. Standardization of organ donor screening to prevent transmission of neoplastic diseases. *Transplant Newsl* 1997;2:4.
2. Fecteau AH, Penn I, Hanto DW. Peritoneal metastasis of intracranial glioblastoma via a ventriculoperitoneal shunt preventing organ retrieval: case report and review of the literature. *Clin Transplant* 1998;12:348–50.
3. Chui AK, Herberth K, Wang LS, Kyd G, Hodgeman G, Verran DJ, et al. Risk of tumor transmission in transplantation from donors with primary brain tumors: an Australian and New Zealand registry report. *Transplant Proc* 1999;31:1266–7.
4. Detry O, Honoré P, Hans MF, Delbouille MH, Jacquet N, Meurisse M. Organ donors with primary central nervous system tumor. *Transplantation* 2000;70:244–8.
5. Frank S, Muller J, Bonk C, Haroske G, Shackert HK, Shackert G. Transmission of glioblastoma multiforme through liver transplantation. *Lancet* 1998;352:31.
6. Birkeland SA, Storm HH. Risk for tumor and other disease transmission by transplantation: a population-based study of unrecognized malignancies and other diseases in organ donors. *Transplantation* 2002;74:1409–13.
7. Healey PJ, Davis CL. Transmission of tumours by transplantation. *Lancet* 1998;352:2–3.
8. Penn I, First MR. Development and incidence of cancer following cyclosporine therapy. *Transplant Proc* 1986;18 Suppl 1:210–5.
9. Bismuth H, Samuel PY, Venancie G, Menouar G, Szekely AM. Development of Kaposi's sarcoma in liver transplant recipients: characteristics, management and outcome. *Transplant Proc* 1991; 23:1438–9.
10. Touraine JL, Garnier JL, Lefrancois N, Finaz de Villaine J, Dubernard JM, de Thé G, et al. Severe lymphoproliferative disease and Kaposi sarcoma in transplant patients. *Transplant Proc* 1989; 21:3197–8.
11. Penn I. Sarcomas in organ allograft recipients. *Transplantation* 1995;60:1485–91.
12. Colquhoun SD, Robert ME, Shaked A, Rosenthal JT, Millis TM, Farmer DG, et al. Transmission of CNS malignancy by organ transplantation. *Transplantation* 1994;57:970–4.
13. Stephens JK, Everson GT, Elliott CL, Kam I, Wachs M, Haney J, et al. Fatal transfer of malignant melanoma from multiorgan donor to four allograft recipients. *Transplantation* 2000;70: 232–6.
14. Donovan JA, Simmons FA, Esrason KT, Jamehdor M, Busuttill RW, Novak JM, et al. Donor origin of a posttransplant liver allograft malignancy identified by fluorescence in situ hybridization for the Y chromosome and DNA genotyping. *Transplantation* 1997;63:80–4.
15. Kauffman HM, McBride MA, Cherikh WS, Spain PC, Marks WH, Roza AM. Transplant tumor registry: donor related malignancy. *Transplantation* 2002;74:358–62.
16. Penn I. Donor transmitted disease: cancer. *Transplant Proc* 1991;23:2629–31.
17. Kauffman HM, McBride MA, Delmonico FL, Penn I. First report of the New International (CTTR-UNOS) Transplant Tumor Registry: US donors with a history of cancer. *Transplantation* 1999;67: S552.
18. Penn I. Questions about the use of organ donors with tumors of the central nervous system. *Transplantation* 2000;70:249–50.
19. Old SE, Burnet NG, Waite KJ. Transmission of tumours by liver transplantation. *Lancet* 1998;352:822.
20. Delhey K, Lewis R, Dunn J, Berry J, Gray R, Van Buren C, et al. Absence of tumor transmission from cadaveric renal donor with malignant astrocytoma and a ventriculoperitoneal shunt: two year recipient follow-up and review of the literature. *Transplantation* 1991;52:737–8.
21. Safai B, Diaz B, Schwartz J. Malignant neoplasms associated with human immunodeficiency virus infection. *CA Cancer J Clin* 1992;42:74–95.
22. Safai B, Mike V, Giraldo G, Beth E, Good RA. Association of Kaposi's sarcoma with second primary malignancies: possible etiopathogenic implications. *Cancer* 1980;45:1472–9.
23. Penn I. Kaposi's sarcoma in transplant recipients. *Transplantation* 1997;64:669–73.
24. Antman K, Chang Y. Kaposi's sarcoma. *N Engl J Med* 2000; 2:1027–38.
25. Marcelin AG, Dupin N, Bossi P, Calvez V. Seroprevalence of human herpesvirus-8 in healthy subjects and patients with AIDS-associated and classical Kaposi's sarcoma in France (letter). *AIDS* 1998;12:539–40.
26. Campistol JM, Gutierrez-Dalmau A, Torregrosa JV. Conversion to sirolimus: a successful treatment for posttransplantation Kaposi's sarcoma. *Transplantation* 2004;77:760–2.
27. Akay S, Karasu S, Akyildiz M, Tokat Y, Goker E. Successful treatment of liver-associated Kaposi's sarcoma with long-term vincristine. *Transplant Proc* 2005;37:2188–9.