

Acute uremia and intestinal obstruction due to a retroperitoneal hydatid cyst

Retroperitoneal kist hidatiğe baėlı akut üremi ve intestinal obstrüksiyon

Mehmet YILMAZ¹, Murat UGRAŞ², Burak IŞIK¹, Sezai YILMAZ¹, Vedat KIRIMLIOĐLU¹

Departments of ¹General Surgery and ²Urology, İnönü University, School of Medicine, Malatya

Hydatid disease should be considered in the differential diagnosis of any cystic mass in endemic areas. The symptoms due to bulk effect, usually occurring over a certain period of time, depend on the site and size of the cyst. We report an unusual presentation of retroperitoneal hydatid cyst with rapidly developing uremia and acute intestinal obstruction.

Endemik bölgelerde, kistik bir kitlenin ayırıcı tanısında kist hidatik gözönünde tutulmalıdır. Belli bir zaman diliminde gelişebilecek baskı semptomları ise kistin yerleşim yerine ve boyutuna bağlıdır. Bu olgu sunusunda retroperitoneal kist hidatiğin neden olduğu hızlı gelişen akut üremi ve intestinal obstrüksiyonu sunduk.

Key words: Hydatid cyst, intestinal obstruction

Anahtar kelimeler: Kist hidatik, intestinal obstrüksiyon

INTRODUCTION

Retroperitoneal and retrovesical localizations of hydatid cyst (HC) disease are rare even in endemic areas. The pouch of Douglas is the preferred site of development for a secondary cyst in the pelvis, initially intraperitoneal and later subperitoneal (1).

The growth of HC is usually slow and asymptomatic, and clinical manifestations are caused by compression of the involved organ (2). We present a case of retroperitoneal pelvic HC that caused bilateral ureterohydronephrosis leading to acute uremia and acute rectal obstruction. To our knowledge, this is the first report of such a clinical manifestation.

CASE REPORT

A 21-year-old male was admitted with oliguria, frequency, mild abdominal pain, constipation and rectal bleeding. A medical examination in another hospital for nausea and vomiting lasting for the last two weeks revealed acute uremia, and he was referred to our emergency ward. His medical history revealed that he was given laxatives for constipation and local therapy for hemorrhoids for

one year and that he had undergone abdominal surgery for liver HC disease with cholecystectomy four years ago.

Physical examination revealed mild abdominal tenderness and a mass in the suprapubic area on deep palpation. Digital rectal examination revealed the compression of the rectum. His white blood cell (WBC) was 11,500/ml, 8% of which were eosinophils; his BUN and creatinine were 72 mg/dl and 4.6 mg/dl, respectively. On ultrasound, he had a lower abdominal cystic mass of 15x12 cm, with septations inside. He also had bilateral hydronephrosis. Noncontrast computed tomography (CT) revealed that the pelvic mass was compressing the bladder and rectum (Figure 1). Initial diagnosis was uremia due to ureteral compression, and an emergency ureteral stenting was planned.

On cystoscopy, the surgeon was unable to reveal ureteric orifices because of bladder compression. The surgeon decided to place bilateral nephrostomies, after which the clinical condition changed significantly. At the end of the second day, a total of 4000 cc/day of urine was draining via nephros-

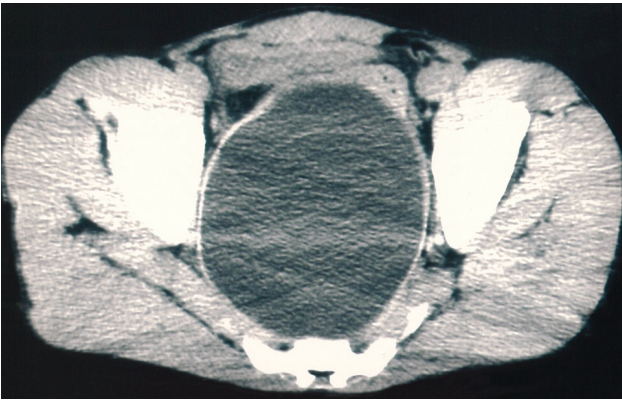


Figure 1. Non-contrast computed tomography revealing 15 cm mass of pelvic hydatid cyst. Note the compression of both the bladder and the rectum

tomies. The BUN and creatinine decreased to 26 mg/dl and 1.8 mg/dl, respectively. On clinical workup, indirect hemagglutination test for HC was positive at a titration of 1/1030. Albendazole 10 mg/kg/d was prescribed. An aspiration biopsy afterwards revealed scoleces in the cyst fluid, confirming the diagnosis of retroperitoneal HC. Fecal drainage was still a problem at the sixth day, and abdominal distension, rebound, nausea and vomiting developed subsequently. Despite nasogastric tube placement, air-gas levels developed, necessitating open surgery. On exploration, intestinal decompression was performed and 3% NaCl solution was instilled into the mass for scolicedal effect. The mass was aspirated and a partial cystectomy was performed. The collapsed laminated layer with its lining germinal layer was then removed from the pericyst, the remnant cyst was washed out with 3% NaCl and a drain was placed. No complication occurred postoperatively, and urethral urine drainage began in the recovery room. The nephrostomies were clamped and removed on the first and second postoperative days, respectively. The patient defecated on the second postoperative day. Pathological examination further confirmed HC by revealing scolices, daughter cysts and acellular eosinophilic lamellar membrane. Albendazole was continued for eight weeks postoperatively. Indirect hemagglutination test decreased to 1/124 at the fourth postoperative week. At the 11-month follow-up, there was no significant problem.

DISCUSSION

Hydatid disease is one of the oldest diseases known to mankind. The locations are mostly

hepatic (75%) and pulmonary (15%), and only 10% occur in the rest of the body (3). According to Deve (4), fissuring or rupture of a primary hepatic, splenic or mesenteric cyst would seed its contents in the abdominal cavity. Retroperitoneal HC is usually the result of spontaneous, traumatic or surgical rupture of the other organ or hepatic cysts or spillage during surgery. Primary retroperitoneal HC is extremely rare and can be considered only when no other cysts of the same etiology are present (1). El Ouakdi et al. (5) reported 31 retroperitoneal tumors, six of which were retroperitoneal HC. Angulo et al. (6) reported 10 cases during a 15-year period in an endemic zone, corresponding to 1% of newly diagnosed hydatidosis in that area. In another study, Prousalidis et al. (7) reported 49 uncommon sites of HC, and two of them were in the retroperitoneal space. The case presented here is considered to be a secondary retroperitoneal HC.

Hydatid cysts in humans produce symptoms by two mechanisms: a generalized toxic reaction due to the presence of the parasite itself and local or mechanical symptoms depending on the location of the cyst (8). The mechanical symptoms depend on the size and the number of the cysts. In more than 40% of the cases, the complications, among which rupture, secondary infection, compressive syndromes and suppuration are the most common, precede the diagnosis of the disease (5,9). In retroperitoneal HC, upper urinary tract obstruction may be present at the time of diagnosis, usually causing flank pain and less often renal insufficiency. Digestive symptoms such as constipation or development of hemorrhoids may be confounding (5,6). All of these complications are due to the mass effect of the cyst and develop over a period of time, usually without causing acute uremia or acute intestinal obstruction. The case presented here had bilateral ureteral obstruction resulting in bilateral ureterohydronephrosis and acute postrenal azotemia. In addition, the mass resulted in obstruction of the rectum, resulting in constipation and hemorrhoids initially, and acute obstructive symptoms later. Acute onset of all these symptoms gives rise to the question of how rapidly a HC can enlarge. It is known that the embryo develops into HC, reaching a diameter of 1 cm in five or so months and thereafter grows according to the stiffness of the surrounding tissue (10). In the liver, the growth rate is approximately 1-2 cm/year (11). Knowledge on the growth rate of

retroperitoneal HC is lacking, mainly because HC disease is not to be followed up but rather to be treated initially. The growth rate can be surveyed by the reports of under-evaluated or missed cases of HC.

This case was evaluated for hydatid disease and was operated for liver HC four years ago. No evidence of retroperitoneal HC was present at that time. Whether he was under-evaluated at that time for a small primary retroperitoneal cyst or had spillage of the disease due to surgery is speculative, but nevertheless, it is evident that a small or nonexistent HC became a 15 cm mass in four years. In the last year of this period there were mild symptoms of the retroperitoneal mass, and the acute onset of obstructive symptoms occurred in less than one month. To our knowledge, this is the only report of a HC case with acute onset of uremia and intestinal obstruction in such a short period of time.

Hydatid disease should be considered in the differential diagnosis of all cystic masses in all anatomical locations, especially in areas where the disease is endemic (12). The combination of

clinical history, imaging findings and serologic test results usually aid in the diagnosis (2,6,7,12,13). Aspiration biopsy may not be as risky as previously considered, and this procedure can be risk-free if performed with systemic albendazole therapy (14). In our patient, the diagnosis was made with CT and fine needle aspiration biopsy, and no complications occurred during or after the biopsy.

For treatment of retroperitoneal HD, total excision may not be possible because of dense adhesions to major vessels such as iliac vessels. The choice of surgery should be evacuation of the cyst and excision of the redundant portion of the pericyst leaving the rest of the cavity open, as in our case (7).

In conclusion, a retroperitoneal HC may develop to a diameter of 15 cm in four years. Although not usual, HC may cause acute uremia and acute intestinal obstruction with a rapid onset. HC should be considered in the differential diagnosis of retroperitoneal masses, even in acute onset of obstructive symptoms.

REFERENCES

1. Kotoulas G, Gouliamos A, Kalovidouris A, et al. Computed tomographic localization of pelvic hydatid disease. *Eur J Radiol* 1990; 11: 38-41.
2. Gossios KJ, Kontoyiannis DS, Dascalogiannaki M, et al. Uncommon locations of hydatid disease: CT appearances. *Eur Radiol* 1997; 7: 1303-8.
3. Beggs I. The radiology of hydatid disease. *Am J Roentgenol* 1985; 145: 639-48.
4. Deve F. L'echinococose secondaire. Societe d'Editions Scientifiques. Paris, 1901.
5. El Ouakdi M, Ben Fadhel S, Ayed M, Zmerli S. Isolated retroperitoneal hydatid cyst. Apropos of 4 cases. *J Urol* 1988; 94: 445-8.
6. Angulo JC, Escribano J, Diego A, et al. Isolated retrovesical and extrarenal retroperitoneal hydatidosis: clinical study of 10 cases and literature review. *J Urol* 1998; 159: 76-82.
7. Prousalidis J, Tzardinoglou K, Sgouradis L, et al. Uncommon sites of hydatid disease. *World J Surg* 1988; 22: 17-22.
8. Romero-Torres R, Campbell JR. An interpretive review of the surgical treatment of hydatid disease. *Surg Gynecol Obstet* 1965; 121: 851-64.
9. Sayek I, Yalin R, Sanac Y. Surgical treatment of hydatid disease of the liver. *Arch Surg* 1980; 115: 847-50.
10. Markell EK, Voge M, John DT. The cestodes. In: Markell EK, Voge M, John DT, eds. *Medical parasitology*. 7th ed. Philadelphia: WB Saunders, 1992; 226-60.
11. Milicevic MN. Hydatid disease. In: Blumgart LH, Fong Y, eds. *Surgery of the liver and the biliary tract*. Vol. 2. London: WB Saunders, 2000; 1167-204.
12. Engin G, Acunas B, Rozanes I, et al. Hydatid disease with unusual localization. *Eur Radiol* 2000; 10: 1904-12.
13. Angulo JC, Sanchez-Chapado M, Diego A, et al. Renal echinococcosis: clinical study of 34 cases. *J Urol* 1997; 157: 787-94.
14. Goel MC, Sharma BC, Baijal SS. Re: Hydatid disease of the kidney: evaluation and features of diagnostic procedures. *J Urol* 1994; 152: 2104.