

Muhammet G Turtay MD¹
Cemal Firat MD²
Emine Samdanci MD³
Hakan Oguzturk MD¹
Serkan Erbatır MD²
Cemil Colak MD⁴

¹ Department of Emergency Medicine,
² Department of Plastic and Reconstructive
Surgery,
³ Department of Pathology,
⁴ Department of Statistics,
Turgut Ozal Medical Center, Inonu University,
Malatya, Turkey

Effects of montelukast on burn wound healing in a rat model

Abstract

Purpose: Montelukast, a selective cysteinyl leukotriene D₄-receptor antagonist, is used in the treatment of asthma. In a rat model, our aim was to investigate the effects of montelukast, alone or in combination with topical antibiotics, on local burn wound healing.

Methods: Rats were randomly allocated to four groups after local burn development: Group 1; rats were left to secondary healing without treatment, Group 2; a dose of 10 mg/kg montelukast was given by gastric gavage once a day for 10 days, Group 3; rats were treated with topical pomade (bacitracin neomycin sulphate), and Group 4; rats were treated with a combination of topical antibiotic and montelukast (10 mg/kg were given by gastric gavage once a day for 10 days). Skin biopsies were taken on days 3, 10, 14, and 20 relative to burn induction.

Results: Reepithelialization in the pomade and montelukast+pomade groups on the 10th day was significantly greater, in comparison with control and montelukast groups ($p < 0.05$). For the montelukast group, edema (on the 14th day) and angiogenesis, fibroblast proliferation, edema and macrophage infiltration (on the 20th day) were statistically improved in comparison with the control group ($p < 0.05$). For the montelukast+pomade group, angiogenesis, fibroblast proliferation and macrophage infiltration (on the 10th day), and angiogenesis, fibroblast proliferation, edema and macrophage infiltration (on the 14th and 20th days) were statistically improved in comparison with the control group ($p < 0.05$).

Conclusion: In conclusion, montelukast was effective on burn wound healing. Moreover, the effect was amplified when combined with topical antibiotics applied in the early stage of burn wound healing.

Manuscript submitted 11th August, 2010
Manuscript accepted 3rd November, 2010

Clin Invest Med 2010; 33 (6): E413-E421.



Correspondence to:

Muhammet G. Turtay, MD, Assistant Professor
Turgut Ozal Medical Center, Inonu University School of Medicine
44280 Malatya, Turkey.
Email: mgturtay@hotmail.com

Burn wounds constitute a significant proportion of emergency service admissions. Although most epidermal burn wounds heal without intervention, severe burn wounds need medical treatment. Treatment of burn wounds aims to decrease the infection and inflammation. Topical antimicrobial agents containing bacitracin, neomycin, silver sulfadiazine and mafenide have been used clinically to eliminate infections common in local burn wounds [1]. In burn cases, inflammatory response is associated with local and systematic tissue damage and lipid peroxidation [2,3], as reflected by an increase in macrophage activity and production of pro-inflammatory mediators and even increased levels of interleukin 1 beta (IL-1 β), interleukin 6 (IL-6), tumor necrosis factor-alpha (TNF- α), tumor growth factor beta (TGF- β), leukotriene B₄ (LTB₄) and lipoxygenase metabolites [4-6]. This suggests that pro-inflammatory cascade plays a role in a number of post-burn complications [7].

Leukotrienes, produced from arachidonic acid by the enzyme 5-lipoxygenase, promotes permeability and is chemotactic. LTB₄ are important modulators of various neutrophils functions including adherence and chemotaxis [8]. Leukotriene C₄ (LTC₄), leukotriene D₄ (LTD₄), leukotriene E₄ (LTE₄) (cysteinyl leukotrienes) are released mainly by eosinophils, mast cells, monocytes, macrophages and are elevated in response to inflammation [9-11].

Montelukast is a new anti-inflammatory medicine used in the treatment of asthma. It is a potent and selective antagonist of the cysteinyl leukotriene 1 (cys-LT₁) receptor (LTD₄ receptor) and inhibits cys-LT [12]. Montelukast also prevents multiple organ dysfunction and local inflammation, and suppresses the release of proinflammatory mediators and the infiltration of neutrophils [2]. The anti-oxidant and anti-inflammatory effects of montelukast have also been used clinically to treat burn-induced gut injury [13]; however, few studies dealing with the effects of montelukast on skin burn wound healing are available. The objective of this study was to investigate the effects of montelukast, alone or in combination with topical antibiotics, on the local burn wound healing in a rat model.

Methods

Animals

A total of 32 males, Sprague-Dawley rats, weighing 300–325 g, were provided by the Experimental Animal Laboratory of Inonu University. Prior to the trial, rats were housed in sterilized polypropylene rat cages, in 12-h light-dark cycle, at an ambient temperature of 21°C. Food and drinking water were given *ad libitum*. Experiments were performed based on the

animal ethics guidelines of Institutional Animals Ethics Committee.

Experimental protocol

Four burned areas and three unburned areas adjacent to the burned areas were generated [14]. In this model, a brass comb with four 10×20 mm rectangular prongs separated by three 5 mm notches, which produces four distinctive burns sites separated by three interspaces of unburned skin, was used. All the rats were anesthetised intraperitoneally with a mixture of 80 mg/kg ketamine and 5 mg/kg xylazine. The backs of the rats were shaved, the brass comb was heated in a boiling water bath for 5 min, and then the brass comb was contacted to the shaved area of rat dorsum for 30 s without pressure. After reheating the brass comb, it was contacted to the other adjacent shaved region of the dorsum. Hence, two comb burns on either side of each rat were formed (Figure 1). All the rats were resuscitated with physiological saline solution (10 ml/kg, subcutaneously). The rats were randomly allocated to four groups of eight: Group 1, rats were left to secondary healing without treatment; Group 2, a dose of 10 mg/kg montelukast was given by gastric gavage once a day for 10 days; Group 3, rats were treated with topical antibiotic (bacitracin neomycin sulphate); and Group 4, topical antibiotic was applied and montelukast (10 mg/kg) was given by gastric gavage once a day for 10 days. Physiological saline solution was given by gastric gavage to Groups 1 and 3 to provide standardization. Healing of a burn wound was investigated through stages 1 and 2: : stage 1, inflammation phase (2-4 days); stage 2, proliferation phase (granulation tissue generation and reepithelialization, 3-20 days) [15,16]. Skin biopsies were taken on the 3rd, 10th, 14th, 20th days following

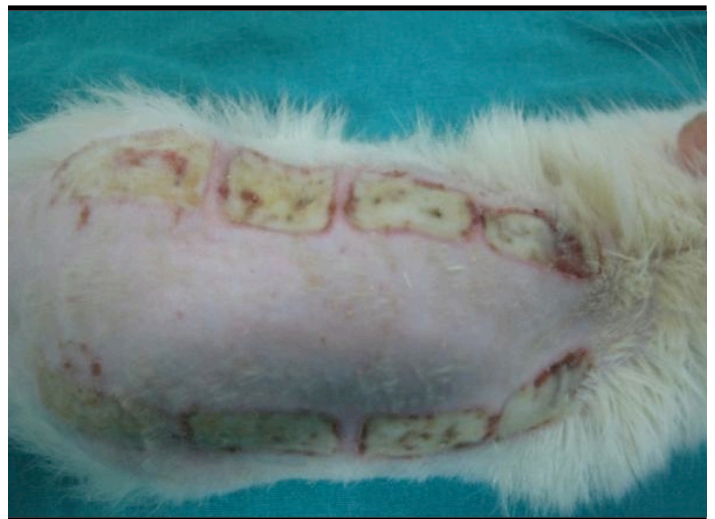

FIGURE 1. Two sided burn injury

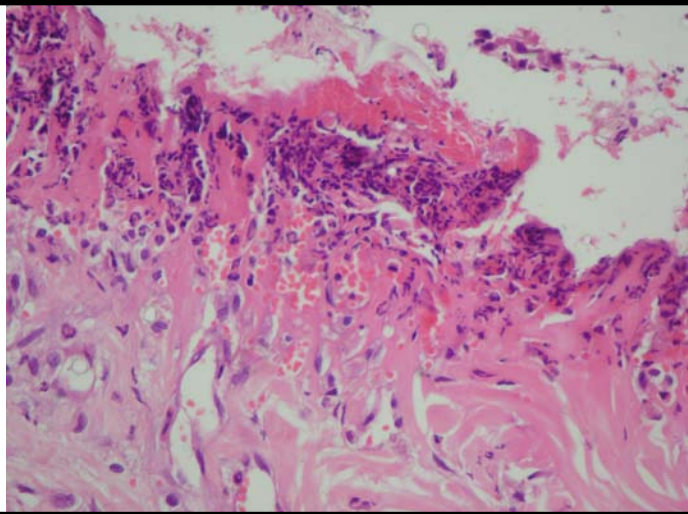


FIGURE 2. The severe neutrophil leukocytes under the separated epidermis (3rd day, group 1) H&E X400

burn development. On these days, skin biopsy specimens of the rats were taken from the same anatomical locations to include the burn wound tissue. One rat from each group died before the 20th day. All rats were sacrificed on day 20. Biopsy specimens were investigated histopathologically.

Histopathology

Biopsy samples were fixed in 10% formalin and embedded in paraffin blocks. Sections (5 μ m thick) were stained with hematoxylin-eosin (H&E) and examined using light microscopy. On the 3rd day subepithelial neutrophil were counted and on the 10th, 14th, and 20th days reepithelialization, angiogenesis, edema, fibroblast and macrophage were evaluated. Subepithelial neutrophil, angiogenesis, edema, and fibroblast and macrophage density were evaluated in accordance with the percentage of the densities in a 40X magnified dissected area of the burn region. The scoring of the parameters mentioned above was determined as absent (0) when it was between 0-10%; mild (1) when it was between 10-40 %; moderate (2) when it was between 40-70% and severe (3) when it was between 70-100%. The length of reepithelialization was evaluated in 40X magnified sections. The scoring was determined as absent (0) when reepithelialization was not present; mild (1) when reepithelialization was up to 1/3 of the burn area; moderate (2) when reepithelialization was up to 2/3; severe (3) when reepithelialization was more than 2/3. The investigator conducting histopathological examination was blinded and allocation concealment was maintained using sealed envelopes.

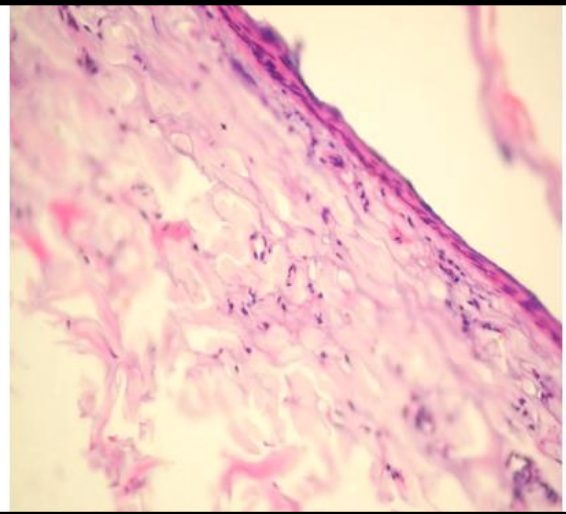


FIGURE 3. No subepidermal neutrophil infiltration (3rd day, group 4) H&E X400

Statistics

Data were expressed median. Group effects were attained by Kruskal Wallis H test (SPSS, version 15.0, for Windows, SPSS Inc., Chicago, IL). Multiple comparisons of the groups were performed by Mann Whitney U test. $P < 0.05$ was considered significant.

Results

In the epidermis, skin appendage homogeneity of the dermis confirmed the formation of burn wounds in all groups. Table 1 summarizes histopathological responses in all experimental groups over the course of 20 days. In the inflammation phase, neutrophil infiltration was severe in the control group (group 1), mild in montelukast group (group 2) and pomade group (group 3) and absent in the montelukast+ pomade group (group 4) (Figures 2 and 3). Montelukast, pomade and montelukast+pomade groups were significantly different from control group ($p < 0.05$).

In the proliferation phase, the length of reepithelialization, fibroblast proliferation, edema, angiogenesis and macrophage infiltration were evaluated. Reepithelialization in the pomade and montelukast+pomade groups on the 10th day was improved, in comparison with the control and montelukast groups ($p < 0.05$); however, reepithelialization was not observed in the control and montelukast groups. On the 14th and 20th days, montelukast, pomade and montelukast+pomade groups were significantly different from the control group ($p < 0.05$). No reepithelialization was observed in the control group until the 20th day.

TABLE 1. Comparison of histopathological variables among the four post-burn treatment groups

Time (day)	Variable	Groups				P†
		Control	Montelukst	Pomade	Montelukast+Pomade	
3	n	8	8	8	8	
	Reepithelialization	ND	ND	ND	ND	-
	angiogenesis	ND	ND	ND	ND	-
	edema	ND	ND	ND	ND	-
	fibroblast	ND	ND	ND	ND	-
	macrophage	ND	ND	ND	ND	-
	subepidermal neutrophil	3 (3-3)	1 (1-2)+	1 (1-2)+	0 (0-0)+*#	<0.001
10	n	7	8	8	8	
	Reepithelialization	0 (0-0)	0 (0-0)	1 (0-3)+*	2 (0-3)+*	0.001
	angiogenesis	2 (2-2)	2 (1-2)	1 (1-1)+*	0 (0-0)+*#	<0.001
	edema	1 (1-1)	1 (1-2)	1 (1-1)	0 (0-1)*#	0.003
	fibroblast	1 (1-2)	1 (1-2)	1 (1-1)	0 (0-1) +*#	0.003
	macrophage	1 (1-2)	2 (1-2)	1 (0-1)*	0 (0-1) +*	0.002
	subepidermal neutrophil	1 (1-1)	1 (1-1)	1 (1-1)	1 (1-2)	0.14
14	N	7	7	8	7	
	Reepithelialization	0 (0-0)	2 (1-2)+	2.5 (0-3)+	2 (2-3)+	0.005
	angiogenesis	2 (1-3)	1 (0-3)	1 (0-2)+	1 (1-1)+	0.04
	edema	2 (2-3)	1 (1-2)+	1 (1-2)+	1 (0-1)+	0.001
	fibroblast	2 (2-3)	1 (0-3)	1 (0-2)+	1 (1-1)+	0.016
	macrophage	2 (2-3)	1 (0-3)	1 (0-2)+	1 (1-1)+	0.016
	subepidermal neutrophil	ND	ND	ND	ND	-
20	n	7	7	7	7	
	Reepithelialization	0 (0-0)	2 (1-3)+	3 (2-3)+	3 (2-3)+	0.001
	angiogenesis	3 (2-3)	1 (0-2)+	1 (0-1)+	2 (1-2)+	0.001
	edema	2 (2-2)	0 (0-1)+	0 (0-1)+	0 (0-1)+	0.001
	fibroblast	3 (3-3)	1 (0-2)+	1 (1-2)+	1 (1-2)+	0.002
	macrophage	3 (3-3)	1 (1-2)+	1 (0-2)+	1 (1-2)+	0.002
subepidermal neutrophil	ND	ND	ND	ND	-	

+: p<0.05, significantly different from Control group; *: p<0.05, significantly different from Montelukast group; #: p<0.05, significantly different from Pomade group; †: Kruskal Wallis H test; Data are expressed as Median (Min-Max). ND = Not determined. Subepithelial neutrophil, angiogenesis, edema, fibroblast and macrophage density were evaluated in accordance with the percentage of the densities of 40X magnified dissected area of the burn region. The scoring of the parameters mentioned above was determined as absent (0) when it was between 0-10%; mild (1) when it was between 10-40 %; moderate (2) when it was between 40-70% and severe (3) when it was between 70-100%. The length of reepithelialization was evaluated in 40X magnified sections. The scoring was determined as absent (0) when reepithelialization was not present; mild (1) when reepithelialization was up to 1/3 of the burn area; moderate (2) when reepithelialization was up to 2/3; severe (3) when reepithelialization was more than 2/3.

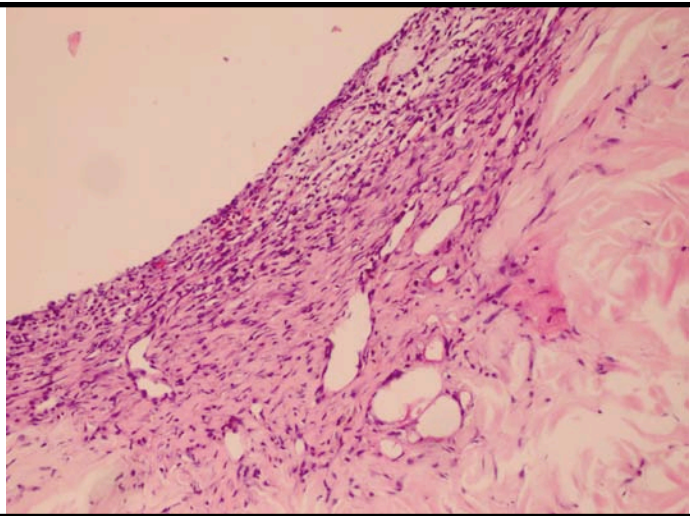


FIGURE 4. No reepithelization and the increased angiogenesis, fibroblast and macrophages (14th day, group 1) H&E X200

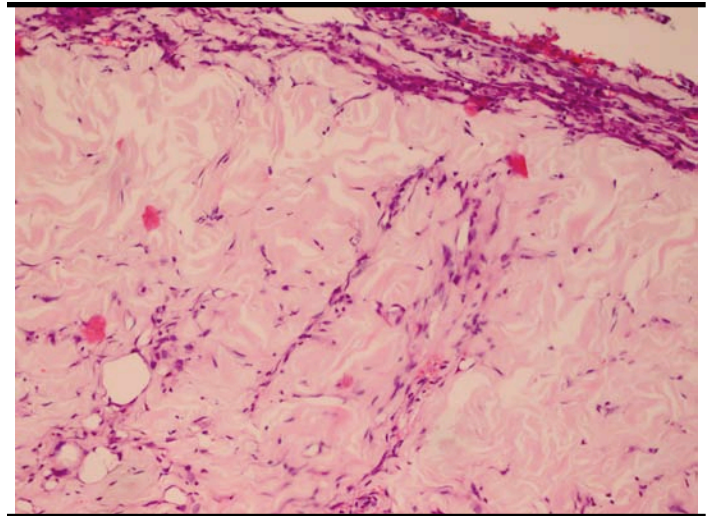


FIGURE 5. Mild level edema, angiogenesis, fibroblasts and macrophages (14th day, group 4) H&E X200

Angiogenesis in the montelukast group was lower than in the control group on the 20th day ($p < 0.05$). Angiogenesis in the pomade group was also lower than in the control group on the 10th, 14th and 20th days ($p < 0.05$). Angiogenesis in the montelukast+pomade group was lower than in the control group on the 10th, 14th and 20th days ($p < 0.05$) (Figures 4 and 5). Angiogenesis in the montelukast group was greater than in the pomade group on the 10th day ($p < 0.05$). Angiogenesis in the montelukast+pomade group was lower than in the montelukast and pomade groups on the 10th day ($p < 0.05$).

Edema in the montelukast group lower than in the control group on the 14th and 20th days ($p < 0.05$). Edema in the pomade group was also lower than in the control group on the 14th and 20th days ($p < 0.05$). Edema in the montelukast+pomade group was lower than in the control group on the 14th and 20th days ($p < 0.05$). Edema in the montelukast+pomade group was lower in the montelukast and pomade groups on the 10th day ($p < 0.05$).

Fibroblast proliferation in the montelukast group was lower than in the control group on the 20th day ($p < 0.05$). Fibroblast proliferation in the pomade group was lower than in the control group on the 14th and 20th days ($p < 0.05$). Fibroblast proliferation in the montelukast+pomade group was lower than in the control group on the 10th, 14th and 20th days ($p < 0.05$). Fibroblast proliferation in the montelukast+pomade group was lower than in the montelukast and pomade groups on the 10th day ($p < 0.05$).

Macrophage infiltration in the montelukast group was lower than in the control group on the 20th day ($p < 0.05$). Macrophage infiltration in the pomade group was lower than

in the control group on the 14th and 20th days ($p < 0.05$). Macrophage infiltration in the montelukast+pomade group was lower than in the control group on the 10th, 14th and 20th days ($p < 0.05$) (Figures 6 and 7). Macrophage infiltration in the montelukast group was lower than in the pomade group on the 10th day ($p < 0.05$). Macrophage infiltration in the montelukast+pomade group was lower than in the montelukast group on the 10th day ($p < 0.05$).

While angiogenesis, fibroblast proliferation, edema and macrophage infiltration were moderate and severe in group 1 on the 14th and 20th days (Figure 8), they were mild in group 2, group 3 and group 4 on the 14th and 20th days (Figure 9).

Figures 10-12 depict the graphics of each variable assessed over time in montelukast, pomade, montelukast+pomade groups.

Discussion

Healing of burn wounds is a complicated process that starts with the infiltration of inflammatory cell such as neutrophils, lymphocytes and macrophages. These inflammatory cells are activated by factors released in the burn process. Once activated, inflammatory cells attempt to eliminate the cause of the damage by producing mediators such as cytokines (TNF- α , IL-1, IL-6 etc) and some growth factors (fibroblast growth factor (FGF), platelet-derived growth factor (PDGF) and epidermal growth factor (EGF)). The cytokines and growth factors start regeneration of epidermis destroyed as a result of the burn, and trigger fibroblast proliferation on the damaged dermis. Other processes in burn healing are angiogenesis and generation of granulation tissue, synthesis of extracellular matrix

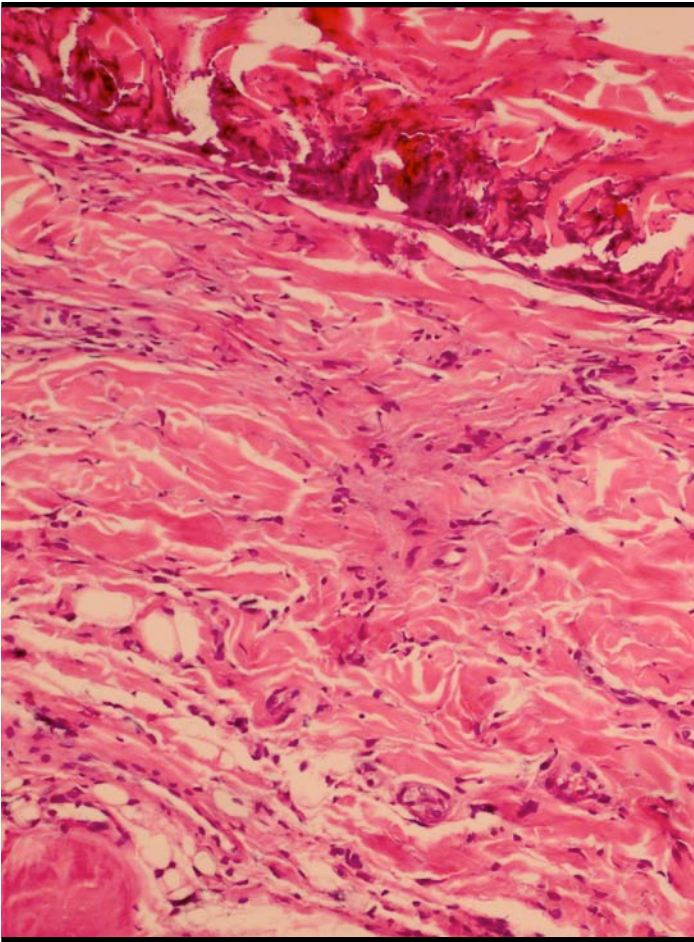


FIGURE 6. The decreased neutrophil leukocytes in superficial dermis (10th day, group1) H&E X200

proteins, storage of collagen and remodelling. The inflammatory response is required to drain damaged tissue debris. Lysosomal enzymes in neutrophils and macrophages, reactive oxygen metabolites, products of arachidonic acids metabolism like leukotrienes and prostaglandins also play roles in the inflammatory process. As these products also have the ability to cause endothelial injury and tissue damage, they may intensify the damage on the injured area [17-19].

In order to minimize the damage of the defence system, which has a capacity to cause tissue damage, anti-inflammatory lipoxin, produced from arachidonic acid, as well as TGF- β and TNF are kept under control by mechanisms that inhibit macrophage release. Anti-inflammatory drugs aim at healing by reducing inflammation [2,4,14,20-22].

Neutrophils are the primary cells of the inflammation phase and accumulate in on the damaged tissue within the first 24 hours. From the 3rd day, granulation tissue starts to form and macrophage infiltration begins. On the 5th day, neovascu-

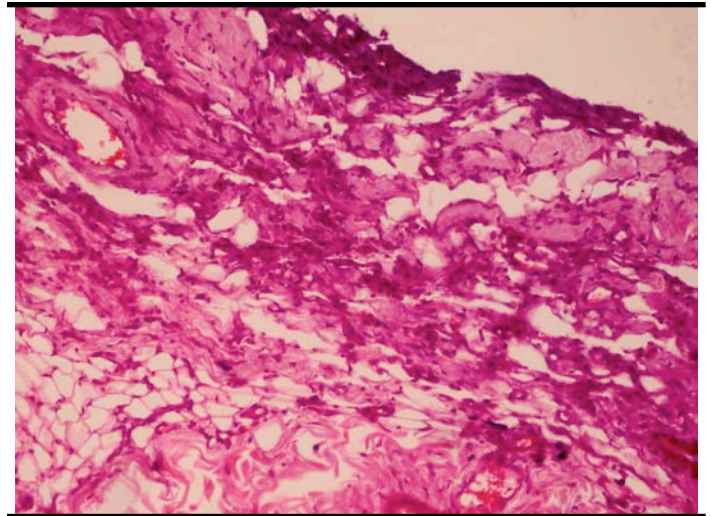


FIGURE 7. The macrophages and fibroblasts under 10%, and mild neutrophil leukocytes (10th day, group 4) H&E X200

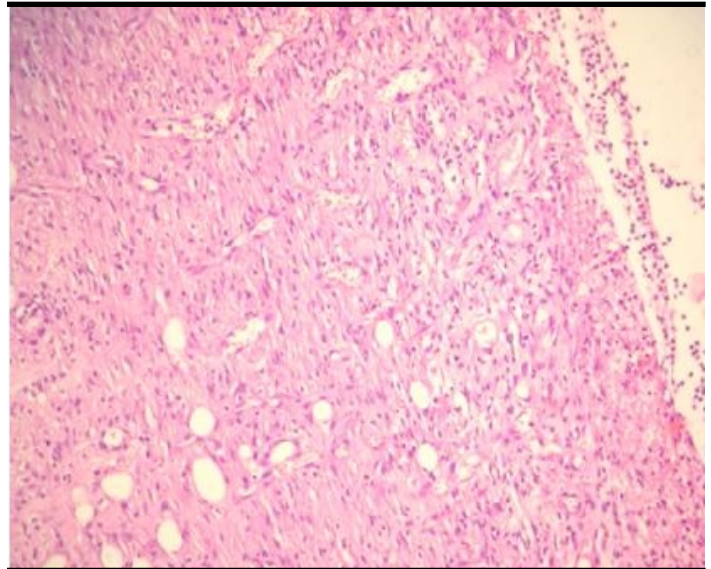


FIGURE 8. Loss at epidermis, severe fibroblast proliferation in the dermis, and angiogenesis (20th day, group1) H&E X200

larisation (angiogenesis) has peaked and reepithelialization starts. From the 2nd week, infiltration of inflammatory cells and increased vascularity declines substantially and collagen accumulation starts. After the 2nd week, in the inflammation and proliferation phase, the macroscopic burn area appears erythematous, turns white after the end of angiogenesis, and scar tissue forms by the end of the 1st month [15,16].

Although the adverse effects of montelukast, such as asthenia, fatigue, headache, hepatitis and Churg–Strauss syndrome, are known, it is still routinely used in the treatment of asthma [23-25]. Montelukast likely exerts the anti-inflammatory effect in burn injury through suppression of a

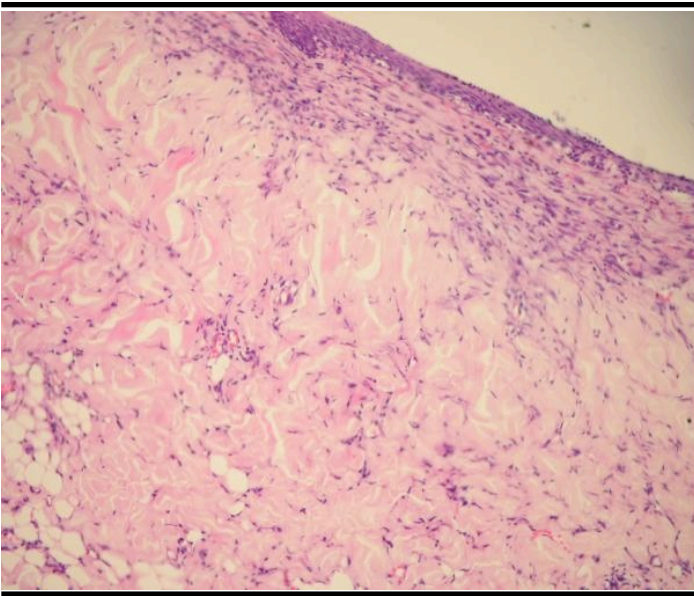


FIGURE 9. Reepithelization, decrease of angiogenesis and fibroblasts in dermis, and initial collagen formation (20th day, group 4) H&E X200

variety of proinflammatory mediators produced by the leukocytes and macrophages [13]. It has been reported that digestive system injuries, that frequently occur in the setting of burns, associate with leukotrienes production and that patients with severe injuries have increased LTE₄ excretion in their urine in comparison with healthy individuals [13,26]. Consequently, leukotriene receptor blockers may be effective in treating burn injuries. In a study carried out on rabbits, the researchers determined that S 872419 A, which is a specific receptor antagonist of peptide leukotrienes, boosted healing of the chemical burn generated in the eye and concluded that other nonsteroidal drugs should improve the anti-inflammatory therapy of the chemically-burned eye [27]. Due to its anti-inflammatory and anti-oxidant effects, montelukast might be useful in the treatment of burn-induced skin and gut injury [2,13]; however, in the research carried out by Sener *et al.* and Kabasakal *et al.*, montelukast is only compared with saline for the treatment of burn injuries [2,13]. Our research compares montelukast with topical antibiotics. In this respect, it is different from the other reported studies.

Burns are susceptible to infection, which is one of the factors that disrupt the healing of these wounds. For this reason, topical antibiotics [1] or antiseptic treatment may be required. Even antiseptic therapy, with a polylactic acid-acetic acid matrix, has an equivalent effectiveness to silver sulfadiazine in the treatment of second and third degree burns [28].

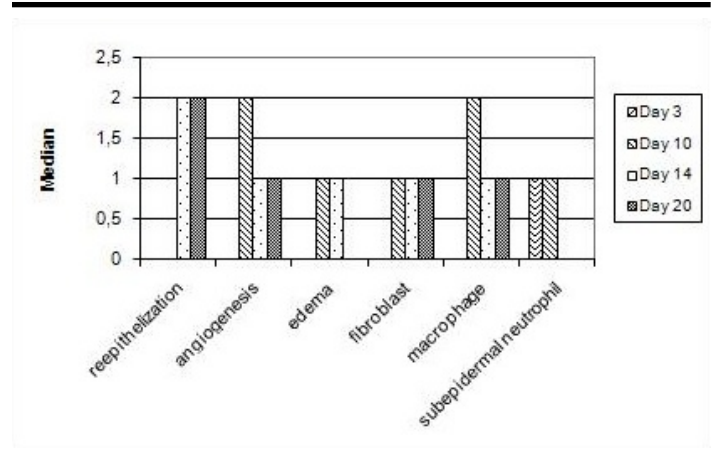


FIGURE 10. Histopathological variables, assessed over time, in the montelukast-treated group

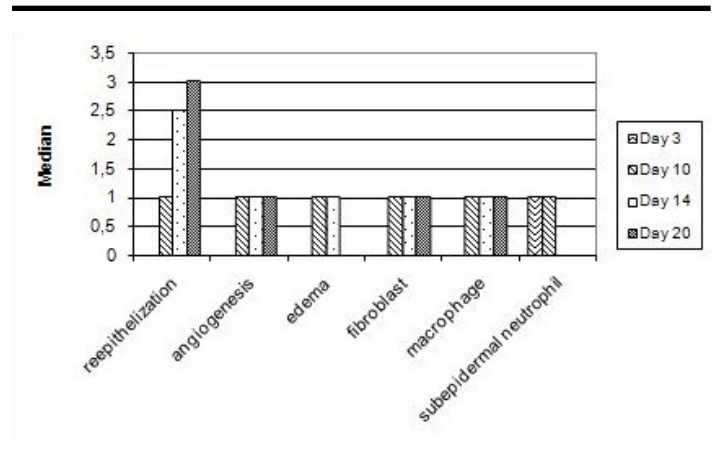


FIGURE 11. Histopathological variables, assessed over time, in the pomade-treated group

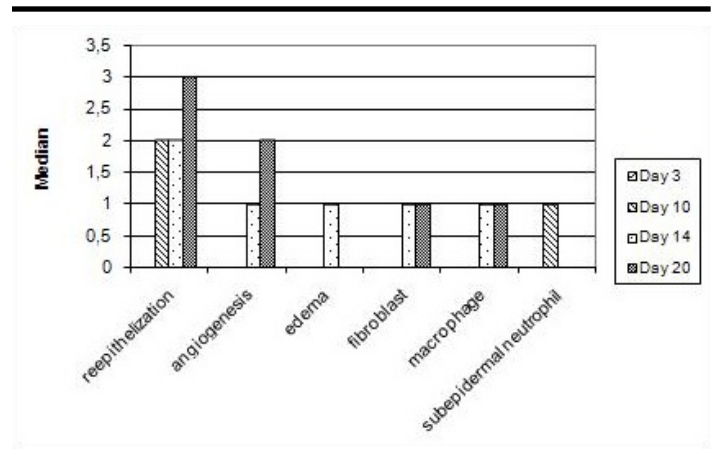


FIGURE 12. Histopathological variables, assessed over time, in the montelukast+pomade-treated group

In this study, in group 2, montelukast administration caused significant reduction in the density of neutrophil leukocytes on the 3rd day – and to a similar extent as that seen with the application of pomade (group 3). The anti-inflammatory effect was observed to be maximum in group 4; where montelukast and topical pomade were administered together. In group 4, hardly any neutrophil leukocytes were observed in the tissue samples. In the proliferation phase, reepithelialization existed as of the 10th day in the two groups where pomade was applied; both solely and in combination with montelukast (groups 3 and 4, respectively) and reepithelialization length increased as the days passed. It was observed that group 4, where montelukast was administered in combination with application of pomade, had the maximum reepithelialization length. No reepithelialization occurred in group 2 on the 10th day, where montelukast was administered without pomade. Although montelukast provided an anti-inflammatory effect, it could not induce reepithelialization. Consistent with the healing process of the burn wound, as of 10th day, angiogenesis, edema, macrophage infiltration, fibroblast proliferation decreased and collagen production increased. In group 4, where montelukast was administered in combination with application of pomade, these parameters decreased and collagen production increased further in comparison with the groups where montelukast and pomade were administered separately (groups 2 and 3, respectively). Thus, although montelukast is not superior to the topical antibiotic pomade routinely used for the treatment of burn injuries, it did show improved outcomes relative to no treatment. The best outcomes were achieved when montelukast was combined with local antibiotic pomade. There may be two reasons for this. The first is that a stronger effect may be generated by the combination of independent effects of montelukast and the topical antibiotic. The second is that montelukast may decrease the inflammation and oxidation caused by the burn injury and help the topical pomade to show its effects better.

Conclusion

We conclude that montelukast is effective in promoting burn wound healing. The effect becomes more significant when combined with the application of a topical antibiotic in the early stage of burn wound healing.

References

1. Palmieri TL, Greenhalgh DG. Topical treatment of pediatric patients with burns: a practical guide. *Am J Clin Dermatol* 2002;3(8):529-534.
2. Sener G, Kabasakal L, Cetinel S, Contuk G, Gedik N, Yeğen BC. Leukotriene receptor blocker montelukast protects against burn-induced oxidative injury of the skin and remote organs. *Burns* 2005 Aug;31(5):587-596.
3. Demling RH, Lalonde C. Systemic lipid peroxidation and inflammation induced by thermal injury persists into the post-resuscitation period. *J Trauma* 1990 Jan;30(1):69-74.
4. Cakir B, Yegen BC. Systemic responses to burn injury. *Turk J Med Sci* 2004;34:215-226.
5. Yamada Y, Endo S, Inada K, Nakae H, Nasu W, Taniguchi S, Ishikura H, Tanaka T, Wakabayashi G, Taki K, Sato S. Tumor necrosis factor-alpha and tumor necrosis factor receptor I, II levels in patients with severe burns. *Burns* 2000 May;26(3):239-44.
6. Meakins JL. Etiology of multiple organ failure. *J Trauma* 1990;30:165-168.
7. Lavaud P, Mathieu J, Bienvenu P, Braquet M, Gerasimo P, Kerigonou JF, Ducouso R. Modulation of leucocyte activation in the early phase of the rabbit burn injury. *Burns Incl Therm Inj* 1988 Feb;14(1):15-20.
8. Damtew B, Marino JA, Fratianne RB, Spagnuolo PJ. Neutrophil lipooxygenase metabolism and adhesive function following acute thermal injury. *J Lab Clin Med* 1993 Feb;121(2):328-336.
9. Dengiz GO, Odabasoglu F, Halici Z, Cadirci E, Suleyman H. Gastroprotective and antioxidant effects of montelukast on indomethacin-induced gastric ulcer in rats. *J Pharmacol Sci* 2007 Sep;105(1):94-102.
10. Damon M, Chavis C, Godard P, Michel FB, Crastes de Paulet A. Purification and mass spectrometry identification of leukotriene D4 synthesized by human alveolar macrophages. *Biochem Biophys Res Commun* 1983 Mar 16;111(2):518-24.
11. Williams JD, Czop JK, Austen KF. Release of leukotrienes by human monocytes on stimulation of their phagocytic receptor for particulate activators. *J Immunol* 1984 Jun;132(6):3034-3040.
12. Aharony D. Pharmacology of leukotriene receptor antagonists. *Am J Respir Crit Care Med* 1998;157:S214-S219.
13. Kabasakal L, Sener G, Cetinel S, Contuk G, Gedik N, Yegen BC. Burn-induced oxidative injury of the gut is ameliorated by the leukotriene receptor blocker montelukast. *Prostaglandins Leukot Essent Fatty Acids* 2005 Jun;72(6):431-440.
14. Choi M, Ehrlich HP. U75412E, a lipoxygenase inhibitor, prevents progressive burn ischemia in a rat burn model. *Am J Pathol* 1993;142(2):519-528.
15. Werner S, Grose R. Regulation of wound healing by growth factors and cytokines. *Physiol Rev* 2003;83(3):835-870.
16. Henry G, Garner WL. Inflammatory mediators in wound healing. *Surg Clin North Am*. 2003;83(3):483-507.
17. Ferrara N, Gerber HP, LeCouter J. The biology of VEGF and its receptors. *Nat Med* 2003;9(6):669-676.
18. Carmeliet P. Angiogenesis in health and disease. *Nat Med* 2003;9(6):653-660.

19. Schwacha MG. Macrophages and post-burn immune dysfunction. *Burns* 2003;29(1):1-14.
20. Tracey KJ. The inflammatory reflex. *Nature* 2002;420(6917):853-859.
21. Nathan C. Points of control in inflammation. *Nature* 2002;420(6917):846-852.
22. Zhu H, Ka B, Murad F. Nitric oxide accelerates the recovery from burn wounds. *World J Surg* 2007;31(4):624-631.
23. Nayak A. A review of montelukast in the treatment of asthma and allergic rhinitis. *Expert Opin Pharmacother*. 2004 Mar;5(3):679-686.
24. Russmann S, Iselin HU, Meier D, Zimmermann A, Simon HU, Caduff P, Reichen J. Acute hepatitis associated with montelukast. *J Hepatol*. 2003 May;38(5):694-695.
25. Conen D, Leuppi J, Bubendorf L, Ronsdorf A, Tamm M, Hauser T. Montelukast and Churg-Strauss syndrome. *Swiss Med Wkly*. 2004 Jun 26;134(25-26):377-380.
26. Westcott JY, Thomas RB, Voelkel NF. Elevated urinary leukotriene E4 excretion in patients with ARDS and severe burns. *Prostaglandins Leukot Essent Fatty Acids* 1991;43(3):151-158.
27. Struck HG, Geiser H, Block HU, Mest HJ, Tost M. Leukotriene antagonist S 872419 A for early-phase treatment of chemical burn in the rabbit eye. *Eur J Ophthalmol* 1991;1(3):137-141.
28. Ryssel H, Gazyakan E, Germann G, Hellmich S, Riedel K, Reichenberger MA, Radu CA. Antiseptic therapy with a polylacticacid-acetic acid matrix in burns. *Wound Repair Regen*. 2010;18(5):439-444.