

An Unexpected Cause of Respiratory Distress and Cyanosis: Cardiac Inflammatory Myofibroblastic Tumor

Ozlem Elkiran, MD,* Cemsit Karakurt, MD,* Nevzat Erdil, MD,† Olcay Murat Disli, MD,† and Adile Ferda Dagli MD‡

Departments of *Pediatric Cardiology, †Cardiovascular Surgery, and ‡Pathology, Inonu University Faculty of Medicine, Malatya, Turkey

ABSTRACT

Inflammatory myofibroblastic tumor is an uncommon spindle cell tumor, occurring mainly in children and young adults. It is an extremely rare cardiac tumor especially patients under 1 year. Although it is benign, the tumor may be very aggressive locally. The diagnosis of this unusual pediatric cardiac tumor without pathologic specimens is difficult. We report a rare case of inflammatory myofibroblastic tumors of the right ventricle in a 7-month-old girl presenting with respiratory distress and cyanosis.

Key Words. Inflammatory Myofibroblastic Tumor; Infant; Respiratory Distress; Cyanosis

Introduction

Primary cardiac tumors are exceedingly rare in children, with an autopsy prevalence of 0.08%. Benign tumors such as rhabdomyoma, fibroma, myxoma, and teratoma account for 78% of all pediatric primary cardiac tumors.^{1,2} Inflammatory myofibroblastic tumor is a very rare primary cardiac tumor that usually involves the lungs and gastrointestinal tract; it rarely involves the heart. It is composed of differentiated myofibroblastic cells accompanied by inflammatory cell infiltration.³⁻⁵ Since the first description of cardiac inflammatory myofibroblastic tumor (IMT) in 1975, there have been only a few additional reports in the medical literature. Its true neoplastic nature and clinical characteristics are still relatively uncertain. IMT is diagnostically troublesome when encountered in the heart because of its infrequency in this location.^{4,6} The clinical and echocardiographic features of IMT often overlap with other intracardiac tumors such as myxoma and rhabdomyoma. Therefore, the diagnosis of this unusual cardiac tumor without pathologic specimens is difficult.⁴ As cardiac IMT may be potentially fatal if a cardiac valve or the coronary arteries are involved, whenever feasible, complete

surgical resection of the tumor remains the definitive treatment and seems to have a satisfactory outcome.^{1,3}

We report a case of inflammatory myofibroblastic tumors of the right ventricle protruding into the right atrium through the tricuspid annulus in a 7-month-old girl who received cardiac surgery for complete resection of the tumor.

Case Report

Previously healthy 7-month-old girl was referred to the pediatric intensive care unit because of 3-day history of fever, three episodes of diarrhea, gradually increasing respiratory distress, and cyanosis. According to her medical history, she was born at full term with an uneventful perinatal course. She had no family history of congenital heart disease.

On physical examination, she was found to have tachypnea (62 breaths/min) and tachycardia (168 beats/min) with a decreased oxygen saturation (75%) and a temperature of 37.2°C. The liver was 5 cm below the costal margins. No pathologic cardiac murmur was detected. The laboratory data revealed elevated white blood cells (14.720/mm³), erythrocyte sedimentation rate (35 mm/h), and C-reactive protein (7.09 mg/L). The hemoglobin level was 10.1 mg/dL, and platelet count was 212 × 10³. All routine blood cultures were negative. Sinusal tachycardia was seen on the electro-

Disclosure of grant(s) or other funding: The authors report that the case report was self-funded.

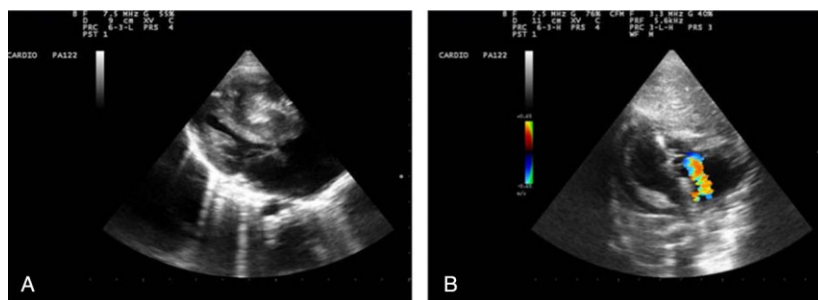


Figure 1. (A) Echocardiographic appearance of the patient: massive mass in right ventricle protruding into right atrium through the tricuspid annulus. (B) Doppler image shows that there are no masses in the heart and second degree tricuspid regurgitation after the resection.

cardiogram (ECG 1150, Nihon Koden, Tokyo, Japan). The chest x-ray was normal. Despite the clinical absence of a heart murmur, continued cyanosis prompted procurement of an echocardiogram.

Two-dimensional and color code transthoracic echocardiography (Mylab 50, Esaote, Florence, Italy) showed a large, mobile mass in the right ventricle, occupying almost 80% of the volume of the right ventricular cavity, an almost completely obliterated tricuspid valve and right ventricular inflow. The mass measured 2.8 cm × 1.6 cm and extended into the right atrium through the tricuspid annulus causing obstruction at the right ventricular inlet and decreased blood flow (Figure 1A). Concurrent cardiac abnormalities have not been detected with good systolic function and no pericardial effusion.

She was intubated and ventilated because of respiratory distress. The indication in this case was immediate surgical resection. During surgical operation, the tumor was completely resected. On gross examination, the tumor was glistening, white, and polypoid (Figure 2). Histological examination of the tumor showed spindle cells with scattered lymphocytes. Immunohistochemistry studies were positive for vimentin and smooth muscle actin and negative for CD31, CD34 anaplastic large cell lymphoma kinase protein, and desmin in spindle cell components, which was consistent with IMT. Atypical mitotic figures were not detected (Figure 3A, B). After cardiac surgery, echocardiography showed no mass in the heart with good systolic function, and no pericardial effusion, but impaired right ventricular function and paradoxical movement of interventricular septum. The color Doppler showed second degree tricuspid valve regurgitation (Figure 1B). She died in the hospital 48 hours after surgery because of systemic inflam-

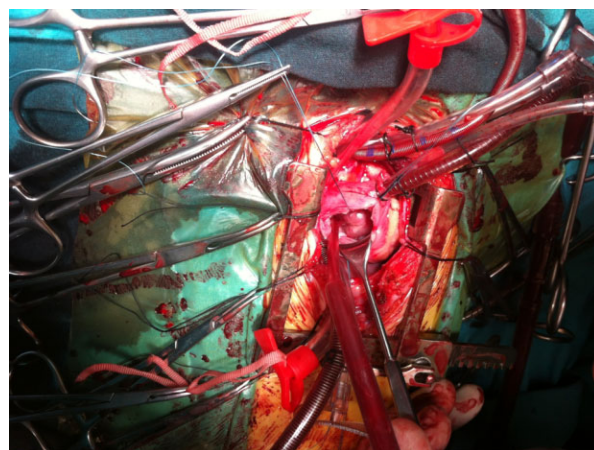


Figure 2. Intraoperative view of the cardiac mass with white, polypoid, and glistening surface.

matory response syndrome and impaired right ventricular function as well as hypotension.

Discussion

Cardiac IMT is extremely rare and involves various sites; the right atrium and right ventricle are more predominant.⁷ Because of the rarity of the tumor in the heart, its natural history and biological potential are still uncertain. The pathogenesis of IMT remains unclear, although it is thought to be an abnormal immunologic response by proliferated spindle cells and primary myofibroblasts to infection, inflammation, or injury.^{7,8} The clinical symptoms and laboratory abnormalities are related to the upregulation of the immune system, including fever, weight loss, anemia, thrombocytosis, and elevated erythrocyte sedimentation rate.^{9,10} Cardiac IMT are considered biologically benign, but because of the location within the heart and size, they are potentially fatal.

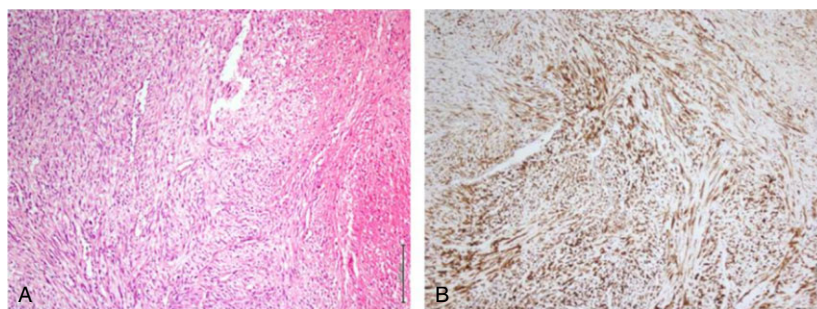


Figure 3. (A) Inflammatory myofibroblastic tumor composed of spindle cell proliferation with interspersed lymphocytes and ischemic necrotic field (hematoxylin and eosin, $\times 100$ magnification). (B) Diffuse immunostaining for smooth muscle actin of inflammatory myofibroblastic tumor (immunoperoxidase, $\times 100$ magnification).

In general, echocardiography has proven a sensitive method for the clinical diagnosis of cardiac tumors. The clinical presentation varies markedly, depending on the site at which the tumor originates.^{11,12} Cardiovascular manifestations are related to the tumor's ability to hinder the filling of the ventricles. Therefore, symptoms may mimic those of mitral or tricuspid valve stenosis. Less commonly, the tumor prevents the leaflet coaptation causing regurgitation of the valve or obstructs outflow of blood causing congestive heart failure.^{4,7,11} Our patient had tachycardia and tachypnea with cyanosis, probably resulting from tricuspid valve obstruction. The differential diagnosis includes cardiac myxoma and papillary fibroelastoma, but the histologic features are sufficiently distinct from these entities. However, the distinction between benign IMT and low-grade sarcoma may be more contentious. The lack of significant pleomorphism and atypical mitotic figures are reliable features of IMT that distinguish them from the cardiac sarcoma.^{1,4} The best accepted treatment is complete surgical resection of the lesion. The results of surgical excision are good, and recurrence of IMT is rare.^{3,7}

Conclusion

Cardiac IMTs are usually benign lesions with a favorable prognosis. However, because cardiac IMT can be potentially fatal, early clinical diagnosis is critical. Surgical resection should be directed toward the elimination of mechanical obstruction whenever feasible. In individuals, especially infants, who have respiratory distress and cyanosis with unexplained causes, an intracardiac tumor including IMT must be taken into consideration.

Author Contributions

Elkiran O, Karakurt C performed the echocardiographic study and wrote the manuscript. Erdil N, Disli OM performed the surgery; Dagli AF performed the histopathological and immunohistochemical evaluation of the specimen. All authors read and approved the final manuscript.

Corresponding Author: Ozlem Elkiran, MD, Faculty of Medicine, Department of Pediatric Cardiology, Inonu University, 42200 Malatya, Turkey. Tel: (+90) 422-3410660-5309; Fax: (+90) 422-3410728; E-mail: ozlemelkiran@yahoo.com

Conflict of interest statement: The authors report no conflicts of interest for this case report.

Accepted in final form: November 11, 2012.

References

- 1 Pucci A, Valori A, Muscio M, Garofalo L, Ferroni F, Abbruzzese PA. Asymptomatic inflammatory myofibroblastic tumor of the heart: immunohistochemical profile, differential diagnosis, and review of the literature. *Cardiovasc Pathol.* 2009;18:187–190.
- 2 Becker AE. Primary heart tumors in the pediatric age group: a review of salient pathologic features relevant for clinicians. *Pediatr Cardiol.* 2000;21:317–323.
- 3 Li L, Cerilli LA, Wick MR. Inflammatory pseudotumor (myofibroblastic tumor) of the heart. *Ann Diagn Pathol.* 2002;6:116–121.
- 4 Burke A, Li L, Kling E, Kutys R, Virmani R, Mietinen M. Cardiac inflammatory myofibroblastic tumor: a “benign” neoplasm that may result in syncope, myocardial infarction, and sudden death. *Am J Surg Pathol.* 2007;31:1115–1122.
- 5 Coffin CM, Watterson J, Priest JR, Dehner LP. Extrapulmonary inflammatory myofibroblastic tumor (inflammatory pseudotumor). A clinico-

- pathologic and immunohistochemical study of 84 cases. *Am J Surg Pathol*. 1995;19:859–872.
- 6 Gonzalez-Crussi F, Vanderbilt BL, Miller JK. Unusual intracardiac tumor in a child. Inflammatory pseudotumor or “granulomatous” variant of myxoma? *Cancer*. 1975;36:2214–2226.
 - 7 Anvari MS, Soleimani A, Abbasi A, et al. Inflammatory myofibroblastic tumor of the right ventricle causing tricuspid valve regurgitation. *Tex Heart Inst J*. 2009;36:164–167.
 - 8 Pettinato G, Manivel JC, De Rosa N, Dehner LP. Inflammatory myofibroblastic tumor (plasma cell granuloma). Clinicopathologic study of 20 cases with immunohistochemical and ultrastructural observations. *Am J Clin Pathol*. 1990;94:538–546.
 - 9 Berman M, Georghiou GP, Schonfeld T, et al. Pulmonary inflammatory myofibroblastic tumor invading the left atrium. *Ann Thorac Surg*. 2003;76:601–603.
 - 10 Coffin CM, Dehner LP, Meis-Kindblom JM. Inflammatory myofibroblastic tumor, inflammatory fibrosarcoma, and related lesions: an historical review with differential diagnostic considerations. *Semin Diagn Pathol*. 1998;15:102–110.
 - 11 Tian JT, Cheng LC, Yung TC. Multiple cardiac inflammatory myofibroblastic tumors in the right ventricle in an infant. *Ann Thorac Surg*. 2006;82:1531–1535.
 - 12 Rose AG, McCormick S, Cooper K, Titus JL. Inflammatory pseudotumor (plasma cell granuloma) of the heart. Report of two cases and literature review. *Arch Pathol Lab Med*. 1996;120:549–554.