

RAPID COMMUNICATION

Resection and primary anastomosis with or without modified blow-hole colostomy for sigmoid volvulus

Sacid Coban, Mehmet Yilmaz, Alpaslan Terzi, Fahrettin Yildiz, Dincer Ozgor, Cengiz Ara, Saim Yologlu, Vedat Kirmlioglu

Sacid Coban, Department of General Surgery, Gaziantep University School of Medicine, Gaziantep 27310, Turkey

Mehmet Yilmaz, Dincer Ozgor, Cengiz Ara, Vedat Kirmlioglu, Department of General Surgery, Inonu University School of Medicine, Malatya 44280, Turkey

Alpaslan Terzi, Fahrettin Yildiz, Department of General Surgery, Harran University School of Medicine, Sanliurfa 63200, Turkey

Saim Yologlu, Department of Biostatistics, Inonu University School of Medicine, Malatya 44280, Turkey

Author contributions: Coban S and Yilmaz M contributed equally to this work; Coban S, Yilmaz M, Ozgor D, Ara C and Kirmlioglu V designed and performed the research; Terzi A, Yildiz F and Yologlu S analyzed data; and Coban S, Terzi A, Yildiz F wrote the paper.

Correspondence to: Sacid Coban, MD, Department of General Surgery, Gaziantep University School of Medicine, Gaziantep 27310, Turkey. sacidcoban@yahoo.com

Telephone: +90-342-3601200-76330 Fax: +90-342-3601013

Received: June 9, 2008

Revised: August 11, 2008

Accepted: August 18, 2008

Published online: September 28, 2008

© 2008 The WJG Press. All rights reserved.

Key words: Acute sigmoid volvulus; Anastomosis; Primary resection; Surgical technique

Peer reviewer: María IT López, Professor, Experimental Biology, University of Jaen, araje de las Lagunillas s/n, Jaén 23071, Spain

Coban S, Yilmaz M, Terzi A, Yildiz F, Ozgor D, Ara C, Yologlu S, Kirmlioglu V. Resection and primary anastomosis with or without modified blow-hole colostomy for sigmoid volvulus.

World J Gastroenterol 2008; 14(36): 5590-5594 Available from:

URL: <http://www.wjgnet.com/1007-9327/14/5590.asp> DOI:

<http://dx.doi.org/10.3748/wjg.14.5590>

Abstract

AIM: To evaluate the efficacy of resection and primary anastomosis (RPA) and RPA with modified blow-hole colostomy for sigmoid volvulus.

METHODS: From March 2000 to September 2007, 77 patients with acute sigmoid volvulus were treated. A total of 47 patients underwent RPA or RPA with modified blow-hole colostomy. Twenty-five patients received RPA (Group A), and the remaining 22 patients had RPA with modified blow-hole colostomy (Group B). The clinical course and postoperative complications of the two groups were compared.

RESULTS: The mean hospital stay, wound infection and mortality did not differ significantly between the groups. Superficial wound infection rate was higher in group A (32% vs 9.1%). Anastomotic leakage was observed only in group A, with a rate of 6.3%. The difference was numerically impressive but was statistically not significant.

CONCLUSION: RPA with modified blow-hole colostomy provides satisfactory results. It is easy to perform and may become a method of choice in patients with sigmoid volvulus. Further studies are required to further establish its role in the treatment of sigmoid volvulus.

INTRODUCTION

The epidemiology and clinical presentation of sigmoid volvulus are well established. Although the clinical manifestations of acute volvulus are often clear-cut, a diagnostic dilemma is not uncommon. Sigmoid volvulus is the third most common cause of large-bowel obstruction in the western world, after cancer and diverticular disease^[1]. It accounts for 4% of all cases of large-bowel obstruction in the United States and United Kingdom^[1,2]. Sigmoid volvulus is relatively more common in Eastern Europe, India and Africa, accounting for 50% of all cases of intestinal obstruction^[1,2].

The precise etiology of sigmoid volvulus remains speculative, and several etiological factors have been suggested including chronic constipation, high fiber diet, bowel habit, high altitude, and enemas containing ginger, pepper and herbal extracts^[3]. Patients with sigmoid volvulus present with abdominal distention, pain, nausea, vomiting, and obstipation, while peritoneal signs are noted infrequently^[4]. The colon is distended often to enormous proportions, particularly when the patient is symptomatic. Plain abdominal X-rays are often diagnostic of volvulus. Air-fluid levels are present, and a "bird's beak" deformity is often seen at the site of the torsion^[5].

Sigmoid volvulus has been described since ancient times, but its treatment continues to evolve^[6,7]. Several therapeutic approaches such as: resection, non-operative

reduction with the help of a colonoscope, sigmoidopexy and mesosigmoidoplasty have been employed^[8]. There is no consensus with regard to the optimal surgical management in patient with an acute presentation. Proximal decompressive blow-hole colostomy has been used in patients with toxic megacolon secondary to inflammatory bowel disease and *clostridium difficile* colitis, with a view to avoid manipulating the colon and to tide over the critical phase^[9]. This procedure is also performed in hemodynamically unstable patients with malignant bowel obstruction^[10-12].

Resection and primary anastomosis (RPA) has emerged as the treatment of choice for sigmoid volvulus over the past two centuries^[6,7]. Particularly in elderly and hemodynamically unstable patients, anastomotic leakage may occur due to co-morbid risk factors with this approach. In such situations, a blow-hole colostomy may play a protective role in avoiding anastomotic leakage.

The aim of the present study was to compare the results of RPA with or without modified blow-hole colostomy in an unprepared bowel in patients with acute sigmoid volvulus.

MATERIALS AND METHODS

From March 2000 to September 2007, 77 patients with acute sigmoid volvulus were treated in the department of general surgery, school of medicine, Inonu University. Colonoscopic derotation was attempted in 27 patients, and was successful in 19 patients. In 10 of the 19 non-operatively reduced patients, semi-elective one-stage resection was performed; the remaining 9 patients refused surgery after non-operative decompression. Hartmann's operation was performed in 11 patients who were not in stable condition. After excluding these 30 cases, the remaining 47 patients who underwent RPA with or without a modified blow-hole colostomy were included in this study.

The diagnosis of sigmoid volvulus was made on the basis of clinical features and plain abdominal radiographs. Laparotomy was performed in all patients after active fluid resuscitation and correction of electrolyte imbalance was obtained. Seftriacson 1000 mg and metronidazole 500 mg were administered intravenously at the time of induction of anesthesia, and were continued every 12 h after the operation for 5 d in patients with viable bowel and for 7 d in those with gangrenous bowel.

None of the patients included in the study were treated with preoperative decompression techniques. At laparotomy, the distended bowel was decompressed by using a rectal tube, and any residual feces was milked digitally into the segment of the bowel to be resected. Although the bowel was unprepared, on-table lavage was not performed in any patient. Informed consent was obtained from each patient prior to the surgery. In 25 patients, RPA (Group A) was performed and in the remaining 22 patients, a modified blow-hole colostomy was performed with RPA (Group B). All the anastomoses were inverting and two-layered.

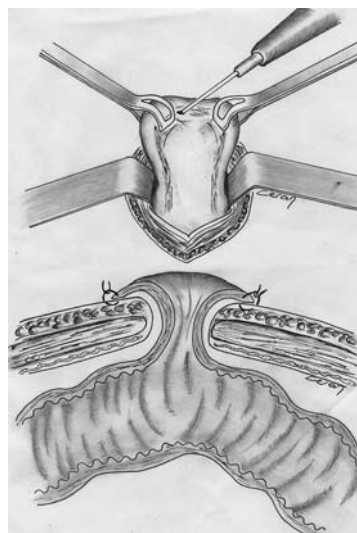


Figure 1 The cut edges of the colon were sutured to the skin with 3/0 vicryl, without fascial or peritoneal sutures. Therefore, the procedure was called “modified blow-hole colostomy technique”.

The clinical course and postoperative complications were documented. Wound infection was defined as spontaneous discharge of pus from the wound or a wound that requires drainage. Anastomotic leak was defined as the presence of fecal fistula or the presence of feces in the drain.

Surgical technique of modified blow-hole colostomy

In group B, a proximal stoma was performed to protect the anastomoses. A 3 cm longitudinal incision was made through the tenia libera, and into the transverse colon. An abdominal wall aperture intended for the colostomy was made in the right upper quadrant using a rectus splitting incision. The collapse of the colon allowed it to reach the incision, and facilitated performing a skin-level colostomy. In the blow-hole colostomy technique which has been previously reported, the omentum and seromuscular layers of the colon were attached to the peritoneum and the rectus fascia with interrupted or continuous sutures^[9]. In the present study, the cut edges of the colon were sutured to the skin with 3/0 vicryl without fascial or peritoneal sutures. As a result, we call it a “modified blow-hole colostomy technique” (Figure 1). In these patients, oral intake was started on postoperative day 1. On postoperative day 10, the anastomotic integrity was checked using water-soluble radiological studies, and if intact, colostomy closure was performed.

Statistical analysis

Statistical analyses were performed using SPSS for Windows version 11.0 program. Continuous variables were reported as mean \pm SD. Categorical variables were reported as percent. Normality for continued variables in groups was determined by the Shapiro Wilk test. The variables showed normal distribution ($P > 0.05$). Therefore, unpaired *t*-test was used for comparison of variables (age and length of hospital stay) between the two groups. Fisher's Exact and Pearson χ^2 tests were used for comparison of categorical variables between the groups. $P < 0.05$ was considered as significant.

Table 1 Operative procedure, morbidity and deaths in 47 patients

Procedure	No. of patients	Wound infection	Anastomotic dehiscence	Deaths
RPA (Group A)	25 (16V, 9G)	6V, 2G	2V, 1G	1V, 1G
RPA with modified blow-hole colostomy (Group B)	22 (17V, 4G, 1P)	2V	-	1V, 1G
Total	47 (33V, 13G, 1P)	10 (8V, 2G)	3 (2V, 1G)	4 (2V, 2G)

V: Viable; G: Gangrenous; P: Perforation; RPA: Resection and primary anastomosis.

Table 2 Comparison of confounding variables between Group A (RPA) and Group B (RPA with modified blow-hole colostomy)

Variable	Group A (n = 25)	Group B (n = 22)	Statistical test and significance
Age (yr)	66.12 ± 14.17	62.27 ± 16.26	Unpaired <i>t</i> -test, <i>P</i> = 0.391
Sex: Female ratio	4/25 (16%)	3/22 (13.6%)	Fisher's exact test, χ^2 -test, <i>P</i> = 0.574
Hospital stay (d)	13.68 ± 8.47	16.72 ± 4.90	Unpaired <i>t</i> -test, <i>P</i> = 0.145
Wound infection	8 (32%)	2 (9.1%)	χ^2 -test, <i>P</i> = 0.11
Anastomotic leak	3 (12%)	-	Fisher's exact test, χ^2 -test, <i>P</i> = 0.142
Mortality	2 (8%)	2 (10%)	Fisher's exact test, χ^2 -test, <i>P</i> = 0.645

RESULTS

Forty-seven consecutive patients (7 women and 40 men), who had undergone RPA (25 patients) or RPA with modified blow-hole colostomy (22 patients) were evaluated. There was no significant difference between the two groups in the mean age or the sex ratio. The operative procedures and postoperative outcomes are shown in Table 1. Nine (36%) patients in group A and 5 (22%) in group B had gangrenous bowel. The mean hospital stay, wound infection and mortality did not differ between the groups (Table 2). However, superficial wound infection was almost four times more common in the group A (32% *vs* 9.1%), and nearly two times more common in patients with a viable colon. All the infected wounds healed with conservative measures. Three patients (12%) developed anastomotic leak in group A; two had viable colon and one had gangrenous sigmoid colon. At re-laparotomy, Hartmann's procedure was performed in patients with anastomotic dehiscence. No anastomotic leak was observed in group B. The time to resumption of oral intake was postoperative day 4 in group A, and day 1 in group B, due to the presence of a protective stoma. All patients in group B, had stoma closure performed on postoperative day 10, after radiological studies were carried out. Development of leak or wound infection secondary to stoma closure was not observed in any patient.

The mortality rates were identical in the two groups. One patient died of myocardial infarction and one of sepsis resulting from anastomotic dehiscence in group

A on the 1st and 4th postoperative day respectively. In group B, one patient died on the 6th postoperative day due to pulmonary embolism, and one patient died secondary to multi-system organ failure on the 16th postoperative day.

DISCUSSION

The management of sigmoid volvulus involves relief of obstruction and prevention of recurrence. Several operative procedures have been used in the emergency management of sigmoid volvulus. However, permanent cure involves resection of the sigmoid colon, with or without anastomosis^[7,13,14]. Less extensive procedures are not always successful and are contraindicated if gangrene or compound volvulus is present^[15]. Colonoscopic detorsion and laparotomy with detorsion and colopexy are associated with appreciable morbidity^[16]. A recent study reported on the use of laparoscopic recto-sigmoidectomy following colonoscopic decompression in nine patients^[17]. Although further studies with larger number of patients are required, this technique appears to be a good option, but can only be applied in decompressed patients.

Traditional surgical teaching has dictated that a primary anastomosis should not be undertaken in an unprepared, obstructed bowel^[18-20]. A number of studies on sigmoid volvulus explored the feasibility of one-stage resection using on-table lavage^[13,21-24]. The advantages of this approach include single stage procedure, no need for a colostomy, possible lower morbidity and mortality, and shorter hospital stay. The disadvantages include prolonged operative time, need for several liters of irrigation solution, and risk of contamination. However, clinical and experimental evidence supports the view that a clean bowel has an important advantage in surgery of the left colon and rectum, which are parts of the bowel containing solid feces, with a high bacterial count^[19,25]. Therefore, an emergency RPA of an unprepared left colon is a controversial subject. Traditionally, obstruction of the left colon is managed by a multi-stage defunctioning colostomy and resection. However, there is a growing acceptance of one-stage primary resection and anastomosis with the use of on-table antegrade irrigation^[24,26-28]. However, several studies have suggested that on-table lavage may not be necessary for a safe emergency RPA of unprepared left colon^[26-29]. Most experts agree that temporary proximal fecal diversion or decompression can reduce the risk of sepsis resulting from anastomotic leakage^[30,31]. All patients in the two study groups, had RPA after intra-operative decompression without any on-table lavage.

Symptomatic anastomotic leak is the most important postoperative complication following emergency colorectal resection with intestinal anastomosis. De *et al*^[26] reported 197 patients who had a single stage primary anastomosis without colonic lavage for left-sided colonic obstruction due to acute sigmoid volvulus; only 2 (1.01%) patients developed symptomatic anastomotic leak. In a similar prospective study by

Raveenthiran^[29], 57 consecutive patients with acute sigmoid volvulus had emergency RPA without on-table lavage or caecostomy. The anastomotic leak was seen in 10% patients, with higher leak rate in patients with gangrenous colon. Factors such as acute anemia, shock and peri-operative whole blood transfusion are believed to be associated with major anastomotic leaks in patients with gangrenous colon. Due to these comorbid risk factors, particularly in patients presenting with gangrenous sigmoid volvulus, the addition of a modified blow-hole colostomy appears to be a promising procedure in order to avoid anastomotic leak. Early diet consumption is another advantage of this procedure and may improve the postoperative course. In the present study, anastomotic leakage occurred in 3 (6.3%) patients in group A, compared to none in group B. The difference was numerically impressive but not statistically significant. Comparison of hospital stay, mortality and wound infection did not reveal any significant difference between the two groups. The lower rate of wound infection in group B is a controversial subject. In our opinion, this is probably due to the beneficial effect of early dietary consumption. Previous studies have clearly shown the advantages of early enteral nutrition in surgical patients in reducing septic complications and the overall morbidity compared to parenteral nutrition^[32,33].

In conclusion, RPA with modified blow-hole colostomy provides satisfactory results in patients with sigmoid volvulus. This procedure is safe and effective in preventing anastomotic leaks, and may become the treatment of choice in patients with sigmoid volvulus. Further studies are required to definitively establish its role in sigmoid volvulus.

COMMENTS

Background

Although the diagnosis of sigmoid volvulus is not difficult, the emergent surgical approach to sigmoid volvulus is a subject of much debate. There is a growing acceptance of one-stage primary resection and anastomosis of sigmoid colon. However, with this approach, anastomotic leakage may occur, particularly in elderly and hemodynamically unstable patients. Blow-hole colostomy can play a protective role to avoid anastomotic leakage. In the present study, we compared the results of resection and primary anastomosis (RPA), with or without the use of a modified blow-hole colostomy in unprepared bowel in patients with acute sigmoid volvulus.

Research frontiers

Anastomotic leakage is the most important postoperative complication following emergency colorectal resection with intestinal anastomosis. Temporary proximal fecal diversion or decompression can reduce the risk of sepsis from anastomotic leakage. The present study showed that RPA with modified blow-hole colostomy in unprepared bowel with sigmoid volvulus is effective in preventing anastomotic leakage.

Innovations and breakthroughs

This is a new technique for use in patients with sigmoid volvulus. We believe that this technique will decrease the rate of complications such as anastomotic leakage, especially in high risk patients.

Applications

The present study has shown that RPA with modified blow-hole colostomy for sigmoid volvulus is a safe procedure, which enables successful decompression and avoids high mortality rates, particularly in elderly and hemodynamically unstable patients. Future studies will be required to verify the effectiveness and safety of this technique.

Peer review

The authors compared the efficacy of two different type of surgery in patients with sigmoid volvulus. The observations are interesting.

REFERENCES

- 1 **Welch GH**, Anderson JR. Acute volvulus of the sigmoid colon. *World J Surg* 1987; **11**: 258-262
- 2 **Wertkin MG**, Aufses AH Jr. Management of volvulus of the colon. *Dis Colon Rectum* 1978; **21**: 40-45
- 3 **Avots-Avotins KV**, Waugh DE. Colon volvulus and the geriatric patient. *Surg Clin North Am* 1982; **62**: 249-260
- 4 **Oncu M**, Piskin B, Calik A, Yandi M, Alhan E. Volvulus of the sigmoid colon. *S Afr J Surg* 1991; **29**: 48-49
- 5 **Geer DA**, Arnaud G, Beitleer A, Holcomb J, Homan J, James L, Martin D, McWhirt E, Napoli P. Colonic volvulus. The Army Medical Center experience 1983-1987. *Am Surg* 1991; **57**: 295-300
- 6 **Ballantyne GH**. Review of sigmoid volvulus. Clinical patterns and pathogenesis. *Dis Colon Rectum* 1982; **25**: 823-830
- 7 **Madiba TE**, Thomson SR. The management of sigmoid volvulus. *J R Coll Surg Edinb* 2000; **45**: 74-80
- 8 **Peoples JB**, McCafferty JC, Scher KS. Operative therapy for sigmoid volvulus. Identification of risk factors affecting outcome. *Dis Colon Rectum* 1990; **33**: 643-646
- 9 **Remzi FH**, Oncel M, Hull TL, Strong SA, Lavery IC, Fazio VW. Current indications for blow-hole colostomy: ileostomy procedure. A single center experience. *Int J Colorectal Dis* 2003; **18**: 361-364
- 10 **Huang WS**, Liu KW, Lin PY, Hsieh CC, Wang JY. Delayed ischemic gangrene change of distal limb despite optimal decompressed colostomy constructed in obstructed sigmoid colon cancer: a case report. *World J Gastroenterol* 2006; **12**: 993-995
- 11 **Poon RT**, Law WL, Chu KW, Wong J. Emergency resection and primary anastomosis for left-sided obstructing colorectal carcinoma in the elderly. *Br J Surg* 1998; **85**: 1539-1542
- 12 **Lau PW**, Lo CY, Law WL. The role of one-stage surgery in acute left-sided colonic obstruction. *Am J Surg* 1995; **169**: 406-409
- 13 **Sule AZ**, Iya D, Obekpa PO, Ogbonna B, Momoh JT, Ugwu BT. One-stage procedure in the management of acute sigmoid volvulus. *J R Coll Surg Edinb* 1999; **44**: 164-166
- 14 **Kuzu MA**, Aslar AK, Soran A, Polat A, Topcu O, Hengirmen S. Emergent resection for acute sigmoid volvulus: results of 106 consecutive cases. *Dis Colon Rectum* 2002; **45**: 1085-1090
- 15 **Ballantyne GH**, Brandner MD, Beart RW Jr, Ilstrup DM. Volvulus of the colon. Incidence and mortality. *Ann Surg* 1985; **202**: 83-92
- 16 **Lal SK**, Morgenstern R, Vinjirayer EP, Matin A. Sigmoid volvulus an update. *Gastrointest Endosc Clin N Am* 2006; **16**: 175-187
- 17 **Cartwright-Terry T**, Phillips S, Greenslade GL, Dixon AR. Laparoscopy in the management of closed loop sigmoid volvulus. *Colorectal Dis* 2008; **10**: 370-372
- 18 **Reilly PMJ**, Jones B, Bulkeley GB. Volvulus of the colon. In Cameron JL., ed. *Current Surgical Therapy*. St Louis: Decker Inc, 1992: 170-174
- 19 **Irvin TT**, Goligher JC. Aetiology of disruption of intestinal anastomoses. *Br J Surg* 1973; **60**: 461-464
- 20 **Smith SR**, Connolly JC, Gilmore OJ. The effect of faecal loading on colonic anastomotic healing. *Br J Surg* 1983; **70**: 49-50
- 21 **Gurel M**, Alic B, Bac B, Keles C, Akgun Y, Boylu S. Intraoperative colonic irrigation in the treatment of acute sigmoid volvulus. *Br J Surg* 1989; **76**: 957-958
- 22 **Gibney EJ**. On-table lavage in the management of sigmoid volvulus: a review. *West Afr J Med* 1992; **11**: 223-225

- 23 **Keller A**, Aeberhard P. Emergency resection and primary anastomosis for sigmoid volvulus in an African population. *Int J Colorectal Dis* 1990; **5**: 209-212
- 24 **Sule A**, Obepka PO, Iya D, Ogbonna B, Momoh J. Intraoperative colonic irrigation in the management of left sided large bowel emergencies in Jos University Teaching Hospital, Nigeria. *East Afr Med J* 2000; **77**: 613-617
- 25 **Nwafo DC**. Selective primary suture of the battle-injured colon: an experience of the Nigerian Civil War. *Br J Surg* 1980; **67**: 195-197
- 26 **De U**, Ghosh S. Single stage primary anastomosis without colonic lavage for left-sided colonic obstruction due to acute sigmoid volvulus: a prospective study of one hundred and ninety-seven cases. *ANZ J Surg* 2003; **73**: 390-392
- 27 **Naaeder SB**, Archampong EQ. One-stage resection of acute sigmoid volvulus. *Br J Surg* 1995; **82**: 1635-1636
- 28 **Duthie GS**, Foster ME, Price-Thomas JM, Leaper DJ. Bowel preparation or not for elective colorectal surgery. *J R Coll Surg Edinb* 1990; **35**: 169-171
- 29 **Raveenthiran V**. Restorative resection of unprepared left-colon in gangrenous vs. viable sigmoid volvulus. *Int J Colorectal Dis* 2004; **19**: 258-263
- 30 **Pakkastie TE**, Ovaska JT, Pekkala ES, Luukkonen PE, Jarvinen HJ. A randomised study of colostomies in low colorectal anastomoses. *Eur J Surg* 1997; **163**: 929-933
- 31 **Karanjia ND**, Corder AP, Holdsworth PJ, Heald RJ. Risk of peritonitis and fatal septicaemia and the need to defunction the low anastomosis. *Br J Surg* 1991; **78**: 196-198
- 32 **Meguid MM**, Campos AC, Hammond WG. Nutritional support in surgical practice: Part II. *Am J Surg* 1990; **159**: 427-443
- 33 **Moore FA**, Feliciano DV, Andrassy RJ, McArdle AH, Booth FV, Morgenstein-Wagner TB, Kellum JM Jr, Welling RE, Moore EE. Early enteral feeding, compared with parenteral, reduces postoperative septic complications. The results of a meta-analysis. *Ann Surg* 1992; **216**: 172-183

S- Editor Li DL L- Editor Anand BS E- Editor Lin YP