

Conclusion

Our case report shows a successful treatment of a post Fontan persistent thoracic drainage by the help of high dose octreotide. Although the reason of persistent pleural drainage was not chyle, high dose octreotide diminished the amount of pleural effusion. Further investigations are needed to understand the effect of octreotide in both chylothorax and post Fontan persistent thoracic drainage.

References

1. Cava JR, Bevandic SM, Steltzer MM, Tweddell JS. A medical strategy to reduce persistent chest tube drainage after the Fontan operation. *Am J Cardiol* 2005; 96: 130-3.
2. Walther T, Theune P, Sullivan I, de Leval MR. Successful medical treatment of persistent pleural drainage after the Fontan operation. *Interact CardioVasc Thorac Surg* 2003; 2: 348-49.
3. Goto M, Kitano M, Watanabe K, Watanabe K, Chiba Y. et al. Treatment of chylothorax in a premature infant using somatostatin. *J Perinatol* 2003; 23: 563-4.
4. Pratap U, Slavik Z, Ofoe VD, Onuzo O, Franklin RC. Octreotide to treat postoperative chylothorax after cardiac operations in children. *Ann Thorac Surg* 2001; 72: 1740-2.
5. Rosti L, Bini RM, Chessa M, Butera G, Drago M, Carminati M. The effectiveness of octreotide in the treatment of post-operative chylothorax. *Eur J Pediatr* 2002; 161: 149-50.
6. Buettiker V, Hug MI, Burger R, Baenziger O. Somatostatin: a new therapeutic option for the treatment of chylothorax. *Intens Care Med* 2001; 27: 1083-6.
7. Jacobs ML, Norwood WI Jr. Fontan operation: influence of modifications on morbidity and mortality. *Ann Thorac Surg* 1994; 58: 945-51.
8. Lemler MS, Scott WA, Leonard SR, Stromberg D, Ramaciotti C. Fenestration improves clinical outcome of the Fontan procedure: a prospective, randomized study. *Circulation* 2002; 105: 207-12.

Recanalization of occluded modified Blalock-Taussig shunt with balloon angioplasty and intraarterial streptokinase

Balon anjiyoplasti ve intraarteriyel streptokinaz ile rekanalize olan tromboze modifiye Blalock-Taussig şant olgusu

*Cemşit Karakurt, Gülendam Koçak, Ünsal Özgen**

From Departments of Pediatric Cardiology and *Pediatric Haematology, Faculty of Medicine, İnönü University, Malatya, Turkey

Introduction

Progressive stenosis and acute thrombosis, months to years after surgical creation, are the most known complications of the modified Blalock-Taussig shunt (1, 2). Children who developed acute Blalock-Taussig shunt occlusion usually require some form of intervention which includes thrombolytic therapy. Tissue plasminogen activator and streptokinase have been used successfully in some children (3, 4). Balloon angioplasty, stent implantation and surgery are the other therapeutic options (5-7).

We report an 11 months old patient with acute modified Blalock-Taussig shunt occlusion. The patient was treated successfully with balloon angioplasty and intraarterial streptokinase.

Case Report

An 11 months old girl with situs inversus totalis, double outlet right ventricle, malposition of great arteries, complete atrioventricular septal defect, pulmonary stenosis, hypoplasia of pulmonary arteries and right-sided modified Blalock-Taussig shunt was admitted to our hospital due to severe cyanosis and respiratory distress. Arterial blood gas parameters were consistent with hypoxia, and oxygen saturation was 35%. Detailed history revealed that she had undergone a right-sided

modified Blalock-Taussig shunt with 4 mm Gore-tex graft three months ago. She was discharged after one week of uneventful follow-up and oral anticoagulation was started after surgery with aspirin. Her condition had deteriorated suddenly, approximately 12 hours before admission.

On admission physical examination showed severe cyanosis and respiratory distress, but the lungs were clear on auscultation. There was no continuous murmur audible at the right sternal border. The typical high velocity, continuous flow profile of the shunt could not be identified by color Doppler echocardiography. Her oxygen saturation was 35%. She was taken up for urgent cardiac catheterization within 4 hours of hospitalization to confirm the diagnosis and perform transcatheter recanalization. Using a percutaneous left femoral artery approach, 50 U/kg heparin was given intravenously and 5F multipurpose catheter was advanced into the right subclavian artery. Right subclavian artery angiogram confirmed complete occlusion of right-sided modified Blalock-Taussig shunt (Fig. 1, 2). A 0.014 inch floppy guidewire was advanced to the left pulmonary artery via B-T shunt. The multipurpose catheter was exchanged over the guidewire with a 4X20 mm percutaneous transluminal coronary angioplasty (PTCA) catheter. After placement the PTCA catheter within the shunt, balloon angioplasty was performed twice (Fig. 3, 4). An irregular contour on the pulmonary side of the shunt was observed in control angiograms performed after balloon angioplasty (Fig. 5). Fibrinolytic treatment with streptokinase was

administered after insertion of the multipurpose catheter for the second time into the proximal end of the shunt. Transcatheter lysis with streptokinase 1500 U/kg was continued for 15 minutes. The final angiogram showed the thrombus to have disappeared and the shunt was completely patent (Fig. 6). Immediately after intervention, oxygen saturation rose from 35% to 85% in room air. There were no signs or symptoms of respiratory failure in intensive care monitoring after angioplasty procedure. Blood sample was taken for the evaluation of thrombosis etiology.

Subcutaneous nadroparine calcium and oral coumadine treatments were started after balloon angioplasty. Nadroparine calcium was discontinued on the 3rd day, and thereafter coumadine together with aspirin were administered. Protein C level was 47% (70-130%), protein S was 61% (60-140%), and antithrombin III level was 62% (80-120%). Factor V Leiden (FV G1691A), prothrombin

(PTH G20210A), and MTHFR (C677T) mutations were not detected. Protein C and antithrombin III levels of parents were within normal limits. Protein C, S and antithrombin III levels were re-evaluated three months later, and all were within normal limits.

Discussion

Occlusion or stenosis of a modified Blalock-Taussig shunt is not infrequent and have been reported in a variety of clinical settings (1). The incidence of thrombotic occlusion of Blalock-Taussig shunts ranges from 1 to 17% (8, 9). The stenotic shunts were characterized by formation of neointima, macrophage accumulation, multiple small areas of calcification, and thrombi of varying ages (8). Shunt failure presents in two different clinical settings. Those occurring over a period of time

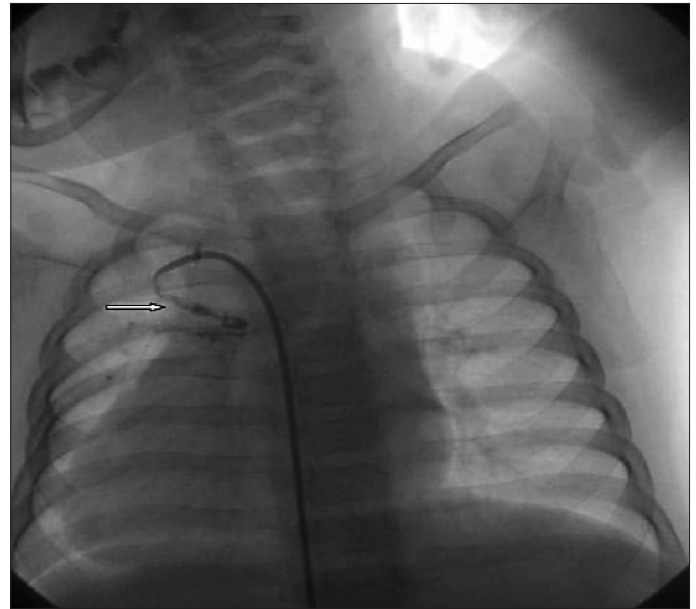
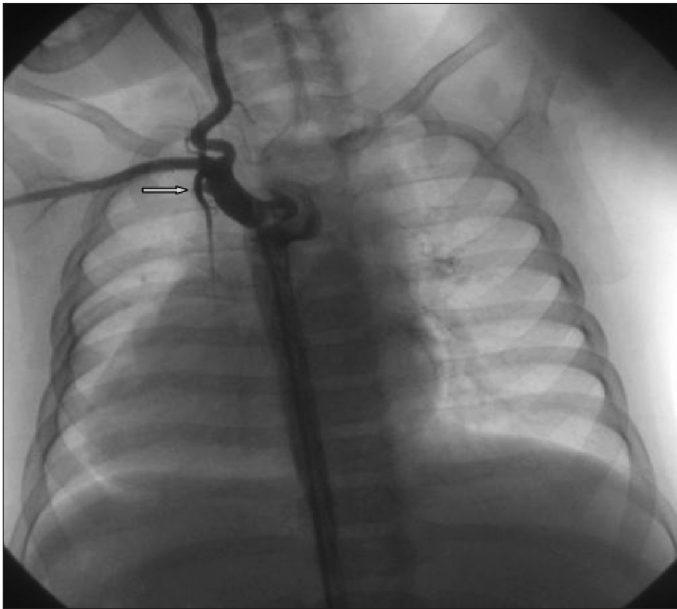


Figure 1 and 2. Antero-posterior angiograms performed in the right subclavian artery show occluded right-sided modified Blalock-Taussig shunt (white arrow).

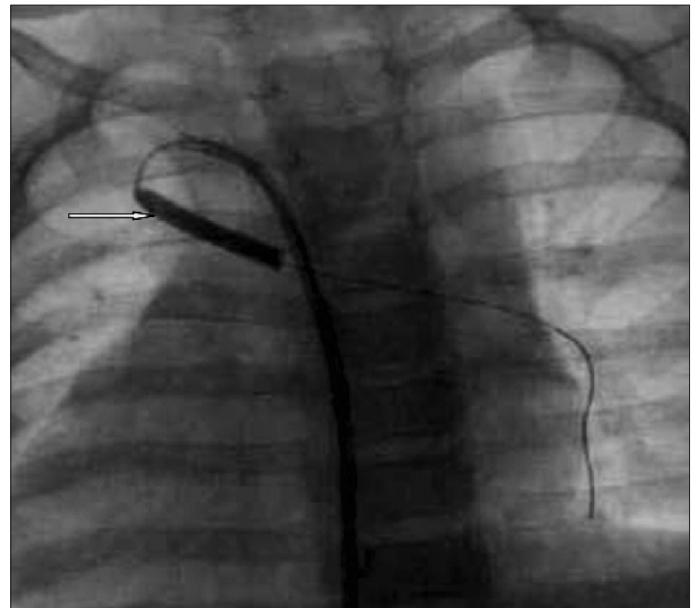
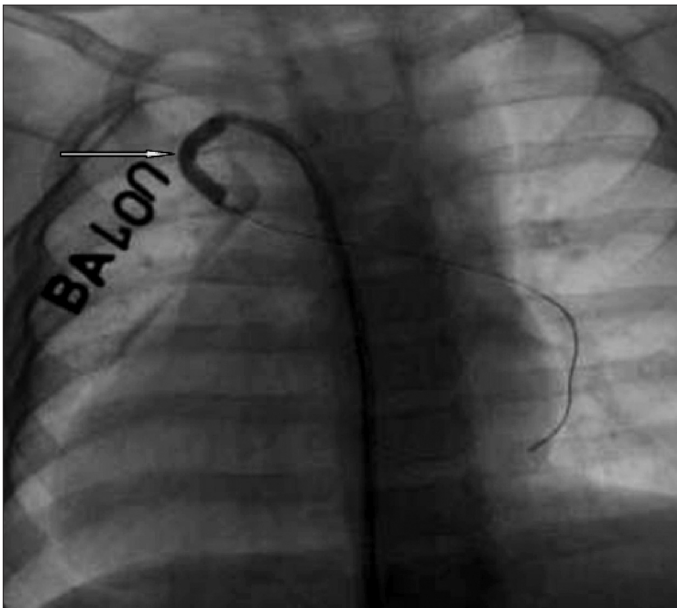


Figure 3 and 4. Anteroposterior angiograms showing balloon angioplasty procedure of occluded modified Blalock-Taussig shunt (white arrow).

result in gradual worsening of cyanosis, polycythemia, effort intolerance and progress to total occlusion. The other presentation is an acute shunt occlusion in patients with shunt-dependent pulmonary blood flow, which can result in sudden onset life-threatening hypoxia, acute respiratory distress, acidosis, hypotension and even death. The clinical diagnosis of acute shunt obstruction with sudden onset cyanosis and absent shunt murmur should prompt immediate action. In suspected patients, echocardiography is a noninvasive reliable diagnostic tool. A second shunt may be required if the pulmonary artery size, weight or age of the patient are suboptimal for the definitive surgery.

Balloon angioplasty with or without thrombolytic therapy for acute occluded modified Blalock-Taussig shunt is an alternative to a second shunt procedure (1, 5). Wang et al. (6) performed balloon angioplasty for obstructed systemic-to-pulmonary artery shunt in 46 patients from 1994 to 1999. Thirty-two of these patients had modified Blalock-Taussig shunt and these shunts were successfully opened with balloon angioplasty (6). In our patient, Blalock-Taussig shunt was opened with balloon angioplasty but thrombolytic therapy was required due to an irregular contour on the pulmonary side of the shunt that was convenient to the thrombus.

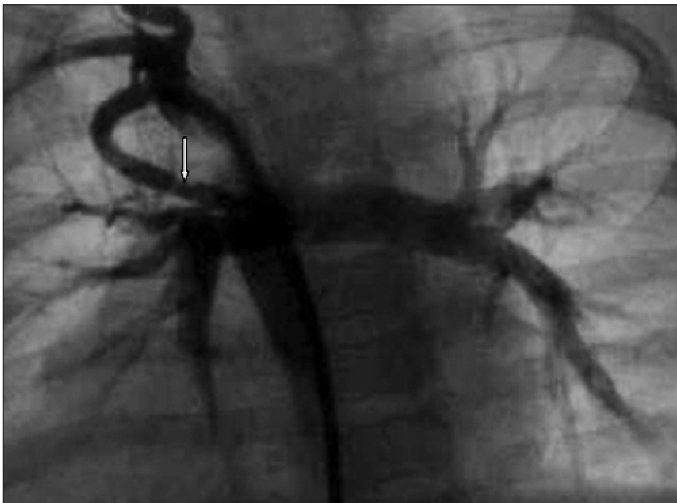

Figure 5. Control anteroposterior angiogram shows completely patent but irregular contour seen in pulmonary site of the right-sided modified Blalock-Taussig shunt (white arrow)

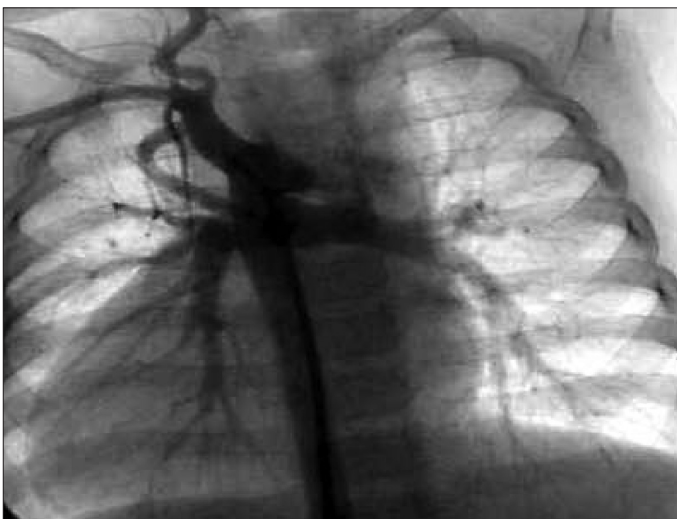

Figure 6. Control angiogram performed after intraarterial streptokinase shows completely patent right-sided modified shunt.

Thrombolysis with various fibrinolytic agents has been described in cases with occluded shunts, as an alternative or adjuvant therapy to balloon angioplasty. Stent implantation is another alternative procedure to balloon angioplasty or thrombolysis in selected patients who have contraindications to thrombolytic therapy, such as recent surgery or neurological injury (7). Thrombolytic agents such as tissue plasminogen activator, urokinase, and streptokinase have been used in a systemic way or local route (3, 4). Localized catheter-directed application is generally preferred because of its lesser dose, lesser side effects, and more effectiveness than systemic application. Various streptokinase dosages have been recommended for clinical use, but there is no standard intraarterial dose in the literature (3). Streptokinase has been used in a dose of 70 U/kg or 5000U/hr for intraarterial thrombolysis (9, 10). The usual recommended dose is 3000-4000U/kg bolus injection together with 1000-1500 U/kg/hour low-dose infusion thereafter. We infused intraarterial streptokinase immediately after balloon angioplasty due to the irregular contour seen in angiograms on the pulmonary side of the modified Blalock-Taussig shunt. Although we had planned to give 24 000 U streptokinase in 30 minutes, we discontinued the infusion after observing complete patency in angiograms after the half dose of streptokinase (12 000 U). Therefore, we stopped streptokinase on 15th minute of infusion. Sivakumar et al. (10) performed balloon angioplasty on 5 patients with acute (10) shunt thrombolysis. One of these patients was successfully treated with local intraarterial streptokinase infusion as a 1000U/kg/hour dose and another patient required balloon angioplasty after streptokinase infusion at a dose of 1000 units/kg/hour for 6 hours, because its infusion was discontinued as hypotension and acidosis worsened and oxygen saturation dropped to 35% (10).

In conclusion, we presented an 11 months old patient with acute modified Blalock-Taussig shunt occlusion, who was successfully treated with balloon angioplasty and intraarterial streptokinase. When a second shunt is under consideration in a patient with obstructed shunt; performing balloon angioplasty with or without intraarterial streptokinase is a feasible, effective, and safe alternative procedure.

References

1. Godart F, Qureshi S, Simha A, Daverall PB, Anderson DR, Baker EJ, et al. Effects of modified and classic Blalock-Taussig shunts on the pulmonary arterial tree. *Ann Thorac Surg* 1998; 66: 512-7.
2. Fermanis GG, Ekangaki AK, Salmon AP, Keeton BR, Shore DF, Lamb RK, et al. Twelve year experience with the modified Blalock-Taussig shunt in neonates. *Eur J Cardiothorac Surg* 1992; 6: 586-9.
3. Bajzar L, Albisetti M. Thrombolysis in children with congenital heart disease. *Progr Pediatr Cardiol* 2005; 21: 45-51.
4. Rajani R, Dalvi B, Kulkarni H, Kale PA. Acutely blocked Blalock-Taussig shunt following cardiac catheterization: successful recanalization with intravenous streptokinase. *Am Heart J* 1990; 120: 1238-9.
5. MacMillan M, Jones TK, Lupinetti FM, Johnston TA. Balloon angioplasty for Blalock-Taussig shunt failure in the early postoperative period. *Cathet Cardiovasc Interv* 2005; 66: 585-9.
6. Wang JK, Wu MH, Chang CI, Chiu IS, Lue HC. Balloon angioplasty for obstructed modified systemic-pulmonary artery shunts and pulmonary artery stenosis. *J Am Coll Cardiol* 2001; 37: 940-7.
7. Peuster M, Fink C, Bertram H, Paul T, Hausdorf G. Transcatheter recanalization and subsequent stent implantation for the treatment of early postoperative thrombolysis of modified Blalock-Taussig shunts in two children. *Cathet Cardiovasc Diagn* 1998; 45: 405.
8. Tsai K, Chang C, Lin P. Modified Blalock-Taussig shunt: statistical analysis of potential factors influencing shunt outcome. *J Cardiovasc Surg* 1996; 37: 149-52.
9. Marks LA, Metha AV, Marangi D. Percutaneous transluminal balloon angioplasty of stenotic standard Blalock-Taussig shunts: Effect on choice of initial palliation in cyanotic congenital heart disease. *JACC* 1991; 18: 546-51.
10. Sivakumar K, Anil SR, Ravichandra M, Natarajan KU, Kamath P, Kumar RK. Emergency transcatheter balloon recanalization of acutely thrombosed modified Blalock-Taussig shunts. *Indian Heart J* 2001; 53: 743-8.