



## Reverse shoulder arthroplasty: Short to mid-term clinical and radiological results

✉ Mehmet Sah Sakci<sup>a,\*</sup>, ✉ Kadir Ertem<sup>b</sup>, ✉ Huseyin Utku Ozdes<sup>b</sup>, ✉ Ersen Turkmen<sup>c</sup>, ✉ Emre Ergen<sup>b</sup>, ✉ Ali Canbay<sup>d</sup>

<sup>a</sup>Kafkas University, Health Research and Application Hospital, Department of Orthopedics and Traumatology, Kars, Turkey

<sup>b</sup>Inonu University, Faculty of Medicine, Department of Orthopedics and Traumatology, Malatya, Turkey

<sup>c</sup>Ankara Polatli Duatepe State Hospital, Department of Orthopedics and Traumatology, Ankara, Turkey

<sup>d</sup>Elbistan State Hospital, Department of Orthopedics and Traumatology, Kahramanmaraş, Turkey

### Abstract

**Aim:** This paper aimed to review the early and midterm radiological and clinical findings of our patients who were treated surgically with reverse shoulder prosthesis via to rotator cuff arthroplasty.

**Materials and Methods:** A total of 22 patients (female: 14, male 8), with shoulder arthrosis due to cuff tears were treated with reverse shoulder prosthesis between 2015 and 2018 in our clinic. The mean age of the patients was detected as 69.4 years (65-93 years). The mean clinical follow-up was detected as 11 months (3-36 month). The patients were evaluated with Visual Analog Scale (VAS), Shoulder Constant Score, American Shoulder/Elbow Surgeons Shoulder Score (ASES) scores, preoperatively. In last outpatient visits, patients were evaluated with radiological views and range of motion, Shoulder Constant, VAS and ASES scores.

**Results:** The mean shoulder flexion, extension, and abduction was measured as 101°, 24°, and 97.9° respectively in the last polyclinic controls. The mean shoulder Constant scores were 30.8 preoperatively and 62.1 at follow-up (p=0.001). Preoperatively, the mean score of ASES was 31.6. And it was increased to 65.9 with the last follow-up (p = 0.001). The mean preoperative VAS scores were 7.42, and the mean postoperative mean were 2.8 (p = 0.001). Periprosthetic fracture developed intraoperatively in one patient who also had a dislocation occurred in the 2<sup>nd</sup> month postoperatively. In another patient, superficial infection occurred at the postoperative 3<sup>rd</sup> week. One patient died because of cardiac problems postoperatively and another one had a traumatic periprosthetic fracture at 5<sup>th</sup> month postoperatively.

**Conclusion:** While clinical presentation of patient is an advanced rotator cuff tear arthropathy, the application of reverse shoulder prosthesis is major surgical procedure. Also, with appropriate rehabilitation protocol, significant improvement in pain and function can be achieved.

### ARTICLE INFO

#### Keywords:

Reverse shoulder prosthesis  
Rotator cuff tear arthropathy  
Radiological results

Received: Oct 05, 2021

Accepted: Mar 01, 2022

Available Online: May XX, 2022

DOI:

[10.5455/annalsmedres.2021.09.544](https://doi.org/10.5455/annalsmedres.2021.09.544)



Copyright © 2022 The author(s) - Available online at [www.annalsmedres.org](http://www.annalsmedres.org). This is an Open Access article distributed under the terms of Creative Commons Attribution-NonCommercial-NoDerivatives 4.0 International License.

### Introduction

Surgical treatment of arthropathy with massive rotator cuff tear is one of difficult conditions in orthopedic clinical life [1, 2]. The arthropathy due to rotator cuff tear described by Neer with three components as: i) massive tears of rotator cuff; ii) degenerative features [basically in the superior of joint (i.e. glenoid and humeral erosions, articular chondral loss, subchondral humeral osteoporosis due to disuse, and humeral head collapse; lack of osteophytes)], and iii) superior humeral migration resulting in

“femoralization” of humeral head and “acetabularization” (in coracoacromial arch) [3]. Treatment options of this disease can be ordered conservative and surgical (arthroscopic debridement, hemiarthroplasty, arthrodesis and resection arthroplasty) [4,5,6]. Since hemiarthroplasty and total shoulder prosthesis do not change the center of rotation, it relieves the pain and functional outcomes [7]. Initially it was designed in the 1970s. It was developed by Paul Grammont in the 1980s. The reverse prosthesis extends the moment arm of the deltoid muscle with shifting the shoulder rotation center to the medial and inferior. Thus, abduction and active forward flexion movement of the shoulder is provided by the deltoid muscle power [8].

\*Corresponding author:

Email address: [seyramaz72@gmail.com](mailto:seyramaz72@gmail.com) (✉ Mehmet Sah Sakci)

This reduces the mechanical torque on the prosthetic components and reduces the risk of loosening. When comparing to the total and partial shoulder prostheses, it has more stable design [9]. The reverse shoulder prosthesis was used for arthropathy due to cuff tear initially. And then it is also commonly used for shoulder arthroplasty revisions, tumor resection, and shoulder involvement in rheumatologic diseases, proximal humerus fractures, fracture sequelae and pseudoparalysis [9, 11]. In young patients without arthropathy, tendon transfer is recommended for massive rotator cuff tears. Reverse shoulder prosthesis is recommended in cases of unrepairable massive rotator cuff tears and pseudoparalysis in elder ages (over 65 years of age) [2, 11].

Many factors affects the results of the reverse prosthesis such as surgeon's experience, surgical technique, correct indication, patient and implant characteristics and postoperative rehabilitation. We aimed to review the functional and radiological results of reverse shoulder prosthesis used for cuff tear arthropathy.

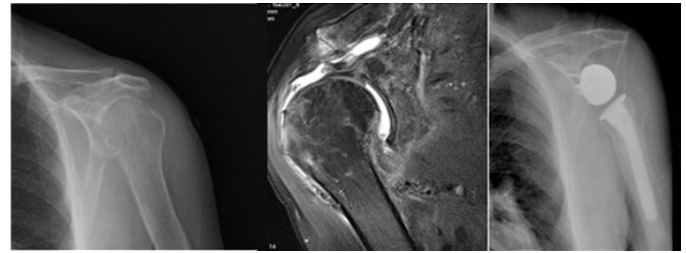
## Materials and Methods

Patients with arthropathy due to rotator cuff tear were detected in our clinic between 2015 and 2018. The inclusion criteria were: i) being over 65-years old, ii) patients with rotator cuff arthropathy, iii) patients with uncontrolled pain for the last 6 months, although history with conservative treatment with physical therapy. The exclusion criteria were: i) being under 65 years old, ii) patients without cuff arthropathy, iii) patients without the anamnesis of conservative treatment with physical therapy, iv) patients which have no pain claims, and function loss.

The dominant hand was the right side in 18 patients, and 4 left side. In the patients group, the surgery was applied in 8 left and 14 right hands. In all patients, the diagnosis was detected as arthropathy due to tear of rotator cuff. According to the anamnesis of the patients, open reduction internal fixation (ORIF) surgery history exist due to a proximal fracture of the humerus. In the preoperative evaluation, standard shoulder anterior posterior (AP) oblique x-rays, Computed Tomography (CT), Magnetic Resonance Imaging (MRI) were taken. The classification of cuff-tear arthropathy in our patients was made according to Hamada et al classification [10]. Grades were found as 4 or 5 in all patients. All patients were evaluated with the mean in range of motion, x-rays, Visual Analog Scale (VAS), American Shoulder-Elbow Surgeons Shoulder Score (ASES), and Constant Shoulder Scores by questioning whether they want to be operated again with satisfaction status at their last follow up. These preoperative scores (VAS, ASES, Constant) were obtained by using the hospital information recording system.

### Analysis and ethics committee

Ethics protocol for our study was approved by the XXX University Medical Faculty Ethics Committee. Declaration of Helsinki was conducted in accordance with our study.



**Figure 1.** Postoperative plain x-ray of 72 years old male patient along with preoperative radiography and MRI.

### Surgical technique

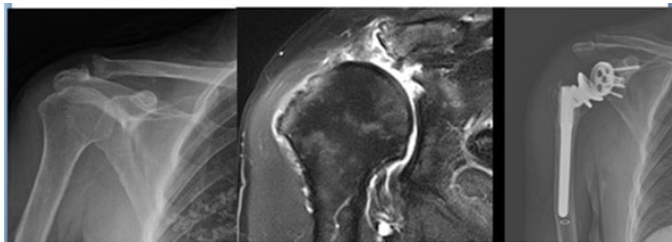
Under general anesthesia and on the beach chair position, deltopectoral incision was used in all patients. Implant-cast brand implant was used in 8 patients and FX brand implant was used in 14 patients. The subscapularis tendon was removed from the humerus insertion site without bone. In four patients, only the remaining muscle tissues were removed because the subscapular muscle was a full-thickness rupture. The cut into humeral head was made with special guiding system to create a 145 degree with the diaphysis. By temporarily placing the head protector in the humerus, fibrous residues around the glenoid were cleared and their borders were determined, especially the inferior. The guide wire was put at the bottom of the glenoid and sent 90 degrees perpendicular to the glenoid axis. The glenoid joint was prepared by removing superficial layers of subchondral bone with reamer. The metaglene was put as inferior as possible to the glenoid. The metaglene was fixed to the scapula with at least two locked, mostly three or four screws. The humeral diaphysis was carved with carvers. The metaphysis was prepared with rasps. The stem for humeral was cemented with a proper degree of retroversion at 20 degrees. The glenosphere is fixed to the component of metaglene with screw. The insert (sourced by polyethylene) was placed into the humeral stool. The humeral joint was reduced. The glenohumeral stability was controlled. When the shoulder in external rotation, the cut subscapularis tendon was repaired if it comes to its insertion site on the humerus, if it did not, it was not repaired so that it did not limit external rotation. The mean duration of physiotherapy was 6 (4-10) weeks. Passive exercises started at the first 4 weeks while active exercises started after sixth week.

### Statistics

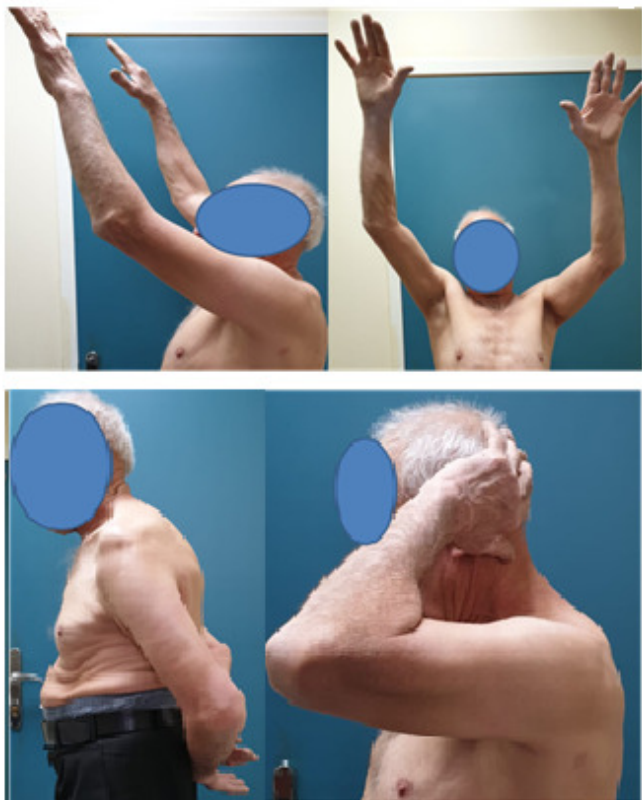The mean standard deviation values of the scores were taken. Wilcoxon signed-rank test was used to compare preoperative and postoperative VAS, Constant and ASES scores. Wilcoxon is a non-parametric test used to compare dependent variables. The p values under 0.05 was considered as significant.

## Results

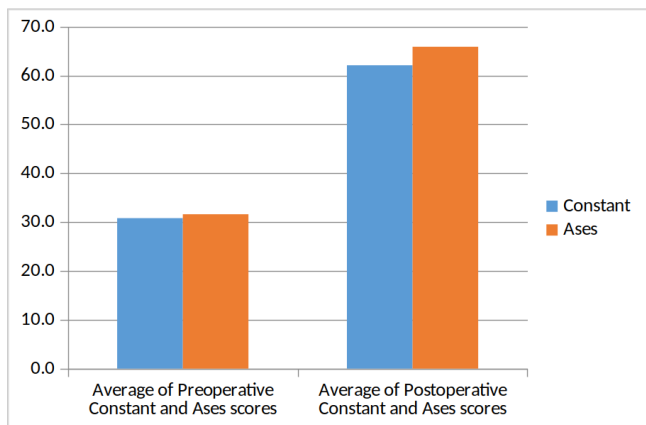
22 patients (female: 14, male: 8) were detected with arthropathy due to rotator cuff tear in our groups. The last polyclinic controls were associated with decreased pain and improvement in shoulder elevation. The mean shoulder Constant score was 30.8 preoperatively and 62.1 at



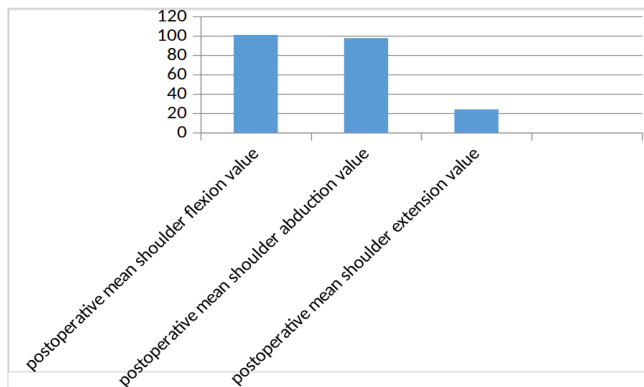
**Figure 2.** 62 y female patient with rheumatoid arthritis - preoperative x-ray and MRI along with postoperative radiography.



**Figure 3.** 76 y male patient - shoulder flexion, abduction, internal & external rotation amount at postoperative 9th month.



**Figure 4.** Average pre and post operative Constant and ASES scores.



**Figure 5.** Post-operative mean shoulder flexion, abduction extension values.

**Table 1.** Pre- and postoperative mean values of VAS, Constant, ASES scores.

Mean	VAS scores	Constant scores	ASESs
Preop	7.42	30.8	31.6
Postop	2.8	62.1	65.9
Statistics (p values)	p=0.001	p=0.001	p=0.001

latter follow-up (p=0.001) (Table 3). The mean score of ASES was 31.6 preoperatively and it was increased to 65.9 at latter follow-up (p=0.001) (Table 3). The mean post-operative flexion, extension and abduction were 101°, 24° and 97.9°, respectively (Table 1). Preoperatively, internal rotation degrees were at L5 and thigh level and increased to L2 level postoperatively. The mean preoperative VAS was 7.42, and 2.8 postoperatively (p=0.001) (Table 2). All functional scores were given Table 4.

When the radiological results were evaluated, it was seen that the humeral stems were placed in varus in two patients and in valgus in one patient. Scapular notching was not observed in any of the patients. Minimal osteolysis was detected around the stem in the proximal humerus in one patient. Postoperative periprosthetic fracture and dislocation was observed in same patient. Loosening around the humeral or glenoid component was not observed in any patient.

Fracture developed in one patient intraoperatively and at the 5<sup>th</sup> month in another patient postoperatively after a fall. Fissure line developed in the humerus in the patient who developed intraoperative fracture when the humerus was rasped. After placing 2 cerclage wires, the humeral stem was placed. Posttraumatic dislocation was observed at postoperative 2nd month in the same patient. Due to closed reduction failed, open reduction performed. And it was observed that the humeral stem was released from the cement and was mobile. Humeral stem revision was performed in this patient. In the postoperative 5<sup>th</sup> month, fracture was seen in the distal part of the humeral stem after falling and osteo-synthesis was achieved with ORIF. In one patient, an infection occurred at the postoperative 3<sup>rd</sup> week at the surgical incisions site. Under the con-



ditions of the operating room, it was observed that the infection was superficial and limited to the subcutaneous tissues for which washing and debridement was performed. The infection cleared up with antibiotic treatment. One patient died due to cardiac problems in the postoperative 5th month. None of the patients had neurological or vascular injury.

## Discussion

The reverse shoulder prosthesis can be recommended for older patients with pseudoparalysis and also massive tear of rotator cuff which is unrepairable [11]. Over time, reverse shoulder prosthesis have also started to be used in elderly complex humeral proximal end fractures, arthrosis after fracture, after tumor resection, rheumatic diseases and revision surgeries of primary operation [9].

Boileau et al reported that the reverse shoulder prosthesis applied to patients with unsuccessful cuff repair surgery showed improved functional outcomes [12]. Successful similar results have been reported in a number of series with follow-up for 4 years [12, 13]. Again, with the report of Guery et al the survival was established as 84% in 77 disease series with at least 5-years results [14]. Although superior results were reported with the reverse prosthesis in the arthropathy developed due to cuff tear, good results were emphasized in patients with massive tears of the cuff in pseudo-paralysis along with other indications such as fractures, revisions, and tumors [2, 12].

In this study, patients who developed arthropathy due to cuff tear as the etiologic diagnosis were selected and the reverse shoulder prosthesis applied showed good results in the early time. According to evaluation of the pain, function, and satisfaction levels of patients, there was a significant improvement, especially in ROM. This condition was associated with the elimination of the mechanical disability caused by shoulder arthrosis and with the removal of degenerated and painful tissues, which was related to normal functioning of the teres minor muscle and reduced pain. The difference between the mean of preoperative and postoperative VAS found to be statistically significant. Oliveira França et al. In the series of 22 cases, reported that preoperative VAS was found to be 7.64 compared to postoperative VAS which was found to be 2.06 [4].

The increase in the mean ASES score was 34.3 after surgery. This was statistically significant and was consistent with the literature. Oliveira França et al. found this difference as 43.1 in a series of 22 cases [4]. The increase in the mean postoperative Constant score of 31.3 points was statistically significant and was consistent with the literature. Ata Can A. et al. In their series of 14 patients, found that the mean Constant score after surgery 38.2 points higher than the mean constant score before surgery [18].

Although incisions such as deltopectoral, superolateral, anterosuperior are used in the literature, deltopectoral incisions are mostly preferred [11]. We preferred the deltopectoral approach in all patients because of the low probability of axillary nerve damage, good surgical field view, easier subscapular repair, and sufficient clinical experience. In some publications, complications such as glenoid loos-

ening, dislocation, glenoid notching, infection, periprosthetic fracture, neurological sequelae, fractures/hematomas of acromion were reported [2, 12, 13]. Complication rates were reported higher levels in reverse prosthesis series performed as revision surgery [15]. To prevent glenoid notching, it is recommended to use non-concentric glenosphere, and inserting the glenoid component as inferior as possible with a slight inferior tilt [16]. Taking these experiences into account, we put into the metaglene to the deep-inferior edge of the glenoid joint. Also, we put into the glenosphere component in some cases in most inferior part using the non-concentric glenosphere to prevent the connection of the humeral component with the inferior of the glenoid joint. In the series of Walch et al with 240 reverse shoulder prosthesis, emphasized that enhanced experience associated with decreased complication rates [14].

In our series, one superficial infection, one dislocation, one second surgery due to periprosthetic fracture were detected with the mean follow-up as 11 months. Due to the lack of long-term follow-up, scapular notching and prosthesis loosening may not have been observed. One of our patients died due to cardiac problems in the postop 5th month. Despite current problems and complications, 18 patients were satisfied with the condition and need to repeat the same operation in case of need while 4 patients were not satisfied with the condition and declared that they would not have the same operation again.

Flávio de Oliveira França et al. 22 reported that the satisfaction rate was 100% in their series of 22 cases [4]. Favaro et al. reported that only one patient did not want to have the same surgery in their 27 case series [17]. The patients underwent a rehabilitation program for an average of 6 weeks after the operation. Rehabilitation progressed faster after wound healing. It was thought that a slow rehabilitation would be more appropriate because the patients were in advanced age, the difficulty in adapting to rapid rehabilitation and increased risk of dislocation.

There were several limitations in this retrospective study that must be acknowledged. These were: the low number of patients, absence of long-term follow-up, and the inability to use the same model prosthesis in all patients.

The reverse shoulder prosthesis with proper technique can achieve significantly good results in patients with arthropathy due to rotator cuff tears who have pain and functional problems. In order to investigate the complications and functional outcomes in the long term, follow-up of our patients is continued.

## Ethical approval

Human research ethics approval was obtained from the local review board (Inonu University Scientific Research and Publication Ethics Committee) prior to the initiation of the study activities.

## References

1. Clement ND, Nie YX, McBirnie JM. Management of degenerative rotator cuff tears: a review and treatment strategy. *Sports Med Arthrosc Rehabil Ther Technol.* 2012; 4(1): 48.
2. Werner CM, Steinmann PA, Gilbert M, et al. Treatment of painful pseudoparesis due to irreparable rotator cuff dysfunction with the Delta III reverse-ball-and-socket total shoulder prosthesis. *J Bone Joint Surg Am* 2005; 87:1476-86.

3. Ecklund KJ, Lee TQ, Tibone J, Gupta R. Rotator cuff tear arthropathy. *J Am Acad Orthop Surg* 2007; 15: 340-349
4. França FO, Freitas JMA, Godinho PC, et al. Clinical and functional evaluation of patients submitted to reverse arthroplasty with minimum one year of follow-up. *Rev Bras Ortop.* 2018; 53(6): 714-720.
5. Eajazi A, Kussman S, LeBedis C, et al. Rotator Cuff Tear Arthropathy: Pathophysiology, Imaging Characteristics, and Treatment Options. *AJR Am J Roentgenol.* 2015; 205(5): W502-W511.
6. Sevimli R, Karakaplan M, Korkmaz MF, Gormeli G. Resection Arthroplasty in Shoulder Joint Tuberculosis: A Case Presentation. *Gavin J Case Rep* 2016; 1: 7-9.
7. Leung B, Horodyski M, Struk AM, et al. Functional outcome of hemiarthroplasty compared with reverse total shoulder arthroplasty in the treatment of rotator cuff tear arthropathy. *J Shoulder Elbow Surg* 2012; 21:319-23.
8. Hecker A, Aguirre J, Eichenberger U, et al. Deltoid muscle contribution to shoulder flexion and abduction strength: an experimental approach. *J Shoulder Elbow Surg.* 2021; 30(2): e60-e68.
9. Matsen FA 3rd, Boileau P, Walch G, et al. The reverse total shoulder arthroplasty. *J Bone Joint Surg Am* 2007; 89:660-7.
10. Brolin TJ, Updegrave GF, Horneff JG. Classifications in Brief: Hamada Classification of Massive Rotator Cuff Tears. *Clin Orthop Relat Res.* 2017; 475(11): 2819-2823.
11. Boileau P, Watkinson D, Hatzidakis AM, et al: The Grammont reverse shoulder prosthesis: results in cuff tear arthritis, fracture sequelae, and revision arthroplasty. *J Shoulder Elbow Surg* 2006; 15:527-40.
12. Boileau P, Gonzalez JF, Chuinard C, et al. Reverse total shoulder arthroplasty after failed rotator cuff surgery. *J Shoulder Elbow Surg* 2009; 18(4):600-6.
13. Sirveaux F, Favard L, Oudet D, et al. Grammont inverted total shoulder arthroplasty in the treatment of glenohumeral osteoarthritis with massive rupture of the cuff. Results of a multi-centre study of 80 shoulders. *J Bone Joint Surg Br.* 2004; 86(3): 388-95
14. Walch G, Bacle G, Lädermann A, et al. Do the indications, results, and complications of reverse shoulder arthroplasty change with surgeon's experience? *J Shoulder Elbow Surg* 2012; 21:14707.
15. Wall B, Nové-Josserand L, O'Connor DP, et al. Reverse total shoulder arthroplasty: a review of results according to etiology. *J Bone Joint Surg Am* 2007; 89:1476-85.
16. Mizuno N, Denard PJ, Raiss P, et al. The clinical and radiographical results of reverse total shoulder arthroplasty with eccentric glenosphere. *Int Orthop* 2012; 36:164753.
17. Fávoro RC, Abdulhad M, Filho SM, et al. Rotator cuff arthropathy: what functional results can be expected from reverse arthroplasty?. *Rev Bras Ortop.* 2015; 50(5): 523-9.
18. Atalar AC, Salduz A, Cil H, et al. Reverse shoulder arthroplasty: radiological and clinical short-term results. *Acta Orthop Traumatol Turc.* 2014; 48(1): 25-31.