



MRI clasification in developmental dysplasia of the hip with reference to soft tissue changes

Gelişimsel kalça displazisinde yumuşak doku değişiklikleri dikkate alınarak yapılan MRG sınıflaması

Ozhan Pazarcı¹, Okay Bulut¹, Seyran Kilinc¹, Umur Hatay Golge², Zekeriya Oztemur¹

¹Cumhuriyet University, School of Medicine, Department of Orthopaedics and Traumatology, Sivas, Turkey

²Çanakkale Onsekiz Mart University, School of Medicine, Department of Orthopaedics and Traumatology, Çanakkale, Turkey

Abstract

Objective: Purpose of the presented prospective study is to assess the pathological soft tissues together and examine their effect on the continuation of reduction in DDH cases treated with closed or open reduction by using MRI technique.

Materials and Methods: 46 hips of 34 cases treated between 2003 and 2012 were prospectively studied. MRI was performed on all children after reduction. Kashiwagi MRI classification was made according to the posterior acetabular rim on axial images at the level of triradiate cartilage. As different from Kashiwagi, the group of patients were divided two subgroups (2A and 2B) according to pathological soft tissue changes on MRI.

Results: 27 hips with sharp posterior acetabular rims were involved in Kashiwagi group 1. Sixteen hips with rounded and dysplastic posterior acetabular rims were involved in group 2. In these cases, 9 hips of 6 cases not diagnosed with pathological soft tissue changes obstructing reduction on MRI were included in group 2A. In addition to rounded posterior acetabular rims, 7 hips of 6 cases having at least one of the soft tissue changes such as pulvinar, transverse acetabular ligament, labrum and hypertrophy of ligamentum teres were involved in group 2B. Redislocation was observed after plaster cast in all cases in group 2B and open reduction and salter osteotomy were applied. Three hips with inverted labrum were involved in group 3.

Conclusion: Presented study provides more useful information on the course of treatment in cases where Kashiwagi's classification modification and closed/open reduction and immobilization were conducted by taking soft tissue factors obstructing reduction into consideration.

Key words: DDH, MRI, Kashiwagi, Hip.

Öz

Amaç: Sunulan prospektif çalışmanın amacı kapalı ya da açık redüksiyon yapılan GKD'li olgularda patolojik yumuşak doku değişikliklerinin; redüksiyonun devamı üzerine etkisinin MRG ile incelenmesidir.

Gereç ve Yöntemler: 2003 ve 2012 yılları arasında tedavi edilen 34 olgunun 46 kalça prospektif takip edildi. Redüksiyon sonrası tüm çocuklara MRG uygulandı. MRG sınıflaması (Kashiwagi) triradiat kırıldak düzeyindeki aksiyel kesitlerdeki posterior asetebular kenara göre yapıldı. Kashiwagi MRG sınıflamasından farklı olarak; Grup 2 MRG'deki patolojik yumuşak doku değişikliklerine göre iki alt gruba ayrıldı (2A ve 2B).

Bulgular: Keskin posterior asetebular rim bulunan 27 kalça grup 1 olarak değerlendirildi. Yuvarlak posterior asetebular kenar olan 16 hasta grup 2'de yer aldı. Bunlardan patolojik yumuşak doku değişikliği bulunmayan 6 olgunun 9 kalçası grup 2A'da yer aldı. Patolojik yumuşak doku değişikliklerinden en az biri bulunan 6 olgunun 7 kalçası grup 2B'de yer aldı. Inverte labrum bulunan 3 kalça grup 3'te yer aldı. Grup 2B ve 3 kalçalarda redüksiyon sonrası dislokasyon ve ek cerrahi işlem gereksinimi olduğu izlendi.

Sonuç: Kashiwaginın Pavlik bandajı ile redükte oluna bilirlilik hakkında bilgi veren MRG sınıflaması kapalı ya da açık redüksiyon yapılan daha ileri yaş olgularda da faydalıdır. Bu olgularda değerlendirmede redüksiyona engel yumuşak doku yapılarında dikkate alınmalıdır. Sınıflamanın bu modifikasyonu ile ileri yaş olgularda tedavi seyri açısından daha yararlı bilgiler verdiğini düşünmekteyiz.

Anahtar Kelimeler: GKD; MRG; Kashiwagi; Kalça.

Received/Başvuru: 08.03.2016
Accepted/Kabul: 11.05.2016

Correspondence/İletişim

Ozhan Pazarcı
Cumhuriyet University School of
Medicine, Department of
Orthopaedics and Traumatology,
Sivas, Turkey
E-mail: dr.pazarcigmail.com

For citing/Atıf için

Pazarcı O, Bulut O, Kilinc S, Hatay
GU, Oztemur Z. Mri clasification in
developmental dysplasia of the
hip; considering by soft tissue
changes. J Turgut Ozal Med Cent
2016;23(3):276-80.

INTRODUCTION

Developmental dysplasia of the hip (DDH) includes clinical conditions such as instability, subluxation and dislocation (1- 3). Physical examination and visualization form the basis of the diagnosis. The first treatment option is the Pavlik harness. However, reduction may not be achieved in all cases (4). If reduction cannot be achieved, closed or open post-reduction plaster cast immobilization is applied (5).

It is very important to maintain position of the femoral head in the plaster cast after reduction (6, 7). One should make sure that redislocation is not present after plaster cast application since acetabular development depends on the concentric reduction of the femoral head (6, 8).

Plain radiography, ultrasonography (US), arthrography, computed tomography (CT), and magnetic resonance

imaging (MRI) are used for imaging position of femoral head after reduction (8, 9, and 10). In addition to acetabular morphology, position of MRI femoral head also ensures the differentiation of soft tissue as a factor obstructing reduction (11). MRI is an effective method in evaluating the reduction (12- 14). Kashiwagi emphasized the importance of foreknowledge for the probability of reduction with the Pavlik harness and described a classification according to posterior acetabular rim in MRI (Table 1). He indicated through this classification that probability of reduction can be foreshadowed through the Pavlik harness (4). Purpose of the presented prospective study is to assess the pathological soft tissues together and examine their effect on the continuation of reduction in DDH cases treated with closed or open reduction through the classification made according to the posterior acetabular rim defined by Kashiwagi et al.

Table 1. Kashiwagi MRI classification

I.	Group	The acetabular rim is sharp, and the shape of the labrum and the acetabular cartilage is almost normal, although delayed ossification may frequently be seen.
II.	Group	The acetabular rim is rounded and dysplastic. The acetabular inlet is wide open.
III.	Group	The acetabular rim (the acetabular cartilage as well as the labrum) is inverted. The acetabular inlet is narrower than the diameter of the femoral head.

Table 2. All patients groups

Group 1		Group 2		Group 3	
Case	Side	2 A. No pathological soft tissue changes detected on MRI		Case	Side
		Case	Side		
2	L	8	B	1	R
3	B	12	B	19	L
4	B	16	R	20	B(R)
5	B	17	B		
7	L	22	L		
9	R	26	L		
10	R	2 B. Pathological soft tissue changes detected on MRI			
		Case	Side		
11	R	6	L		
13	L	20	B.(L)		
14	B	23	R		
15	R	25	B.		
18	R	29	L		
21	R	33	B.(L)		
24	R				
27	B				
28	L				
30	L				
31	B				
32	L				
33	B(R)				
34	L				

MATERIALS and METHODS

Having obtained the approval of the local ethics committee, 46 hips of 34 cases treated between 2003 and 2012 were prospectively studied. Patients were assessed for closed reduction under general anesthesia in the operating room. After performing the open reduction on 3 hips of 2 cases, which were not appropriate for closed reduction, and performing the closed reduction on others, the plaster casts were applied. Reduction affirmation was realized in the operating room through plain radiography. MRI was performed on all children after reduction. Images were obtained from a 1.5 T MRI device (Toshiba-Excelart, Tokyo-Japan). Sedation was not used on the others except for 3 cases. One of the parents accompanied their child during imaging. Average MRI period was 5.27 (min. 3.55 – max. 10.50) minutes. There were no images not evaluated due to movement-based artifacts. T1 and T2 weighted axial and coronal images were obtained at the 4 mm-thick sections. All images were evaluated by two senior orthopedic surgeons. Hip reduction was assessed on axial and coronal plans. Kashiwagi classification was made according to the posterior acetabular rim on axial images at the level of triradiate cartilage. Different from Kashiwagi, while Group 2 patients with no pathological soft tissue changes on MRI were included in sub-group A, those having these changes were included in sub-group B. DDH-related intra-articular and extra-articular pathological soft tissue changes were noted. Average duration of follow-up was 36.45 months (min. 9-max 128 months). Average MRI age was specified as 12.7 months (min. 5-max 24 months).

RESULTS

Twenty-seven hips with sharp posterior acetabular rims were involved in Kashiwagi group 1. Concentric reduction was achieved in these patients after closed reduction and plaster cast immobilization. No factors obstructing intra-articular reduction were observed in any cases on MRI.

Sixteen hips with rounded and dysplastic posterior acetabular rims were involved in group 2. In these cases, 9 hips of 6 cases not diagnosed with pathological soft tissue changes obstructing reduction on MRI were included in group 2A. When 3 hips of 2 cases in group 2A were found not to be appropriate for closed reduction, plaster cast immobilization was applied after open reduction. Recovery was enabled in group 2A without the need for any additional procedure. In addition to rounded posterior acetabular rims; 7 hips of 6 cases having at least one of the soft tissue changes such as pulvinar, transverse acetabular ligament, labrum and hypertrophy of ligamentum teres were involved in group 2B. Redislocation was observed after plaster cast in all cases in group 2B and open reduction and salter osteotomy were applied.

Three hips with inverted labrum were involved in group 3. Redislocation was determined within the plaster cast in case 1 and 20. Redislocation was observed after the plaster cast in case 19. Open reduction and salter osteotomy were applied on cases 19 and 20. Since the first treatment age is 6 months, closed reduction plaster cast immobilization was reapplied on case 1. Recovery was achieved afterwards without the need for surgical operation.

DISCUSSIONS

In our study, reduction was achieved in cases in group 1 in a similar way with Kashiwagi while reduction could not be obtained in cases in group 3 (Figure). As different from Kashiwagi, cases in group 2 were divided in groups A and B according to their intra-articular pathological soft tissue changes. Reduction was achieved in cases in group A who did not have intra-articular soft tissue changes, whereas redislocation was determined after applying plaster cast in cases in group B who had these changes.

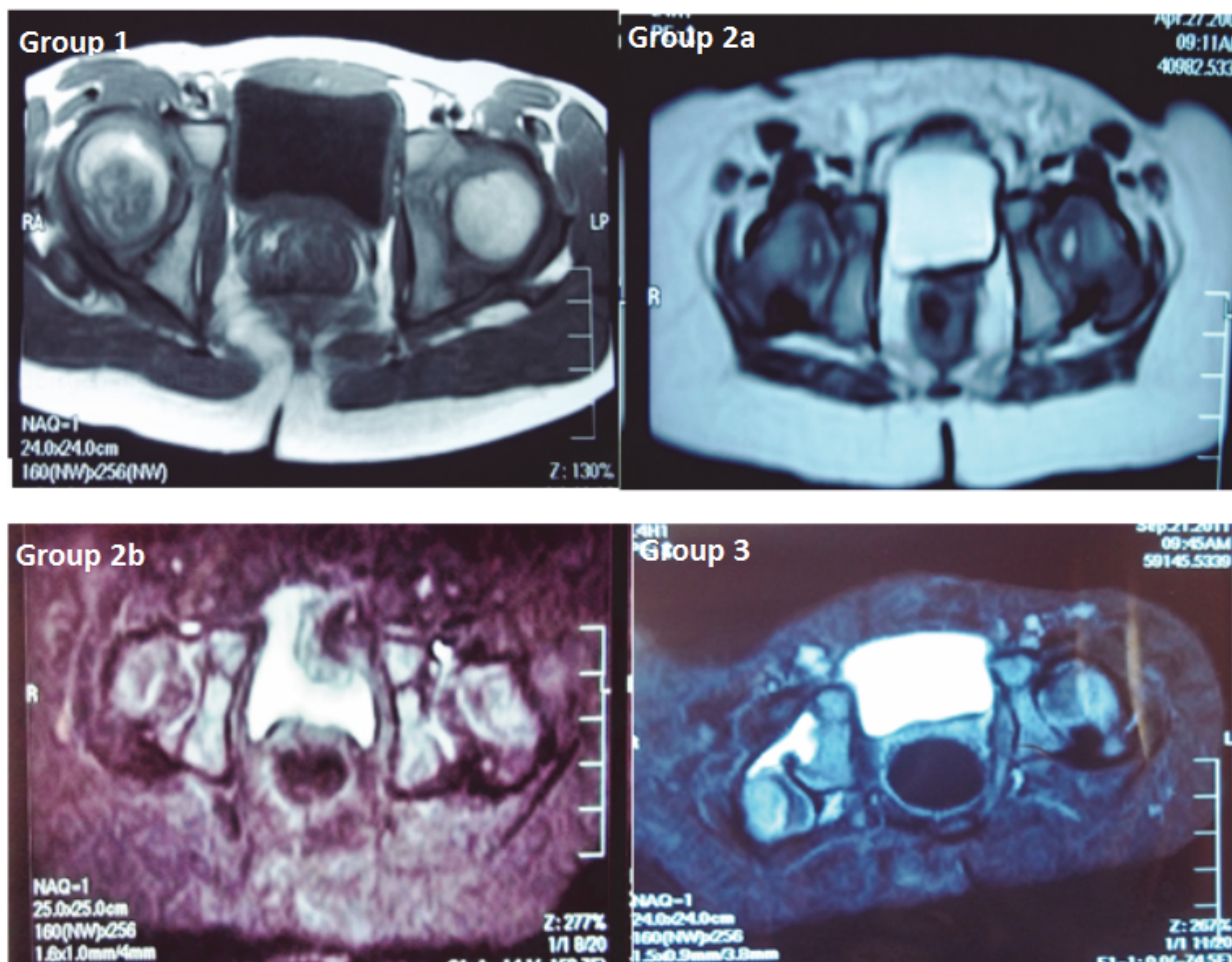


Figure. All patient groups (group 1, group 2a / 2b, group 3)

The first treatment method in DDH is Pavlik harness. If this method fails, open or closed post-reduction plaster cast immobilization is applied (5, 7). Normal acetabular development depends on the concentric reduction of the femoral head (8, 13, and 14). This is why it is important to ensure redislocation does not exist after applying plaster cast. In patients who were applied plaster cast after open or closed reduction, position of the femoral head may be ascertained with plain radiography, MRI, CT and US methods (10, 17). MRI defines infant hip anatomy completely and provides an outstanding soft tissue imaging (1, 8, 14- 16).

MRI is a method that does not contain ionized radiation and ensures a good soft tissue imaging (2, 4). However, many authors find MRI useful due to its long imaging time and requirement of sedation (2, 5, and 18). MRI is a practicable and reliable method for evaluations after reduction (3, 5, 6, and 8). Even if the femur head is seen in central position, it provides information if intra-articular structures will need additional reduction transaction (9). Inverted labrum, hypertrophic pulvinar, ligamentum teres and transverse acetabular ligament are factors obstructing intra-articular reduction (6, 8, 11, and 13).

Kashiwagi emphasized that anatomic details of the hip can be evaluated through MRI independently of femoral head position. He analyzed the posterior acetabular rim on sections taken from triradiate cartilage level in the T1 weighted axial sections and described a classification accordingly (4).

Kashiwagi et al. put emphasis on the soft tissue factors obstructing reduction in their studies. However they did not use them in their classification system (4). In addition to Kashiwagi classification in our study, we also used pathological soft tissue changes in classification as well as posterior acetabular rim (Table 1). Accordingly, we separated them into the sub-groups A and B according to presence of the pathological soft tissue changes in group 2. Recovery was achieved in patients, who received plaster cast immobilization after closed or open reduction in group 2A, without the need for any additional surgical operations. In cases in group 2B, in addition to the rounded or dysplastic posterior acetabular rim; there was at least one of the intra-articular pathological soft tissue changes such as pulvinar, transverse acetabular ligament, labrum and hypertrophy of ligamentum teres. In cases in group 2B, redislocation was observed after applying plaster cast and also open reduction and salter osteotomy were applied (Table 2).

Three hips with inverted posterior labrum were involved in group 3. While redislocation was observed within the plaster cast in case 1 and 20, redislocation was determined in case 19 after the plaster cast. Open reduction and salter osteotomy were applied on cases 19 and 20. Concentric reduction was achieved after closed reduction reapplied on 6-month-old case 1.

Kashiwagi et al. analyzed the hips through MRI according to Suzuki US classification (4). Accordingly,

they indicated that Suzuki type A and B hips in group 1 and group 2 were reduced with Pavlik harness whereas Suzuki type C hips in group 2 and group 3 could not be reduced with Pavlik harness (4). In our study, the average MRI age of patients was 12.7 months. US evaluation was not performed since the age of patients was advanced. It becomes difficult to assess US when ossific nucleus arises (9, 16). Qualities of US decrease after 4-6 months (11). Reduction affirmation was conducted through plain radiography at the operating room.

Consequently, Kashiwagi's MRI classification, providing information on the possibility of reduction through Pavlik harness, is also helpful in cases with closed or open reduction. We believe that the presented study provides more useful information on the course of treatment in cases where Kashiwagi's classification modification and closed/open reduction and immobilization were conducted by taking soft tissue factors obstructing reduction into consideration.

Conflicts of Interest and Source of Funding

The authors have no commercial or otherwise relation to any third party institutions or persons and they declare no conflict of interest.

REFERENCES

1. Fukiage K, Yamasaki N, Suzuki S. Visualization of developmental dysplasia of the hip in infants by using three-dimensional magnetic resonance imaging. *J Pediatr Orthop B* 2014;23(2):107-11.
2. Fukuda A, Miyati T, Maruki M, Tomoda Y, Futami T. Multiple-echodata image combination in infants with developmental dysplasia of the hip: comparison with conventional T1-weighted and T2-weighted imaging. *J Pediatr Orthop B* 2014;23(1):37-43.
3. Vandevienne JE, Lincoln T, ButtsPauly K, Rinsky L, Lang PK. Magnetic resonance imaging-guided closed reduction treatment for developmental dysplasia of the hip. *Singapore Med J* 2009;50 (4):407-11.
4. Kashiwagi N, Suzuki S, Kasahara Y, Seto Y. Prediction of reduction in developmental dysplasia of the hip by magnetic resonance imaging. *J Pediatr Orthop* 1996;16(2):254-8.
5. Gould SW, Grissom LE, Niedzielski A, Kecskemethy HH, Bowen JR, Harcke HT. Protocol for MRI of the hips after spicacast placement. *J Pediatr Orthop* 2012;32(5):504-9.
6. McNally EG, Tasker A, Benson MK. MRI after operative reduction for developmental dysplasia of the hip. *J Bone Joint Surg Br* 1997;79(5):724-6.
7. Chin MS, Betz BW, Halanski MA. Comparison of hip reduction using magnetic resonance imaging or computed tomography in hip dysplasia. *J Pediatr Orthop* 2011;31(5):525-9.
8. Desai AA, Martus JE, Schoenecker J, Kan JH. Spica MRI after closed reduction for developmental dysplasia of the hip. *Pediatr Radiol* 2011;41(4):525-9.
9. Bachy M, Thevenin-Lemoine C, Rogier A, Mary P, Ducou Le Pointe H, Vialle R. Utility of magnetic resonance imaging (MRI) after closed reduction of developmental dysplasia of the hip. *J Child Orthop* 2012;6(1):13-20.
10. Eberhardt O, Zieger M, Wirth T, Fernandez FF. [Determination of femoral head position with transinguinal ultrasound in DDH treatment]. *Z Orthop Unfall* 2009;147(6):727-33.

11. Atweh LA, Kan JH. Multimodality imaging of developmental dysplasia of the hip. *Pediatr Radiol* 2013;43 Suppl 1:S166-71.
12. Grissom L, Harcke HT, Thacker M. Imaging in the surgical management of developmental dislocation of the hip. *Clin Orthop Relat Res* 2008;466(4):791-801.
13. Westhoff B, Wild A, Seller K, Krauspe R. Magnetic resonance imaging after reduction for congenital dislocation of the hip. *ArchOrthopTraumaSurg* 2003;123(6):289-92.
14. Ranawat V, Rosendahl K, Jones D. MRI after operative reduction with femoral osteotomy in developmental dysplasia of the hip. *Pediatr Radiol* 2009;39(2):161-3.
15. Laor T, Roy DR, Mehlman CT. Limited magnetic resonance imaging examination after surgical reduction of developmental dysplasia of the hip. *J Pediatr Orthop* 2000;20(5):572-4.
16. Conroy E, Sproule J, Timlin M, McManus F. Axial STIR MRI: a faster method for confirming femoral head reduction in DDH. *J Child Orthop*. 2009;3(3):223-7.
17. Duffy CM, Taylor FN, Coleman L, Graham HK, Nattrass GR. Magnetic resonance imaging evaluation of surgical management in developmental dysplasia of the hip in childhood. *J Pediatr Orthop* 2002;22(1):92-100.
18. Omeroglu H. MRI after operative reduction for developmental dysplasia of the hip (letter). *J Bone Joint Surg Br* 1998;80:556.