



## Synchronous bilateral testicular seminoma: a rare case report Senkron bilateral testiküler seminom: nadir bir olgu sunumu

Caner Ediz<sup>1</sup>, Ayse Nur Ihvan<sup>2</sup>, Muzaffer Ilkay Tosun<sup>3</sup>

<sup>1</sup>Uskudar State Hospital, Department of Urology, Istanbul, Turkey

<sup>2</sup>Uskudar State Hospital, Department of Pathology, Istanbul, Turkey

<sup>3</sup>Umraniye Training and Research Hospital, Department of Pathology, Istanbul, Turkey

### Abstract

Testicular cancer represents 5% of urological tumours. Its incidence has been increasing during the last decades especially in the industrialised countries. Especially pure seminoma patients have been between 30 and 40 years old. At diagnosis, 1-2% of testicular tumors are bilateral. Radical orchiectomy is the gold standart for the treatment despite the performing of organ sparing surgery in selected cases for recent years. We present a case of bilateral synchronous testicular seminoma stage-IIIa in a 32-year old Turkish male who presented at our hospital with painless mass last one year. He underwent bilateral radical inguinal orchiectomy followed by four courses of BEP (bleomycin, etoposide, and cisplatin) chemotherapy. After the treatment, there was no recurrence or metastasis in a one-year follow-up.

**Keywords:** Seminoma; Testicular; Bilateral; Treatment.

### Öz

Testis tümörü üriner sistem maligniteleri arasında %5 oranında karşımıza çıkmaktadır. Son 10 yıl boyunca özellikle endüstriyel ülkelerde insidansı giderek artmaktadır. Özellikle saf seminom vakaları 30 ila 40 yaş arasında görülmektedir. Testis tümörleri tanı anında %1-2 oranında bilateral saptanmaktadır. Tedavisinde altın standart radikal orşiektomi olmasına rağmen son yıllarda organ koruyucu cerrahide seçilmiş vakalar uygulanmaktadır. Olgumuzda son bir yıldır ağrısız kitle ile kliniğimize başvuran 32 yaşında erkek hastada evre 3a bilateral senkron testikular seminomu sunuyoruz. Bilateral radikal inguinal orşiektomi sonrası hastaya 4 kür BEP (bleomisin, etoposid ve sisplatin) kemoterapisi verildi. Tedavi sonrası 1 yıllık takipte nüks ya da metastaz izlenmedi.

**Anahtar Kelimeler:** Seminom; Testis; Bilateral; Tedavi.

Received/Başvuru: 13.03.2016  
Accepted/Kabul: 10.04.2016

### Correspondence/İletişim

Caner Ediz  
Department of Urology, Uskudar  
State Hospital, Istanbul, Turkey  
E-mail:drcanerediz@hotmail.com

### For citing/Atıf için

Ediz C, Ihvan AN, Tosun MI.  
Synchronous bilateral testicular  
seminoma; a rare case report. J  
Turgut Ozal Med Cent  
2016;23(3):324-6.

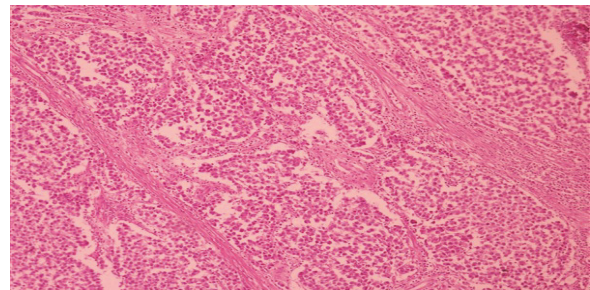
## INTRODUCTION

Testicular cancer accounts for 1% of all cancers in men. (1). It is observed most frequently between the ages of 20 and 30. 1-2% of the cases apply as synchronous bilateral at the time of diagnosis. It was reported that bilateral testicular tumors were observed less frequently in Asian countries compared to Western countries (2). Many factors such as presence of testicular tumor in the family or history of undescended testicle in patients, Klinefelter Syndrome and infertility increase the risk of testicular cancer development. Short arm of the 12<sup>th</sup> chromosome has been identified as a decisive factor in the development of tumors (3).

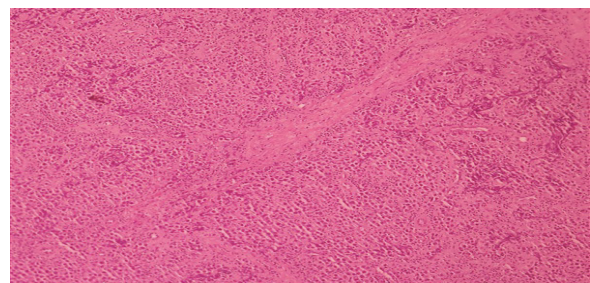
## CASE REPORT

A 32-year-old married male patient applied due to painless palpable mass in both testicles that he was aware of for a year. In his physical examination, there was a palpable mass of 5 cm with irregular borders at the inferior of the right testicle, and a palpable mass of 3 cm with relatively regular borders at the lateral of the left testicle. Supraclavicular lymph node was not detected. In laboratory analysis, hemogram values were normal. Serum LDH level was measured as 1352 (98-192) IU/L, hCG 18,92 (0-5) mIU/mL and AFP < 1 (0.5-5.5) ng/mL. In scrotal Doppler ultrasonography, the right testicle's size was highly increased and it was measured as 12x8.5x6 cm, while the left testicle was measured as 5x5x2.5 cm. Multiple lesions with heterogeneous inner structure that filled the right testicular parenchyma almost fully and distorted the parenchyma border, the largest of which with a size of about 45x44 mm, having partially intertwined borders and partially vascularized areas were observed. Although the left testicle's size was normal, a solid lesion of about 15x8 mm with partially vascularized areas was observed at the middle zone posterior. Both epididymis were normal. Bilateral radical and/or partial orchiectomy was planned as the patient was considered to have bilateral malign testicular tumor. The patient was recommended semen cryopreservation for assisted-reproduction technical treatments he might need in the future and pre-operatively a semen cryopreservation procedure was performed in an external center where assisted-reproduction technologies were applied. Later, under spinal anesthesia the patient was administered inguinal exploration and both testicles were evaluated intraoperatively. In the right testicle, a mass of about 8 cm and, in the left testicle, a mass of about 2 cm were detected. For histopathological evaluation, a frozen sample of 1x0.5x0.5 cm was taken from the right testicle and a 2x1x1 cm partial orchiectomy material was taken from the left testicle. In the histopathological examination of the frozen tissue samples, in the tissue of the right testicle IGONU (Intratubular Germ Cell Neoplasia, Unclassified) and in the tissue of the left testicle IGONU and surgical margins were found to be positive. In the light of histopathological evaluation, it was decided to apply bilateral orchiectomy to the patient. In the macroscopic examination of the both

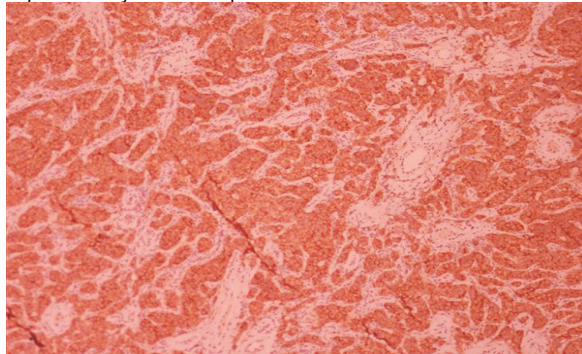
testicles, in the right testicles 8,5x6,2x4,5 cm tumor tissue and in the left testicles 5.5x5.5x2.5 cm tumor tissue and tissues containing hemorrhagic areas were detected. In the right testicle, 8.5x6.2x4.5 cm classic type of seminoma and intratubular germ cell neoplasia was present (Figure 1). Lymphovascular invasion was not detected. Tumor invasion was present in tunica albuginea. Rete testicle was observed to be intact. Tumor invasion towards spermatic cord fat tissue was present. In the left testicle, 1.2x1x1 cm classic type of seminoma and prevalent intratubular germ cell neoplasia was present (Figure 2). Lymphovascular invasion was not detected. Tunica albuginea and rete testicle were observed to be intact. In immunohistochemical examination, while CD 117 (Figure 3), D2-40, PLAP were determined positive, CD 30 and LCA were negative. For metastatic scan, contrast enhanced abdominal and thoracic computerized tomography was performed on the patient. Lymphadenopathy was not detected in para-aortic and retroperitoneal area. Nodular formations that might be consistent with low density lymphadenopathy, about 7 mm in diameter in the right lung basal posteromedial subpleural and about 4-5 mm in diameter in the right lung medial segment anterior subpleural, were observed. Bone structures within the examination area were intact. Additional imaging was not needed as suspicious bone lesions were not present. In the laboratory analyses in the post-operative 3<sup>rd</sup> week, serum LDH level was measured as 165 IU/L, hCG <1.2 mIU/mL and AFP < 1 ng/mL. According to IGCCCC (International Germ Cell Cancer Collaborative Group) classification, the patient was considered to have intermediate prognosis stage IIIA seminoma and 4 cures BEP (cisplatin, etoposide, bleomycin) were given. In the one-year follow-up of the patient, no recurrence or metastasis was detected.



**Figure 1.** The right testicle H&E x 100, the tumor consists of cavities and cord structures, rich with lymphocytes, separated by fibrous septa.



**Figure 2.** The left testicle H&E x 100, the tumor consists of cavities and cord structures, rich with lymphocytes, separated by fibrous septa.



**Figure 3.** IN tumor cells, CD117 x 100 positive (+) expression was observed.

## DISCUSSION

Testicular cancers usually appear to be derived from germ cells. Seminomas are observed more frequently especially in the 4<sup>th</sup> decade. History of undescended testicles and presence of tumor in the family are important factors in terms of tumor development (4). In our case, on the other hand, there wasn't any family history or history of undescended testicle. In hormonal analyses conducted, we detected negative AFP and high hCG suggest seminoma. In seminoma cases, while AFP does not rise, hCG value can rise by 30% (4). LDH, on the other hand, is a less specific tumor marker and is closely associated with tumor volume (5). However, it should be noted that the detection of a normal hormonal profile does not precisely eliminate presence of malignancy.

While testicular tumors are seen relatively rare among urologic malignancies, their synchronous or metachronous detection are much rarer. Gilbert and Hamilton published their bilateral germ cell tumors first in 1941 (6). 80-85% of bilateral testicle tumor cases occur as metachronously and 15-20% occurs synchronously (7). Especially in men of reproductive age, detection of such malignancies as bilateral at the time of diagnosis also affects treatment planning. The classical treatment of testicular tumors is radical orchiectomy. However, in recent years, testicle-preserving surgery has been in the forefront in the treatment of testicular cancers. Especially in young cases with have solitary testicle, synchronously detected bilateral testicular masses, normal testosterone levels and tumors inside testicle not exceeding 30% of the volume of the testicle, organ preserving surgery can be applied, considering need for long-term androgen treatment in the future, fertility concern and castration effects (4). Testicle-preserving surgery results are controversial in terms of 10.

its application, especially if contralateral testicle is normal, but it is an appropriate treatment for well tolerated and selected patients (8). In our case, primarily right radical orchiectomy and left partial orchiectomy was planned due to synchronous bilateral testicular tumor. Especially in young patients for whom fertility is planned, it should be noted that implementation of semen cryopreservation as a part of surgical planning is golden standard (9). Although partial orchiectomy is considered as surgery in such cases, it should also kept in mind that radical orchiectomy can be performed and semen cryopreservation should be included in fertility planning also in terms of radiotherapy and chemotherapy that will be applied in the postoperative period.

Testicular tumors remain as a malignancy that is seen in men of reproductive age and affect, albeit rarely, both testicles synchronously or metachronously. While testicle-preserving treatment can be applied to selected cases with its increasing popularity in recent years, radical orchiectomy maintains its popularity as the golden standard. However, being in close contact with the patient and doing planning in preoperative period in terms of fertility and castration are extremely important.

## REFERENCES

1. Shanmugalingam T, Soultati A, Chowdhury S. Global incidence and outcome of testicular cancer. *Clin Epidemiol* 2013;17;5:417-27.
2. Koppad SN, Sonawane SR, Kapoor VB. Bilateral synchronous spermatocytic seminoma: a rare case report from rural India and literature review. *Pan Afr Med J* 2012;13:34.
3. Korkola JE, Houldsworth J, Bosl GJ. Molecular events in germ cell tumours: linking chromosome-12 gain, acquisition of pluripotency and response to cisplatin. *BJU Int* 2009;104(9 Pt B):1334-8.
4. Albers P, Albrecht W, Algaba F. Guidelines on testicular cancer: 2015 Update. *Eur Urol* 2015;68(6):1054-68.
5. Peyret C. Tumeurs du testicule. Synthèse et recommandations en onco-urologie. Testicular tumours. Summary of onco-urological recommendations. *Prog Urol* 1993;2:60-4.
6. Gilbert JB, Hamilton JB. Studies in malignant tumor of the testis. IV. Bilateral testicular cancer. Incidence, nature, and bearing upon management of the patient with a single testicular cancer. *Cancer Res* 1942;21:125-9.
7. Detti B, Scocciati S, Cassani S. Synchronous bilateral testicular germ cell tumour: case report and review of the literature. *Klinicka Onkologie* 2013;26(4):281-5.
8. Djaladat H. Organ-sparing surgery for testicular tumours. *Curr Opin Urol* 2015;25(2):116-20.
9. Vakalopoulos I, Dimou P, Anagnostou I. Impact of cancer and cancer treatment on male fertility. *Hormones (Athens)*. 2015;14(4):579-89.