

Small Cell Lung Cancer Case Admitted with Brain Metastasis After Nine Years

Dokuz Yıl Sonra Beyin Metastazı Gelişen Küçük Hücreli Akciğer Kanseri Olgusu

Öztun Temelli¹, Cemal Ekici², Ayşenur Akatlı³

¹İnönü University, Faculty of Medicine, Department of Radiation Oncology, Malatya, Turkey

²İnönü University, Faculty of Medicine, Department of Medical Biology and Genetics, Malatya, Turkey

³İnönü University, Faculty of Medicine, Department of Medical Pathology, Malatya, Turkey

Dear Editor,

Causing the majority of deaths among cancer types, lung cancer is the most common cancer worldwide. It has been reported that 224,210 patients were newly diagnosed with lung cancer while 159,260 patients died of lung cancer only in 2014 in the United States. Approximately 15% of these patients had small cell lung cancer (1).

There are very few molecular genetic studies on small cell lung cancers. The discovery of cell surface receptors in recent years has especially strengthened the relationship between small cell lung cancer and genetics. Some of these genes are chemokine receptor-4 and chemokine ligand 12 (CXCR4/CXCL12), bombesin receptor, bradykinin receptor, vasopressin receptor, and fibroblast growth factor receptor (FGFR). In limited stage small cell lung cancer, median survival is 16-20 months. The most important factor affecting survival is the spread of disease. Patients have a high rate of developing brain metastasis. Brain metastasis usually develops within the first 2 years (2, 3).

A sixty-year-old male patient nine received curative chemoradiation due to small cell lung cancer 9 years ago (Figure 1). Having given complete response to chemoradiotherapy, the patient was offered prophylactic cranial irradiation but he rejected the treatment. The patient did not attend the follow-ups and, nine years after the treatment, he presented with patients complaints of headache, dizziness, and seizures. The computed tomography imaging showed multiple metastases: 2 in the left cerebellar region, 1 in the right cerebellar region, and 1 in the right posterior frontal region (Figure 2). The imaging also revealed multiple metastases in the liver and and recurrence in the lungs. We decided to implement palliative radiotherapy and systemic chemotherapy for the brain metastases.

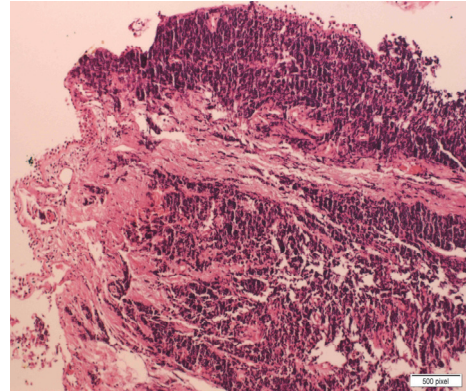


Figure 1. Atypical tumour cells with hyperchromatic nuclei and extended compression artifacts just under the respiratory tract epithelium (HE, 100X).

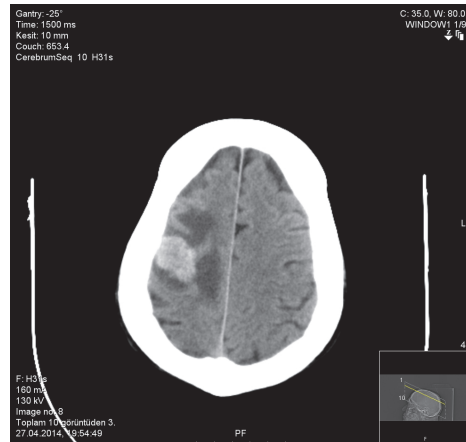

Figure 2. CT image of the patient developing brain metastases.

Lung cancers are divided into two groups: non-small cell cancers and small cell lung cancers. 15-20% of patients have small cell lung cancers. Brain metastases may

develop within the first 2 years by 45% in small cell lung cancers. In addition, in patients who have early complete response, practitioners perform prophylactic cranial radiotherapy since the 1970s because it reduces the risk of cranial recurrence while systemic chemotherapy alone can not cross the blood-brain barrier. With prophylactic cranial irradiation, prolonged survival has been achieved and, therefore, prophylactic cranial irradiation has eventually become a standard treatment method in patients giving a complete response throughout initial treatment (4, 5, 6). For patients who have brain metastases in early stages, systemic chemotherapy should accompany palliative cranial radiotherapy. Post-treatment survival is 6-7 months in patients with brain metastases. Radiation dose is usually 30 to 37.5 Gy (Gray) at a fraction of 10 to 15 (7, 8). The systemic chemotherapy treatment of our patient still continues.

REFERENCES

1. American Cancer Society: Cancer Facts and Figures 2014. Atlanta, Ga: American Cancer Society, 2014. Last accessed March 26, 2014.
2. Lassen U, Osterlind K, Hansen M, et al.: Long-term survival in small-cell lung cancer: posttreatment characteristics in patients surviving 5 to 18+ years--an analysis of 1,714 consecutive patients. *J Clin Oncol* 1995;13(5):1215-20.
3. Teicher BA. Targets in small cell lung cancer. *Biochem Pharmacol* 2014;15;87(2):211-9.
4. Hochstenbag MM, Twijnstra A, Wilmink JT, Wouters EF, ten Velde GP. Asymptomatic brain metastases (BM) in small cell lung cancer (SCLC): MR-imaging is useful at initial diagnosis. *J Neurooncol* 2000;48:243-8.
5. Arriagada R, Le Chevalier T, Borie F, Riviere A, Chomy P, Monnet I, et al. Prophylactic cranial irradiation for patients with small-cell lung cancer in complete remission. *J Natl Cancer Inst* 1995;87:183-90.
6. Auperin A, Arriagada R, Pignon JP, et al: Prophylactic cranial irradiation for patients with small-cell lung cancer in complete remission. Prophylactic Cranial Irradiation Overview Collaborative Group. *N Engl J Med* 1999;341:476-484.
7. Fry WA, Menck HR, Winchester DP: The National Cancer Data Base report on lung cancer. *Cancer* 1996;77 (9):1947-55.
8. Hochstenbag MM, Twijnstra A, Wilmink JT, Wouters EF, ten Velde GP. Asymptomatic brain metastases (BM) in small cell lung cancer (SCLC): MR-imaging is useful at initial diagnosis. *J Neurooncol* 2000;48:243-8.

Received/Başvuru: 08.10.2014, Accepted/Kabul: 20.10.2014

Correspondence/İletişim

Öztun TEMELLİ
İnönü Üniversitesi Tıp Fakültesi, Radyasyon Onkolojisi
Anabilim Dalı, MALATYA, TÜRKİYE
E-mail: droztun@gmail.com

For citing/Atf için

Temelli O, Ekici C, Akatli A. Nine years later admitted with brain metastasis of small cell lung cancer case. *J Turgut Ozal Med Cent* 2015;22:215-6 DOI: 10.7247/jtomc.2014.2417