



Intrathoracic Sewing Needle: An Unusual Penetrating Injury in Two Children

Sema Uguralp*, Birsen Harma*, Abdurrahman Karaman*

Inonu University Faculty of Medicine, Department of Pediatric Surgery, Malatya

Intrathoracic sewing needle was not reported in children. We present two cases with intrathoracic sewing needle due to their rarity and incidental presentation. Even though rare, foreign body penetration should be considered as a potential cause in addition to aspiration when a sharp foreign body is detected in child's thorax.

Key Words: Foreign Body, Sewing Needle, Thorax, Child

Toraksa Batmış İğne: İki Çocukta Sıradışı Penetran Yaralanma

Toraksa batmış iğne çocuklarda rapor edilmemiştir. Nadir rastlanmasından ve tesadüfen tanı konmasından dolayı toraksa batmış iğne tesbit ettiğimiz iki olguyu sunduk. Toraksta keskin yabancı cisim görüldüğünde yabancı cisim aspirasyonunun yanısıra iğne batması ile oluşan penetran yaralanmalar da akla getirilmelidir.

Anahtar Kelimeler: Yabancı Cisim, Batmış İğne, Toraks, Çocuk

INTRODUCTION

Manifestations of pediatric penetrating injuries by sewing needles are rare,¹ Intrathoracic sewing needle was reported only rarely in adults.^{2,3} Penetrating trauma can occur accidentally or intentionally. Most of those unusual injuries were described in the abdomen, cranium, heart or extremities.^{1,2,4-7} In this report, we present two cases of intrathoracic sewing needles. We encountered these cases during regular examinations and decided to present them due to their rarity. Patients had no history of foreign body (needle) penetration witnessed by the family.

CASE REPORTS

1st Patient: A 4-year-old male was admitted to the hospital with a complaint of cough that had been lasting for 3 days. Physical examination was normal. There was no wheezing. The patient had no history of foreign body aspiration. The postero-anterior thorax x-ray showed a needle at the location of the right lower hemithorax. The lateral x-ray mildly rotated and needle was found at the posterior side of thorax, superimposing vertebral column (Fig 1).

Therefore rigid bronchoscopy was performed. It did not reveal the foreign body. There were no fibrin-coated areas, purulence or inflammation. Three-dimensional computed tomography (CT) revealed that the needle was lying within intermuscular area on the 8th and 9th ribs. It was parallel to and near the vertebral column. It

was located at a 2 cm depth from skin. Needle localization was determined ultrasonographically. Repeated physical examination did not reveal any entrance site for the needle on the back, and the needle couldn't be palpated. No subcutaneous erythema or inflammation was detected.

The paravertebral incision was performed, and the needle was removed. The needle was rusty and surrounded by scar tissue, it split into two during the operation indicating that it must have been in the tissue for an extended period of time. The postoperative course was uneventful.

2nd Patient: A 4-year-old male was admitted to the hospital with fever that had been lasting for 2 days. Physical examination was normal.

The posteroanterior thorax x-ray revealed a huge needle at the horizontal location on the right upper hemithorax. Sharp tip of the needle lied between 6th and 7th ribs. There was no pneumothorax (Fig 2).

Repeated physical examination did not reveal any entrance site for the needle on the back, and the needle couldn't be palpated. There wasn't any subcutaneous erythema and inflammation. CT of the thorax has shown that the needle was within posterior-upper lobe of the right lung. The tip of the needle was under scapula (Fig 3).

Needle localization was determined scopically. During the operation the scapula was elevated, an abscessed pouch was located and aspirated. The sharp tip of the

Başvuru Tarihi: 28.10.2008, Kabul Tarihi: 06.07.2009

needle under the scapula was seized and the needle was pulled out of the lung parenchyma. The size of needle was approximately 10 cm. The postoperative course was uneventful.

DISCUSSION

The most frequent way for a sharp foreign body to reach into the thorax is aspiration and rarely by externally penetrating trauma. Foreign body aspiration is more common in male patients, mostly below five years of age. Choking is the most common symptom and decreased air entry on auscultation is the typical examination finding.⁸ The complications of foreign body in the thorax are pneumomediastinum, pneumothorax, abscess, atelectasia, pneumonia, bronchospasm, migration to the esophagus or mediastinum of foreign body. The treatment alternatives are rigid and flexible bronchoscopy, video-assisted thoracoscopy, thoracotomy. Penetrating injuries can arise from accidental or intentional causes such as physical abuse. Although, there is a group of child patients who were abused by adults with sewing needles inserted in to their body parts, by an infanticide attempt, most of these children presented with other findings of child abuse, such as bruises, abrasions, or burns.⁴ The mechanisms of injury in our cases are still uncertain. It is highly possible that the children were neglected and the needles penetrated accidentally. For example, the needles, potentially dropped by the mother, might have penetrated the thoraxes of children while crawling or playing on the ground. On the other hand, whether it became as a result of infanticide attempt or not is unclear, because there were no signs of penetration over the skin when the child was first seen. Since the needle was detected incidentally the penetration wound could potentially heal in the mean time. Upon admission to the hospital, neither child had any indications of child abuse on their body. In the first case the needle was parallel to the vertebra. In the other case, sharp tip of the needle was under the scapula. For

both cases, if the penetration was intentional, one would expect to find the sharp tip of the needle deeper within the tissue and perpendicular to the skin. The

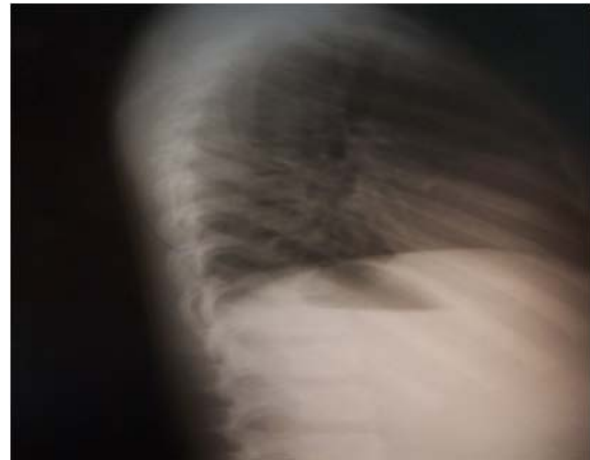

Fig 1B Lateral thoracic x-ray shows straight pin superimposing the vertebral column.

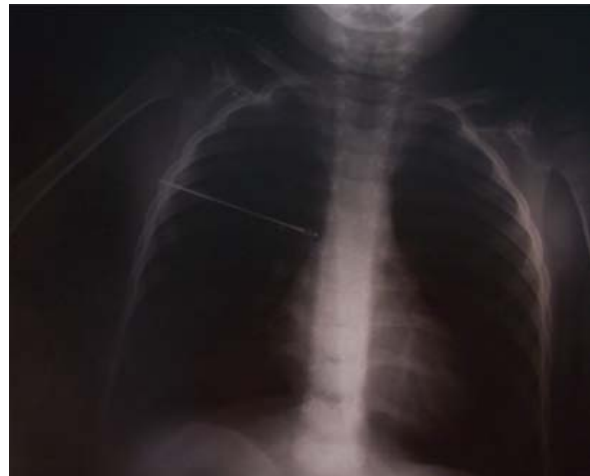

Fig 2 Plain thoracic x-ray shows straight pin in the second patient.

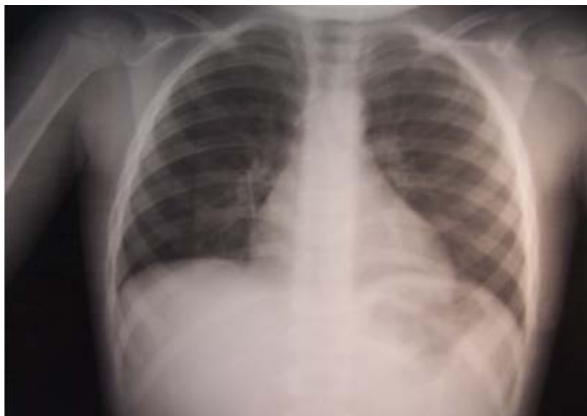

Fig 1A Plain thoracic x-ray shows straight pin in the first patient.

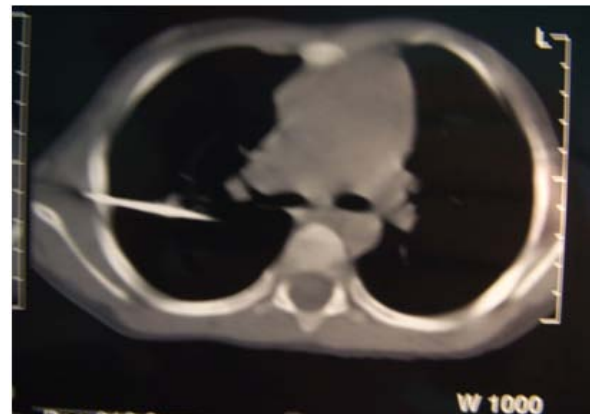


Fig 3 CT shows pin extending from under the scapula to the thoracic cavity in the second patient.

Intrathoracic Sewing Needle: An Unusual Penetrating Injury in Two Children

positions of needles suggest an external penetrating trauma rather than a child abuse.

For easy diagnosis and to avoid unnecessary invasive attempts (bronchoscopy), it should be kept in mind that the sharp foreign body can reach to the thorax with externally penetrating trauma. In our first case, CT was essential in determining the exact localization of the foreign body. Three-dimensional CT is a non-invasive technique that can detect the narrowing of the airway resulting from the presence of a foreign body.⁹

In both cases, sewing needles were removed by minimal open surgery. Thoracoscopy was not needed as the needle was lying on the ribs for the first case and the tip of the needle was extending outside the thoracic cage in the second case. For cases when the foreign body lies completely within the thoracic cage, thorascopic approach would be a preferred alternative to the classical open surgery.

Thoracoscopy yields better cosmetic results with less postoperative pain and reduced morbidity with.³ Open surgery must be saved for foreign bodies that couldn't be removed by thorascopic attempts. Removal of sharp foreign bodies is mandatory before migration into different organs to avoid complications. Several reports exist in the related literature regarding sewing needles penetrating the body parts or cavities.^{1,2-4,7} Yet, we didn't find any reports of intrathoracic foreign bodies in children. Even though rare, foreign body penetration should be considered as a potential cause in addition to aspiration when a sharp foreign body is detected in child's thorax.

REFERENCES

1. Balak N, Güçlü G, Karac I, Aksoy S. Intracranially retained sewing needle in a child: Does the rust on the needle have any implication? *Eur J Trauma Emerg Surg* 2008; 34: 159-62.
2. Otani Y, Ishikawa S, Kawata K, Ohtaki A, Yoshida I, Morishita Y. Surgical treatment of needles in intracardiac cavity and chest wall—a case report and review of cases removed under open-heart surgery in Japan. *Nippon Geka Gakkai Zasshi* 1994; 95: 790-3.
3. von Riedenauer WB, Baker MK, Brewer RJ. Video-assited thorascopic removal of migratory acupuncture needle causing pneumothorax. *Chest* 2007; 131, 899-901.
4. Lukefah JL, Angel CA, Hendrick EP, Torn SW. Child abuse by percutaneous insertion os sewing needles. *Clin Pediatr* 2001; 40: 461-3.
5. Unal N, Babayigit A, Karababa S, Yilmaz S. Asymptomatic intracranial sewing needle: an unsuccessful infanticide attempt ? *Pediatr Int* 2005; 47: 206-8.
6. Yalçın Ş, Karnak İ, Ciftci AO, Şenocak ME. An unusual penetrating injury in an infant: straight-pin migration from the back to the stomach. *J Pediatr Surg* 2006; 41: 1332-4.
7. Sola JE, Cateriano JH, Thompson WR, Neville HL. Pediatric penetrating cardiac injury from abuse: a case report. *Pediatr Surg Int* 2008; 24: 495-7.
8. Asif M, Shah SA, Khan F, Ghani R. Analysis of tracheobronchial foreign bodies with respect to sex, age, type and presentation. *J Ayub Med Coll Abbottabad* 2007; 19: 13-5.
9. Huang HJ, Fang HY, Chen HC, Wu CY, Cheng CY, Chang CL. Three-dimensional computed tomography for detection of tracheobronchial foeign body aspiration in children. *Pediatr Surg Int* 2008; 24: 157-60.

Corresponding Address: Dr. Sema UĞURALP
Department of Pediatric Surgery
Inonu University, Faculty of Medicine
44069 MALATYA, TURKEY.
Phone # +90 (422) 212 5202
Fax # +90 (422) 341 07 28,
E-mail: suguralp@inonu.edu.tr

