

Intracranial Arteriovenous Malformation Associated With Meningioma: An Unusual Case

Meningioma Eşlik Eden Arteriovenöz Malformasyon Olgusu; Nadir Bir Durum

SÜLEYMAN R. ÇAYLI, ÖMER SÖKMEN, TANGÜL BULUT

İnönü University School of Medicine, Department of Neurosurgery (SRÇ), Malatya Oncology Hospital, Departments of Neurosurgery (ÖS) and Pathology (TB) Ankara

Received : 5.7.2000 ⇔ Accepted : 24.8.2000

Abstract: It is rare to find a cerebral arteriovenous malformation and a primary brain tumor in the same patient. A literature search revealed only 33 such cases. We report the case of a patient with an arteriovenous malformation and a meningioma in the same cerebral hemisphere, and discuss the clinical and radiological findings.

Key words: Arteriovenous malformation, meningioma, primary brain tumor

Özet: Primer beyin tümörü ve arteriovenöz malformasyonların aynı anda bulunması oldukça nadir görülen bir durumdur. Literatür taramamızda toplam 33 olgu vardır. Aynı olguda saptanan meninjiom ve arteriovenöz malformasyon varlığı, klinik ve radyolojik bulgular ışığında tartışılmıştır.

Anahtar Kelimeler: Arteriovenöz malformasyon, meninjiom, primer beyin tümörü

INTRODUCTION

Arteriovenous malformations (AVMs) have been found in association with a variety of intracranial neoplasms. This simultaneous occurrence may be coincidental, but it may also reflect common origin. To our knowledge, only 10 cases of concurrent meningioma and intracranial AVM have been reported up to date. In three of these, the AVM and meningioma were located not adjacent to or mixed with each other, but were in separate regions of the brain (5,9,12). We report the case of a patient who had an AVM and a meningioma in distinct areas of the same cerebral hemisphere.

CASE REPORT

A 70-year-old man was hospitalized after he suffered a right-sided focal seizure and developed right-sided weakness. On admission the patient appeared to be in good condition. He was conscious, well oriented and demonstrated normal intelligence. His physical examination was unremarkable, as were the laboratory data. His neurological examination revealed papilledema, right hemiparesis and a positive Babinski's sign on the right. All cranial nerves were intact bilaterally.

Cerebral computerized tomography (CT) with contrast infusion demonstrated a large, homogeneously enhancing mass lesion in the left frontal parasagittal region (Figure 1). The lesion was spherical, appeared to be fixed to the falx cerebri, and was surrounded by extensive edema in the white matter. CT also demonstrated marked enhancement of the serpiginous vessels superficial to the mass in the left frontal region. T1-weighted magnetic resonance imaging (MRI) showed a left parasagittal extraaxial mass lesion with surrounding edema. The lesion was isointense with normal brain tissue, and contrast administration produced homogeneous enhancement (Figure 2). T1-weighted MRI in the sagittal plane showed multiple signal-void areas that created a tubular honeycomb appearance in the anterior region of the parasagittal tumor (Figure 3). A cerebral angiogram demonstrated a left frontal AVM that was supplied by the anterior cerebral artery (Figures 4 and 5). Selective internal carotid artery study did not highlight the frontal mass as a hypervascular mass with a homogeneous capillary blush, as would be expected in a typical meningioma.

We performed a left parasagittal craniotomy and found a mass with the typical appearance of a meningioma that was firmly attached to the falx cerebri and sagittal sinus. The margins of the tumor were clearly defined and the mass was not highly

vascularized. We totally excised the neoplasm, and histopathological examination confirmed that it was an atypical meningioma (Figure 6). The patient did well postsurgery and his right hemiparesis improved. He declined embolization or any surgical treatment for the AVM.

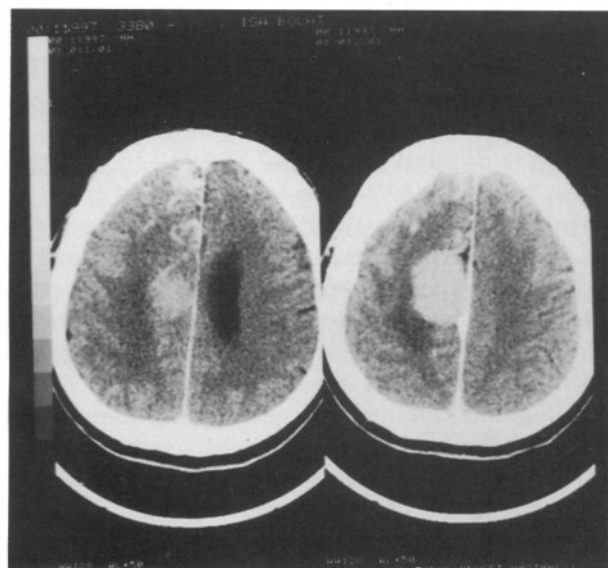

Figure 1: A CT scan with contrast injection shows homogeneous enhancement of the mass lesion and associated serpiginous vessels in the left frontal region.

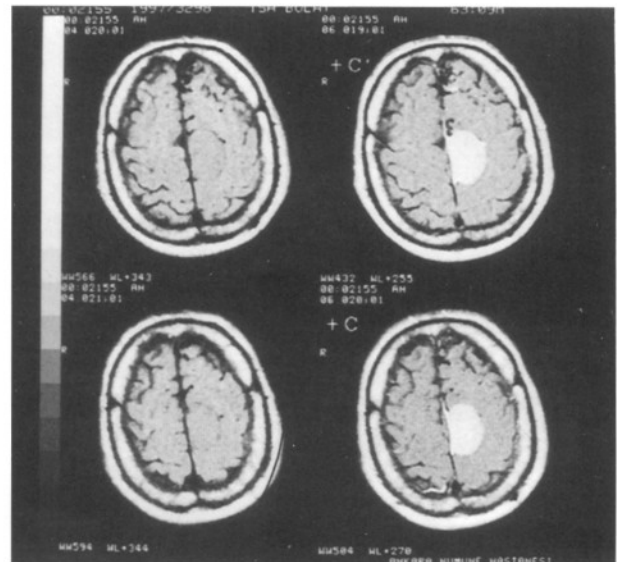


Figure 2: T1-weighted MRI shows a mass lesion in the left parasagittal region. Contrast administration resulted in homogeneous enhancement of the lesion.

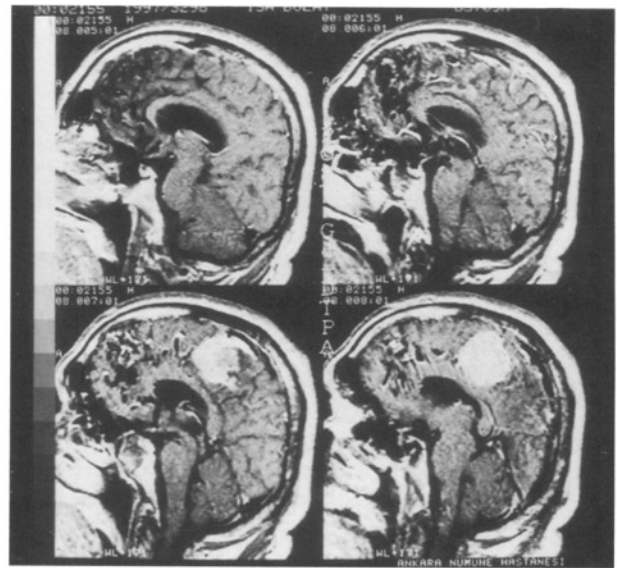


Figure 3: Sagittal MRI demonstrates multiple signal-void areas creating a tubular honeycomb pattern in front of the parasagittal tumor.

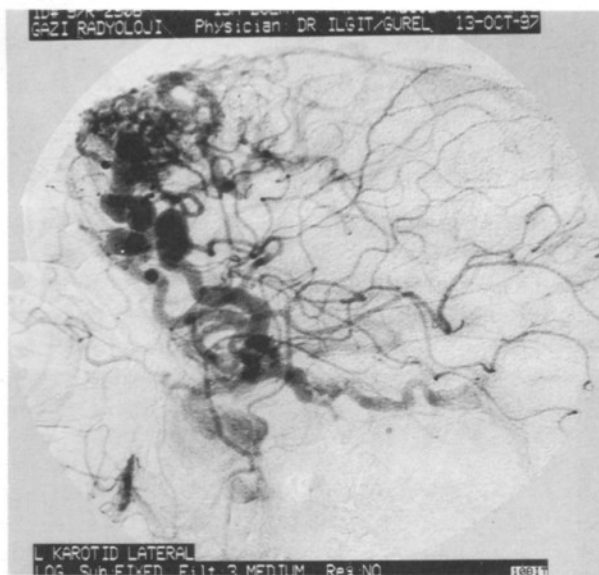
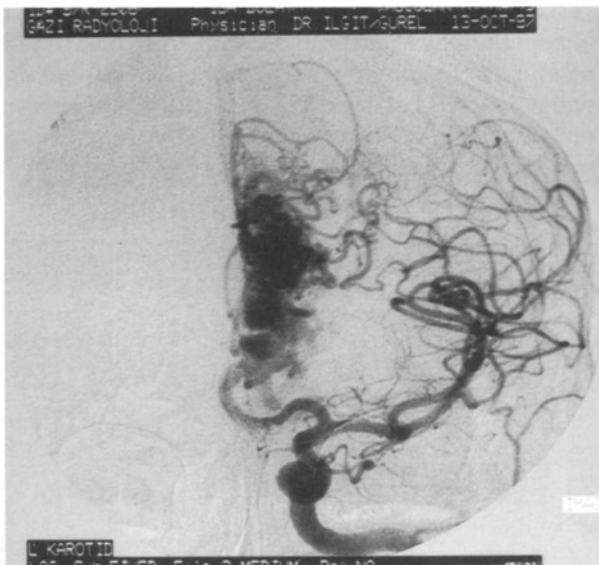


Figure 4-5: A carotid angiogram demonstrates an AVM fed by the anterior cerebral artery. The mass lesion in the parietal region does not appear to be highly vascularized.

DISCUSSION

The simultaneous occurrence of cerebral AVM and a primary brain tumor is rare. Currently, there is no agreement on why these two lesions would be found together. The most popular hypotheses are that AVMs induce tumor development, that tumors give rise to AVMs, and that both lesions develop due to a third common factor. It is true that certain humoral

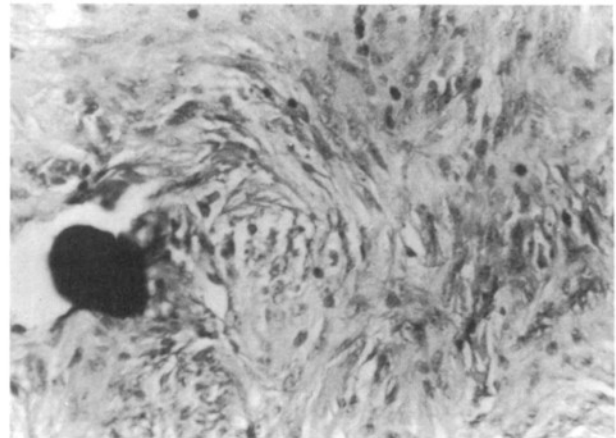


Figure 6: A photomicrograph shows an area of the meningioma containing psammoma bodies. (HEX10)

factors secreted by tumors could induce AVM as an acquired condition, and that any focus of chronic irritation on the arachnoid cells could cause a meningioma to develop (2,4,5).

Regarding the latter, the most likely source of chronic irritation of the arachnoid cells is scar tissue surrounding an AVM. This theory would explain the development of a meningioma adjacent to an AVM, or a mixed AVM-meningioma lesion. Indeed, in 7 of the 10 documented cases of concurrent meningioma and AVM, the tumors were either adjacent to or mixed with the AVM (1,3,6,7,8,10,11). In the other three cases, the AVM was located distant from the meningioma in the patient's brain. Reporting on one of these three individuals, Ohno et al. described an AVM and a meningioma located in different parts of the same hemisphere (9). In the other two cases, the lesions were found in separate hemispheres (5,12). Table 1 lists the specifics for the AVM-meningioma combination cases in the literature and for our case.

AVMs can produce symptoms at any time in the life of the affected individual. The most common signs are neurologic deficits due to hemorrhage. Our patient's symptoms of headache, right hemiparesis and right-sided focal epilepsy were caused by a parietal parasagittal meningioma in the left hemisphere. Once the tumor was removed, his

Table 1:

Case	Author	Age, sex	Meningioma location	AVM location	Relationship
1	Fine RD. et al	43 M	Right parietal	Right frontal	Adjacent
2	Kasantikul V. et al	15 M	Right frontal	Right frontal	Intermixed
3	Kasantikul V. et al	69 F	Right frontal	Right frontal	Intermixed
4	Bitoh S. et al	37 M	Right frontal	Right frontal	Adjacent
5	Sawamura Y. et al	68 M	Right occipital	Right occipital	Intermixed
6	Shida N. et al	65 F	Right sphenoid ridge	Right temporal	Adjacent
7	Kodoya C. et al	28 F	Right lateral ventricle	Right parietal	Adjacent
8	Soria E. et al	70 M	Left occipital	Right parietal	Separated
9	Ohno M. et al	67 F	Left frontal	Left parietal	Separated
10	Fukawa I. et al	56 M	Right parasagittal	Left parietal	Separated
11	Çaylı SR. et al	70 M	Left parietal	Left frontal	Separated

symptoms began to subside. This indicated that none of the clinical problems were associated with the AVM.

The optimal therapy for AVM remains controversial. The options are surgery, nonsurgical treatment with radiosurgery or embolization, or a combination of surgical and nonsurgical methods. As noted, our patient declined further treatment.

It is well known that meningiomas are vascular lesions that enhance homogeneously on contrast injection. Our patient's MRI and CT scans demonstrated homogeneous contrast enhancement of the tumor lesion, but carotid angiography showed no evidence of the hypervascularity or the homogeneous capillary blush typical of meningiomas. Angiography also confirmed that the AVM and meningioma were not vascularly connected. On the basis of our case and the other three reported cases of AVM and meningioma located distant from each other in the brain, we suggest that this is most likely a coincidental finding.

Correspondence: Dr. Süleyman R. Çaylı
Çöşnük mah. Mehmet Buyruk Cad.
Bayrak sitesi 5. Daire:3
Malatya/Türkiye
Tel: 90 422 3113067
Fax: 90 422 3410726

REFERENCES

1. Bitoh S, Hasegawa H, Kato A, Tamura K, Eiichiro M, Kobayashi Y: Meningeal neoplasms associated with cerebral vascular malformations. *Surg Neurol* 27; 469-475, 1987
2. Cushing H, Eisenhardt L: Meningiomas; their classification, regional behaviour, life history, and surgical end results. Springfield, Illinois; Charles C. Thomas, 1938, pp 785.
3. Fine RD, Gonski A: Cerebral tumor with intracranial angioma. *Med J Aust* 1; 227-230, 1976
4. Folkman J: Tumor angiogenesis. *Adv Cancer Res* 19; 331-358, 1974
5. Fukawa J, Tanata T, Takekawa: The association of intracranial meningioma with arteriovenous malformation and aneurysm. Report of a case. *No Shinkei Geka* 5; 175-180, 1997
6. Kadoya C, Kajiwara H, Soejima T, Yamada H, Matsuoka S: Arteriovenous malformation associated with meningioma. *Sangyo Ika Diagaku Zasshi*. 13; 35-38, 1991
7. Kasantikul V, Brown WJ: Meningioangiomas in the absence of von Recklinghausen's disease. *Surg Neurol* 15; 71-75, 1981
8. Kasantikul V, Brown WJ: Lipomatous meningioma associated with cerebral vascular malformation. *J Surg Oncol* 26; 35-39, 1984
9. Ohno M, Nagai H, Misawa I, Sugiyama N: A meningioma associated with AVM; a case report. *No Shinkei Geka* 5; 175-180, 1977
10. Sawamura Y, Janzer RC, Fankhauser H, Tribolet N: Arteriovenous malformation in meningiothelial meningioma; case report. *Neurosurgery* 29; 109-113, 1991
11. Shida N, Suzuki M, Mizoi K, Yoshimoto T: Ipsilateral coexistence of AVM and meningioma. *No Shinkei Geka* 23; 543-547, 1995
12. Soria E, Fine E, Hajdu I: Association of intracranial meningioma with arteriovenous malformation. *Surg Neurol* 34; 111-117, 1990