

Beneficial effects of hesperidin following cis-diamminedichloroplatinum-induced damage in heart of rats

H Oguzturk, O Ciftci¹, A Cetin², K Kaya³, OM Disli⁴, MG Turtay, S Gürbüz, N Basak⁵

Departments of Emergency Medicine, ¹Medical Pharmacology, ²Histology and Embryology and ⁴Cardiovascular Surgery, Faculty of Medicine, University of Inonu, ⁵Department of Pharmaceutical Toxicology, Faculty Pharmacy, University of Inonu, Malatya 44280, ³Department of Medical Biochemistry, Graduate Institute of Health Sciences, University of Inonu, Malatya, Turkey

Abstract

Background: Increased oxidative stress and histopathological damage have been implicated in the cardiotoxicity that limits the clinical therapy of cisplatin (CP) as an anti-cancer drug.

Objectives: This study aimed to investigate the protective effect of hesperidin (HP) against CP-induced cardiotoxicity in rats.

Materials and Methods: Rats were divided into four groups ($n = 7/\text{group}$), and the first group served as the control group. Animals in Group CP and Group CP + HP received a single dose of CP (CP - 7 mg/kg); animals in Group HP and Group CP + HP received 50 mg/kg/day HP with gavage for 14 days. At the end of day 14, cardiac tissue samples were histologically and biochemically examined.

Results: In this experimental study, thiobarbituric acid reactive substances levels in the cardiac tissue were significantly higher in the CP group, whereas glutathione (GSH), superoxide dismutase (SOD), and CAT levels were significantly lower in this group. On the other hand, GSH and SOD levels in the CP + HP group were similar to the control group. There was no significant difference in cardiac CAT levels between Group CP and Group CP + HP.

Conclusion: Hesperetin treatment leads to a decrease in oxidative stress, and associated histological damage. The findings of the current study suggest that HP has a protective effect against CP-induced cardiotoxicity.

Key words: Cardiotoxicity, cisplatin, hesperidin

Date of Acceptance: 03-Jul-2015

Introduction

Cisplatin (Cis-diamminedichloroplatinum [CP]) is a platinum-based anti-carcinogenic drug that is commonly

used in the treatment of solid tumors. The therapeutic effect of CP increases prominently with increasing dose.^[1] On the other hand, the clinical use of CP has been limited due to increased oxidative stress, and side effects (nephrotoxicity, cardiotoxicity) due to apoptosis.^[1,2] CP interacts with DNA, and forms intra- and inter-crosslinks. The resulting DNA damage initiates apoptosis.^[2]

Address for correspondence:

Dr. H Oguzturk,
Department of Emergency Medicine, Faculty of Medicine, University of Inonu, Malatya 44280, Turkey.
E-mail: oguzturk@hotmail.com

Access this article online

Quick Response Code:



Website: www.njcponline.com

DOI: 10.4103/1119-3077.173707

This is an open access article distributed under the terms of the Creative Commons Attribution-NonCommercial-ShareAlike 3.0 License, which allows others to remix, tweak, and build upon the work non-commercially, as long as the author is credited and the new creations are licensed under the identical terms.

For reprints contact: reprints@medknow.com

How to cite this article: Oguzturk H, Ciftci O, Cetin A, Kaya K, Disli OM, Turtay MG, *et al.* Beneficial effects of hesperidin following cis-diamminedichloroplatinum-induced damage in heart of rats. *Niger J Clin Pract* 2016;19:99-103.

Cardiotoxicity of the treatment in oncology usually limits its benefits. To date, cardiotoxicity has not received much attention, as it has not been considered as a dose-limiting factor for CP; however, recent studies have reported that CP treatment leads to significant cardiotoxic effects.^[1-5] During the development of CP-dependent cardiotoxicity, mild symptoms as well as severe symptoms (congestive heart failure, pericarditis, and cardiomyopathy) can be observed.^[3-5] Oxidative stress plays an important role in the pathophysiology of CP cardiotoxicity.^[4,5] The CP superoxide ion can produce active oxygen species, such as hydroxyl radicals, and can inhibit active antioxidant enzymes in normal tissues.^[6] Therefore, various antioxidants including ginger extract, propionyl-L-carnitine, DL-lipoic acid, and thiamine pyrophosphate have been tested to prevent CP cardiotoxicity.^[2,4,5,7] On the other hand, there are no studies on the efficacy of hesperidin (HP) against CP-dependent cardiotoxicity. HP (3',5,7-trihydroxy-4'-methoxyflavanone 7-rhamnoglucoside) is a flavonoid glycoside that is found in orange and lemon cultivars, and has antioxidant properties.^[8] This flavonoid has anti-inflammatory, anti-microbial, anti-carcinogenic, anti-oxidant effects, and strengthens capillaries.^[8,9] Thus, the aim of the current study was to analyze the biochemical and histological effects of HP against CP-induced cardiotoxicity and resulting oxidative stress.

Materials and Methods

Chemicals

CP (10 mg/10 ml, code 1876A) was obtained from Faulding Pharmaceuticals Plc (Warwickshire, UK). All other chemicals were purchased from Sigma Chemical Co. (St. Louis, MO) and were of analytical grade or of the highest grade available.

Animals and treatments

A total of 28 healthy adult male Sprague Dawley rats (aged between 2 and 3 months and weighing 250–300 g) were obtained from the Experimental Animal Institute, Malatya, Turkey, for this experiment. Animals were housed in sterilized polypropylene rat cages, in a 12 h light-dark cycle, at an ambient temperature of 21°C. Diet and water for them were given *ad libitum*. Experiments were performed based on animal ethics guidelines of the Institutional Animals Ethics Committee. Rats were randomly divided into four equal groups ($n = 7/\text{group}$). CP was intraperitoneally (i.p.) administered at the dose of 7 mg/kg with a single injection. HP was given in doses of 50 mg/kg/day for 14 consecutive days by gavages. Group 1 (control) served as the negative control and was administered isotonic saline (i.p.) and corn oil (orally) as vehicles. In Group 2 (CP group), CP was administered as a single injection and then the corn oil was given for 14 days. Rats in Group 3 (HP group) were treated with HP for 14 days without CP. In Group 4, the

rats were treated with CP and HP (i.e. CP + HP group) together. Tissue samples were collected on day 14 of CP treatment. The animals were killed under ether anesthesia and tissues (heart) were immediately removed and dissected over the ice-cold glass. Tissue samples were stored at 86°C in a deep freezer until analysis.

Biochemical assay

The homogenization of tissues was carried out in a Teflon glass homogenizer with 150 mM KCl (pH 7.4) to obtain a 1:10 (w/v) dilution of the whole homogenate. The homogenates were centrifuged at $18,000 \times g$ (4°C) for 30 min to determine thiobarbituric acid reactive substances (TBARS), reduced glutathione (GSH) levels, and catalase (CAT) activities, and at $25,000 \times g$ for 50 min, to determine Cu Zn-superoxide dismutase (SOD) activities.

The levels of homogenized tissue TBARS, as an index of lipid peroxidation, were determined by a thiobarbituric acid reaction using the method of Yagi.^[10] The product was evaluated spectrophotometrically at 532 nm, and results are expressed as nmol/g tissue. The GSH content of the testis homogenate was measured at 412 nm using the method of Sedlak and Lindsay.^[11] The GSH level was expressed as nmol/ml. SOD activity was measured by the inhibition of nitro blue tetrazolium (NBT) reduction due to O_2^- generated by the xanthine/xanthine oxidase system.^[12] One unit of SOD activity was defined as the amount of protein causing 50% inhibition in the NBT reduction rate. The product was evaluated spectrophotometrically at 560 nm. Results were expressed as IU/mg protein. CAT activity of the tissues was determined according to the method of Aebi.^[13] The enzymatic decomposition of H_2O_2 was followed directly by the decrease in absorbance at 240 nm. The difference in absorbance per unit time was used as a measure of CAT activity. The enzyme activities are given in k/mg protein. GPx activity was measured by the method of Paglia and Valentina.^[14] In the presence of GSH reductase and NADPH, the oxidized GSH is immediately converted to the reduced form with a concomitant oxidation of NADPH to NADP. The decrease in absorbance at 340 nm was measured. GPx activity is expressed as IU/mg protein. Tissue protein content was determined according to the method developed by Lowry *et al.*^[15] using bovine serum albumin as the standard.

Histological evaluation

For the light microscopic evaluation, heart samples were fixed in 10% formalin. The heart samples were processed by routine tissue techniques and were embedded in paraffin. Paraffin-embedded specimens were cut into 5 mm thick sections, mounted on slides, and stained with hematoxylin and eosin. Sections examined under a Leica DFC280 light microscope by Leica Q Win and Image Analysis System (Leica Micros Imaging Solutions Ltd., Cambridge, U.K).

An overall score of cardiac damage severity was semi-quantitatively assessed as follows: Eosinophilic stained and pyknotic nuclei cells, congestion, and necrosis. The microscopic score of each tissue was calculated as the sum of the scores given to each criterion. Scores were given as: 0 - none; 1 - mild; 2 - moderate; and 3 - severe for each criterion.

Statistical analysis was performed using SPSS 13 (SPSS Inc. Chicago IL, USA) and MedCalc software MedCalc Software, (Acaciaaan Ostend, Belçika). All groups were compared by the nonparametric Kruskal–Wallis test. Exact *P* values were given where available, and *P* = 0.0002 was accepted as statistically significant. All results were expressed as mean ± standard deviation.

Results

Histological results

In the control [Figure 1a] and HP groups [Figure 1b], heart tissues showed normal histological appearance. In the CP group, eosinophilic stained and pyknotic nuclei cells, hemorrhage, and degeneration were detected [Figure 2a and b]. On the other hand, these histological changes were partially decreased with HP treatment, and the therapeutic effects of HP were seen in the histological examination. Moreover, it was detected that the necrotic field [Figure 2c] in cardiac tissue had a significant appearance compared to control and other experimental groups. However, these changes were not seen in other treatment groups (HP and CP + HP groups) and HP treatments prevented these effects of CP in CP + HP groups. On the other hand, cardiac damage decreased in the CP + HP group. Cardiac damage was not completely ameliorated in the CP + HP group [Figure 3a and b]. Histopathological scores are shown in Table 1.

Biochemical results

As shown in Table 2, the results of the current study revealed that use of CP resulted in a significant increase in heart tissue TBARS level. In addition, the administration of HP with CP diminished the CP-induced increase in the

TBARS level in heart tissue. The current study showed that in CP + HP group significantly increased the SOD, GSH levels in heart tissue, compared to the CP group.

As seen in Table 2, CP treatment led to a marked increase in TBARS level in the cardiac tissue compared to other groups. However, CP treatment led to a significant decrease in SOD, GSH, and CAT levels. There was no significant difference in TBARS and CAT levels between the HP group and the control group, whereas GSH and SOD levels were markedly higher in the HP group. In addition, when the CP + HP group was compared to the control group, changes that were caused by CP treatment were closer to the control group, and except for CAT levels, the effects of CP were attenuated.

Table 1: Histopathological scores of groups

Groups	Histopathological scores (mean ± SE)
Control	1.00 ± 0.22 ^a
CP	4.71 ± 0.47 ^b
CP+HP	2.29 ± 0.36 ^c
HP	1.29 ± 0.29 ^a

The mean differences between the values bearing different superscript letters within the same column are statistically significant. (a, b and c: *P*=0.0002). SE=Standard error; CP=Cisplatin; HP=Hesperidin

Table 2: The levels of SOD, CAT, GSH, and TBARS in rat heart tissue (n=7, mean ± SD)

	TBARS nmol/g tissue	GSH nmol/ml	SOD IU/mg protein	CAT k/mg protein
Control	7.40 ± 0.96 ^a	84.0 ± 2.78 ^a	6.97 ± 0.38 ^a	0.064 ± 0.004 ^a
CP	14.5 ± 2.06 ^b	70.4 ± 2.68 ^b	5.69 ± 0.68 ^b	0.049 ± 0.005 ^b
HP	8.88 ± 1.28 ^{ac}	96.9 ± 6.18 ^c	8.58 ± 0.91 ^c	0.064 ± 0.007 ^a
CP+HP	10.2 ± 1.20 ^c	80.5 ± 1.88 ^a	7.03 ± 0.67 ^a	0.053 ± 0.006 ^b

Means bearing different superscripts within the same line were significantly (*P* ≤ 0.01) different. SD=Standard deviation; CP=Cisplatin; HP=Hesperidin; SOD=Superoxide dismutase; GSH=Glutathione; CAT=Catalase; TBARS=Thiobarbituric acid reactive substances

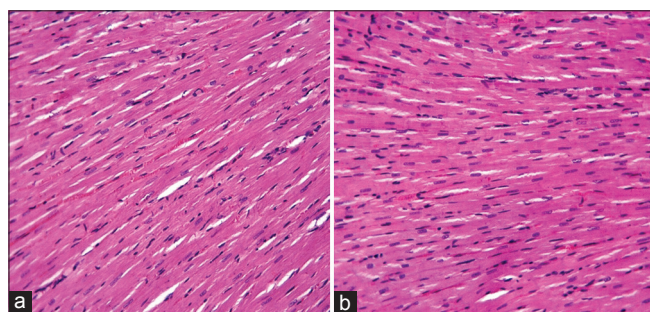


Figure 1: Control (a) and hesperidin (b) groups: Normal histological appearance of cardiac cells, H and E, ×20

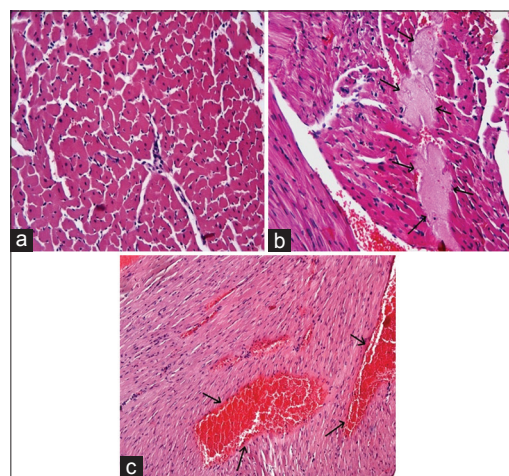


Figure 2: Cisplatin group: (a) Eosinophilic stained and pyknotic nuclei cells. (b) Hemorrhage (arrows) H and E, ×10. (c) Necrosis (arrows) H and E, ×20

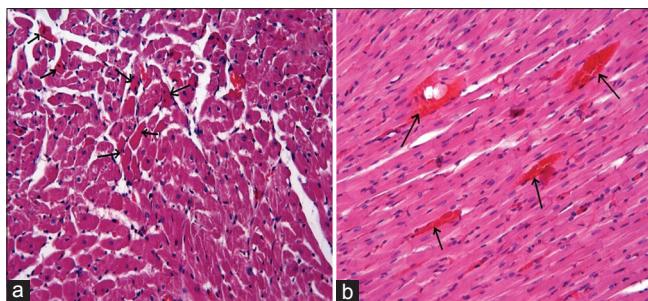


Figure 3: Cisplatin + hesperidin groups: (a) Eosinophilic stained and pyknotic nuclei cells (arrows). (b): Hemorrhage (arrows), H and E, $\times 20$

Discussion

Cardiotoxicity of the therapy in oncology often limits its benefits. Therefore, monitoring and early prevention of anti-carcinogenic treatment cardiac complications is of clinical interest. CP is used in the treatment of many solid tumors. Dose limitation due to side effects is one of the major problems in CP treatment. Therefore, various studies are conducted to reduce the side effects of CP, which is frequently used in chemotherapy. The current study analyzed the oxidative and histological damage in cardiac tissue that is caused by CP.

Oxidative stress can be defined as the imbalance between reactive oxygen species and the capacity of antioxidant defense systems. While the pathogenesis of CP-induced cardiotoxicity is not fully explained, the contribution of DNA damage due to oxidative stress is known. Previous studies support the current study, and it has been shown that CP leads to cardiotoxicity by inducing cardiac enzymes and histopathological lesions.^[2] Secondary to the CP-triggered lipid peroxidation in cardiac membranes, this damaging effect causes changes in TBARS, GSH, and SOD levels, activities of certain protective enzymes, and levels of antioxidant molecules.^[1,3-5]

The present study revealed that single dose CP treatment led to a marked increase in TBARS level in the cardiac tissue, and led to a significant decrease in SOD, CAT, and GSH levels. Due to its effects on oxidant and antioxidant systems, CP causes a significant level of oxidative stress in the cardiac tissue.

HP has attracted attention in recent studies, especially regarding its capacity to prevent the effects of free radicals, and its high antioxidant properties. Antioxidant molecules such as HP have protective effects against the oxidative damage caused by drugs and other damaging agents.^[16,17] The strong antioxidant activity of HP contributes to the prevention of various types of oxidative damage, toxicity, and other diseases.^[17]

The present study revealed that HP inhibited CP-induced oxidative damage by increasing SOD and GSH levels, and decreasing TBARS levels. These findings indicate the cardioprotective role of HP due to its antioxidant effect and are consistent with other studies indicating the protective effect of HP on the cardiovascular system.^[8,17]

The researchers of the present study did not observe a significant difference in GSH levels between the CP + HP group and the control group. However, compared to the CP group, GSH levels were significantly higher in Group 3 and Group 4. GSH is a nonenzymatic antioxidant, and is a key component of the antioxidant defense system. At the same time, GSH ensures protection of the membrane integrity.^[7] In the present study, high GSH levels in Group 3 and Group 4 are consistent with the previous studies indicating its cardioprotective features.^[3,7] In the present study, elevated GSH levels supported the membrane integrity in myocardial cells, and protected them from oxidative damage, thus, preventing various pathologies within the myocardium. Increased TBARS levels and decreased GSH levels in the cardiac tissue due to CP treatment support the notion that CP triggers oxidative damage that led to cardiac damage.

In addition, recent studies have focused on the protective effect of HP on the cardiovascular system.^[8] Deng *et al.* reported that HP inhibits pressure-dependent dysfunction and fibrosis, and cardiac hypertrophy, and decreases increased oxidative stress and apoptosis. According to the findings of the present study, HP protects heart muscle cells from damage, and attenuates cardiac damage and toxicity.

Previous studies have shown that CP inhibits cellular protein synthesis, and causes apoptosis after mitochondrial damage.^[18,19] CP also causes significant histopathological changes in heart tissue.^[1-5] According to the findings regarding the histopathological changes, CP, together with fibrous tissue reactions, causes degeneration and necrosis in cardiomyocytes. Massive degenerative changes have been reported in a study on the histopathological changes in the cardiac system that are caused by CP.^[1] The number of studies on this topic is limited, and the findings are consistent with the current study with regards to tissue damage criteria (e.g., necrosis, degeneration, and hemorrhage).^[1-3] This condition can be interpreted as the disruption of the balance between the oxidant system, which is induced by CP, and the antioxidant system. In addition, the present findings suggest that the combination of CP and HP decreases histopathological damage. These findings are consistent with the findings by Al-Majed *et al.*^[1]

Conclusion

HP treatment led to a decrease in oxidative stress and associated histological damage. The present findings indicate

that HP treatment supports a reduction in heart damage due to CP treatment. HP treatment led to biochemical and histological improvements in the heart tissue. HP treatment led to a decrease in TBARS levels in the cardiac tissue, and an increase in SOD and GSH levels. The current study represents the first study on the protective effect of HP against CP-induced cardiotoxicity. While the results indicate the protective effect of HP in CP-dependent cardiac damage, more comprehensive prospective studies are required. Future clinical studies will contribute to the potential clinical use of HP.

Financial support and sponsorship

Nil.

Conflicts of interest

There are no conflicts of interest.

References

1. Al-Majed AA, Sayed-Ahmed MM, Al-Yahya AA, Aleisa AM, Al-Rejaie SS, Al-Shabanah OA. Propionyl-L-carnitine prevents the progression of cisplatin-induced cardiomyopathy in a carnitine-depleted rat model. *Pharmacol Res* 2006;53:278-86.
2. Attyah AM, Ismail SH. Protective effect of ginger extract against cisplatin-induced hepatotoxicity and cardiotoxicity in rats. *Iraqi J Pharm Sci* 2012;21:27-33.
3. Hussein A, Ahmed AA, Shouman SA, Sharawy S. Ameliorating effect of DL- α -lipoic acid against cisplatin-induced nephrotoxicity and cardiotoxicity in experimental animals. *Drug Discov Ther* 2012;6:147-56.
4. El-Awady el-SE, Moustafa YM, Abo-Elmatty DM, Radwan A. Cisplatin-induced cardiotoxicity: Mechanisms and cardioprotective strategies. *Eur J Pharmacol* 2011;650:335-41.
5. Demkow U, Stelmaszczyk-Emmel A. Cardiotoxicity of cisplatin-based chemotherapy in advanced non-small cell lung cancer patients. *Respir Physiol Neurobiol* 2013;187:64-7.
6. Sadzuka Y, Shoji T, Takino Y. Effect of cisplatin on the activities of enzymes which protect against lipid peroxidation. *Biochem Pharmacol* 1992;43:1872-5.
7. Coskun R, Turan MI, Turan IS, Gulapoglu M. The protective effect of thiamine pyrophosphate, but not thiamine, against cardiotoxicity induced with cisplatin in rats. *Drug Chem Toxicol* 2014;37:290-4.
8. Deng W, Jiang D, Fang Y, Zhou H, Cheng Z, Lin Y, *et al.* Hesperetin protects against cardiac remodeling induced by pressure overload in mice. *J Mol Histol* 2013;44:575-85.
9. Garg A, Garg S, Zaneveld LJ, Singla AK. Chemistry and pharmacology of the Citrus bioflavonoid hesperidin. *Phytother Res* 2001;15:655-69.
10. Yagi K. Simple assay for the level of total lipid peroxides in serum or plasma. *Methods Mol Biol* 1998;108:101-6.
11. Sedlak J, Lindsay RH. Estimation of total, protein-bound, and nonprotein sulfhydryl groups in tissue with Ellman's reagent. *Anal Biochem* 1968;25:192-205.
12. Sun Y, Oberley LW, Li Y. A simple method for clinical assay of superoxide dismutase. *Clin Chem* 1988;34:497-500.
13. Aebi H. Catalase. In: Bergmeyer HU, editor. *Methods of Enzymatic Analysis*. New York: Academic Press; 1974. p. 673-7.
14. Paglia DE, Valentine WN. Studies on the quantitative and qualitative characterization of erythrocyte glutathione peroxidase. *J Lab Clin Med* 1967;70:158-69.
15. Lowry OH, Rosebrough NJ, Farr AL, Randall RJ. Protein measurement with the Folin phenol reagent. *J Biol Chem* 1951;193:265-75.
16. Menze ET, Tadros MG, Abdel-Tawab AM, Khalifa AE. Potential neuroprotective effects of hesperidin on 3-nitropropionic acid-induced neurotoxicity in rats. *Neurotoxicology* 2012;33:1265-75.
17. Trivedi PP, Kushwaha S, Tripathi DN, Jena GB. Cardioprotective effects of hesperetin against doxorubicin-induced oxidative stress and DNA damage in rat. *Cardiovasc Toxicol* 2011;11:215-25.
18. Jung M, Hotter G, Viñas JL, Sola A. Cisplatin upregulates mitochondrial nitric oxide synthase and peroxynitrite formation to promote renal injury. *Toxicol Appl Pharmacol* 2009;234:236-46.
19. Chirino YI, Pedraza-Chaverri J. Role of oxidative and nitrosative stress in cisplatin-induced nephrotoxicity. *Exp Toxicol Pathol* 2009;61:223-42.