

Anatomical and functional results of pars plana vitrectomy+ ILM peeling+ gas endotamponade in patients with idiopathic stage 4 macular hole

Seyhan Dikci¹, Soner Demirel¹, Ilknur Tuncer Firat¹, Turgut Yilmaz²

¹Inonu University, Faculty of Medicine, Department of Ophthalmology, Malatya, Turkey

²Medical Park Hospital, Department of Ophthalmology, Elazig, Turkey

Copyright © 2019 by authors and Annals of Medical Research Publishing Inc.

Abstract

Aim: To evaluate the anatomical and functional results in cases underwent 23-gauge pars plana vitrectomy (PPV) due to idiopathic stage 4 macular hole.

Material and Methods: 17 eyes of 17 patients who underwent PPV due to idiopathic stage 4 macular hole between March 2013 and March 2016 at İnönü University Turgut Özal Medical Center Department of Ophthalmology were included in the study. The medical records of the patients were retrospectively reviewed. Macular hole staging was performed according to biomicroscopic examination and optical coherence tomography findings. Anatomical success was evaluated according to the condition of the macular hole after the surgery and functional success was evaluated according to the visual acuity.

Results: 9 (53%) of the cases were females and 8 (47%) were males, the mean age was 66.6 ± 6.6 (55-81). PPV, internal limiting membrane (ILM) peeling and gas tamponade were applied to all cases. The mean follow-up period was 13.9 ± 9.7 (4-30) months. ILM peeling was performed using trypan blue in three (17.6%) of the cases, brilliant blue in 4 (23.5%) of the cases and membrane blue in 10 (58.8%) of the cases. Three cases (17.6%) were treated with C3F8 and 14 cases (82.3%) with SF6 gas tamponade. The mean preoperatively best-corrected visual acuity (BCVA) was 0.08 ± 0.06 (0.03-0.2) and the mean postoperatively BCVA was 0.16 ± 0.15 (0.03-0.5). Visual acuity did not change in two eyes (11.7%) and decreased in two eyes (11.7%). Macular hole had not closed in four patients (23.5%).

Conclusion: 23 gauge PPV, ILM peeling and C3F8 or SF6 gas tamponade provides anatomical and functional success in the treatment of idiopathic stage 4 macular hole.

Keywords: Internal limiting membrane; Macular hole; Pars plana vitrectomy.

INTRODUCTION

Macular hole is an interface pathology characterized by full-thickness retina loss at the center of the macula that results in complaints such as a decrease in central vision, metamorphopsia and central scotoma. Macular holes were considered untreatable until Kelly and Wendel obtained successful outcomes using vitrectomy, posterior hyaloid peeling, and intraocular gas tamponade (1,2). Gass explained for the first time the probable pathogenesis of idiopathic macular holes based on biomicroscopic findings and proposed that vitreous cortex remaining in the macula during spontaneous posterior vitreous detachment resulted in an eccentric tear on the macula (3). Following

the introduction of optic coherence tomography (OCT), researchers demonstrated the presence of vitreomacular adhesion, which was centered at the fovea, in stage 1 and 2 macular holes. Adhesion was surrounded by a shallow posterior hyaloid detachment and this finding convinced observers that antero-posterior traction also played a very important role in the pathogenesis besides tangential traction (4). Based on these important findings, researchers introduced an OCT-based classification for macular holes, which is more useful in clinical practice. Stage 4 defines a full-thickness macular hole where vitreous detachment is found. Recently, the International Vitreomacular Traction Study group has defined and classified closely related vitreomacular disorders according to OCT. This

Received: 10.04.2019 Accepted: 27.05.2019 Available online: 02.07.2019

Corresponding Author: Seyhan Dikci, Inonu University, Faculty of Medicine, Department of Ophthalmology, Malatya, Turkey

E-mail: seyhandikci@gmail.com

classification also described vitreomacular adhesion and vitreomacular traction besides full-thickness macular holes (5).

Macular holes are typically idiopathic and have a prevalence of 3.3/1000. They are more prevalent in females and individuals aged 60-70 years. While most cases are unilateral, bilateral cases can be encountered at rate 10% (6). Vitrectomy allows intervention directed at the pathology of macular holes and the creation of the space required for gas injection at the end of surgery. Recent studies report higher anatomical and visual success in these cases with novel vitreoretinal surgery techniques. The visual outcome may be affected by various factors such as a reopened the macular hole, cataract development, increased intraocular pressure (IOP), and retinal detachment (7).

This study aims to evaluate the intra- and post-operative complications, and anatomical and functional outcomes observed in cases who underwent 23-gauge pars plana vitrectomy (PPV), internal limiting membrane (ILM) peeling and gas endotamponade due to idiopathic stage 4 macular holes.

MATERIAL and METHODS

This study included 17 eyes belonging to 17 cases who had undergone PPV for idiopathic stage 4 macular holes at Inonu University Turgut Özal Medical Centre Department of Ophthalmology between March 2013 and March 2016. Patient files were retrospectively evaluated. Macular hole stages were determined based on biomicroscopic examination and optic coherence tomography results. Cases with a history of trauma, pathological myopia, and diabetes, and cases who previously underwent PPV and/or detachment surgery were excluded from the study. All patients underwent best corrected visual acuity (BCVA) and intraocular pressure (IOP) assessments and anterior and posterior segment examination, and their images were obtained with OCT (RS3000, Nidek) pre- and postoperatively. BCVA was measured using the Snellen equivalent. Procedures performed during surgery, stains used in ILM staining, used endotamponades, pre- and postoperative BCVA and IOP, state of the macular hole according to OCT, and complications were recorded.

All patients underwent 23 G transconjunctival PPV. Locations of trocar insertion were lower temporal, upper temporal, and upper nasal 4mm posterior to the limbus in phakic cases and 3.5 mm posterior to the limbus in pseudophakic cases. In cases where fundus imaging was difficult, core vitrectomy was performed after phacoemulsification and intraocular lens (IOL) implantation. All cases underwent conventional ILM peeling. ILM was stained with brilliant blue, trypan blue, or membrane blue. Vitrectomy was performed using the DORC Eva device (Dutch Ophthalmic Research Center, Zuidland, Netherlands) and the Eibos imaging system (Möller Wedel) and ILM peeling was performed using a macula lens.

Stains were administered without being diluted and slowly by stopping the infusion fluid. Staining procedures were performed in a liquid medium and a 30-second wait time was allowed. Intraocular micro forceps were utilized for ILM peeling. Following fluid-air exchange, 20% SF6 or 15% C3F8 gases were used as endotamponades that do not expand. Sclerotomy sites were closed with 6-0 vicryl in all cases.

Postoperatively, the cases were started on topical antibiotic and steroid drops and recommended to sleep in a facedown position for one week. Patients were requested to visit for a follow-up examination on the first postoperative day, at the first postoperative week, first, third, and sixth postoperative months, and afterwards, at six-month intervals. Anatomical success was considered as a closed macular hole and functional success was considered as improved BCVA after surgery.

Statistical analysis was performed using the SPSS for Windows 21.0 program. Quantitative data were expressed as mean±standard deviation, whereas categorical data were expressed as number (n) and percentages (%). The data were tested for normality using the Shapiro-Wilk test. The Wilcoxon test was utilized for comparisons. The level of significance was considered 0.05 for all tests.

RESULTS

Of the cases, 9 (53%) were female and 8 (47%) were male with an overall mean age of 66.6±6.6 (55-81) years. Duration of macular hole was evaluated based on patient history concerning onset of symptoms. The duration of symptoms was shorter than 6 months in all cases. All cases underwent PPV, ILM peeling, and gas tamponade procedures. Mean follow-up time was 13.9±9.7 (4-30) months. ILM peeling was performed using trypan blue (Membrane Blue, DORC) in 3 (17.6%) cases, brilliant blue (ILM-Blue, DORC) in 4 (23.5%) cases, and membrane blue dual, DORC (trypan blue and brilliant blue) in 10 (58.8%) cases. The used gas tamponades included C3F8 (15%) in 3 cases (17.6%) and SF6 (20%) in 14 cases (82.3%). 4 (23.5%) cases were pseudophakic. One patient had an epiretinal membrane and one patient had glaucoma. The eye with an epiretinal membrane (ERM) underwent epiretinal membrane peeling and ILM peeling.

Best-corrected visual acuity demonstrated an increase in 13 cases (76.5%), 5 of these eyes (29.4%) manifested an increase by 2 rows or more. BCVA remained unchanged in two eyes (11.7%), while it decreased in two eyes (11.7%). Mean BCVA of the cases was 0.08±0.06 (0.03-0.2) preoperatively, and 0.16±0.15 (0.03-0.5) postoperatively ($p<0.05$). Two cases (17.6%) underwent a combined PPV and phacoemulsification surgery. In these eyes, BCVA increased in one eye and remained unchanged in one eye.

Anatomical success was achieved in 13 (76.5%) cases. Figure 1-2. Macular hole had not closed in four patients (23.5%). Three eyes of these eyes were treated with SF6 gas and one eye was treated with C3F8 gas endotamponade. Anatomical success was achieved in eleven of eyes

(78.6%) treated with SF6 gas and in two of eyes (66.7%) treated with C3F8. In the early postoperative period, 3 patients (17.6%) demonstrated a temporary increase in the IOP and this was controlled with medical treatment. Two patients (11.8%) manifested retinal detachment due to an iatrogenic retinal tear. These patients with retinal detachment were administered PPV and silicone oil injection. Of phakic eyes, 4 (30.8%) developed cataracts and underwent phacoemulsification surgery. Irregular IS/OS was demonstrated in four eyes (23.5%).

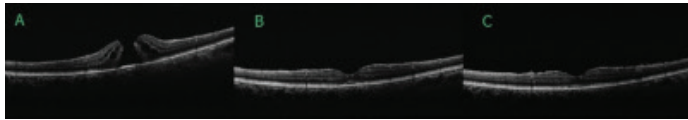


Figure 1. A. Stage 4 macular hole with intraretinal cysts. B. It can be seen that the hole has closed in the first postoperative month and there is subfoveal serous detachment. C. It can be seen that serous detachment has regressed by the fifth postoperative month and the hole has completely closed

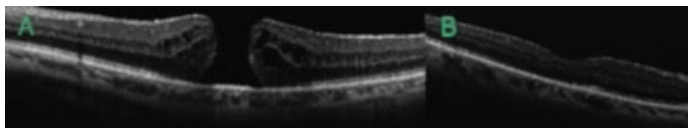


Figure 2. A. Stage 4 macular hole with intraretinal cysts. B. It can be seen that the hole has closed in the first postoperative month and the IS/OS band is irregular

DISCUSSION

Macular hole is a vitreomacular interface disorder with a complex mechanical pathogenesis that significantly impairs vision and is usually idiopathic. Macular holes emerge from abnormal antero-posterior and tangential vitreous traction due to incomplete posterior vitreous detachment (8). Currently, vitrectomy constitutes the most effective treatment option for macular holes, however, issues such as whether or not ILM should be removed or stained, which endotamponade to be used, the necessity and the duration of a facedown sleeping position, and whether or not cases with very long-term or large-diameter holes should be operated are still subject to discussion (9,10).

The literature reports that macular holes are closed at a rate between 58-100% and visual acuity improves by two rows or more in the Snellen equivalent at a rate between 65% and 85% (1,7,11,12). In a study conducted in our country, the authors reported that macular holes were closed at a rate of 88.5% and visual acuity improved by two rows or more at a rate of 62% in a 26-case series who were treated with PPV, ILM peeling, and gas tamponade (13). Meanwhile, Ozturk et al. performed PPV+ILM peeling and intravitreal gas tamponade on 14 of their 15 cases with idiopathic macular holes, while one case with a stage-1B hole underwent SF6 gas injection. Macular holes were closed in 10 (66%) of the 15 cases and 8 (53%) of these 10 cases demonstrated improved visual acuity. Of the cases presented in the mentioned study, 7 had stage 4 macular

holes and all of the 5 cases who had unsuccessful outcomes were reported to have stage-4 macular holes (14). In a study by Ovali et al., 62 (79.5%) of the 74 eyes included manifested improved postoperative vision and mean best visual acuity according to the Snellen equity increased from 0.21 ± 0.20 to 0.45 ± 0.31 postoperatively (15). Another study presented an anatomical success rate of 92.3% but only 30.7% of the patients were found to experience an improvement in their visual acuity by at least two rows or more. This was connected to the fact that all cases included in the study had Stage 3 or 4 macular holes and demonstrated a cataract development rate of 33% (16). In a study by Teke et al. where they evaluated 167 cases, vision was improved at a rate of 69.5%, however, only 25.1% of the cases demonstrated an improvement in their visual acuity by two rows or more according to the Snellen equivalent. They suggested that this outcome was connected to 32.3% of their 167 cases having stage 4 macular holes. They reported in this study that 37 (68.5%) of the 54 cases with stage 4 macular holes demonstrated anatomical success and 33 (61.1%) demonstrated functional success (17). In our study, all cases had stage 4 macular holes and while anatomical and functional success rate was 76.5%, an increase in visual acuity by 2 rows or more in the Snellen equivalent could be achieved in only 29.4% of the cases.

It has been reported that better preoperative visual acuity, small holes, and short symptomatic times are among positive prognostic factors that affect surgical success and the most significant of these is the diameter of the hole (2,18). Tognetto et al. reported that a high-stage hole and long-term presence of symptoms were risk factors for surgical failure, however, that ILM peeling increased surgical closure in patients with long symptomatic periods and stage 3-4 holes (18). Furthermore, Wendel et al. reported better outcomes in patients who had been symptomatic for less than 6 months (2). Meanwhile, Ulrich et al. stated that base and top diameters of the macular hole had prognostic value for macular hole surgery (19).

The necessity of ILM peeling in idiopathic macular hole surgery is controversial. ILM peeling may increase the rate of macular hole closure by reducing tangential forces (20). ILM peeling was reported to increase both primary and final macular hole closure rates and provide better visual outcomes at the third postoperative month (21). On the other hand, it was also reported that ILM peeling could fail to improve visual success despite increasing anatomical success (11). Currently, most surgeons choose to routinely perform ILM peeling in macular hole surgery. Staining the ILM may facilitate the surgical technique, shorten operative times, and ameliorate the surgical trauma and phototoxic damage sustained by the retina. Adjuvants that have been proven useful in ILM staining include indocyanine green (ICG), brilliant blue G (BBG), trypanblue, and triamcinolone acetonide (22). ICG was reported to be more toxic for the retina than other vital stains (23). Triamcinolone acetonide is not a vital stain and can be washed away with irrigation. Triamcinolone acetonide adheres to the retina and is

removed during ILM peeling. Thus, it provides contrast by indicating the remaining areas of ILM where its particles are still attached. BBG has superior biocompatibility (24). Once ILM peeling is complete, the peripheral retina must be checked for potential tears by performing scleral indentation with a depressor (17). In our study, trypan blue was used in 3 (17.6%) cases, brilliant blue in 4 (23.5%) cases, and membrane blue dual in 10 (58.8%) cases.

The preoperative size of the macular hole is an important predictor of anatomical success (19,25). Michalewska et al. defined a surgical technique that is named as inverted ILM peeling in order to increase surgical success in large macular holes (26). In this technique, residual ILM that is left unpeeled is inverted in a way to close the macular hole. They showed that in cases where the macular hole size exceeds 400 µm, macular hole closure reached rates as high as 98% with this technique, surpassing the 81% rate achieved by conventional complete ILM peeling. Kuriyama et al. reported that this technique resulted in a perfect success rate in cases of macular hole associated with pathological myopia (27).

Post-surgical closure of the macular hole occurs through glial proliferation, and since contact with liquids interferes with this, endotamponade and a facedown sleeping position are recommended after surgery (28). However, there is no consensus on the necessity and duration of the facedown sleeping position (15,29). Based on the OCT examinations they performed during the first three days following surgery, Eckardt et al. reported macular hole closure rates of 54.4% in twenty-four hours, 75.7% in forty-eight hours, and 90.9% in the end of seventy-two hours and consequently concluded using the facedown position (30). In our study, the patients were recommended to sleep in a facedown position for one week.

The most prevalent preoperative and postoperative complications associated with macular hole surgery include cataract formation and a temporary increase in IOP, while less common complications such as retinal tears, retinal detachment, ERM formation, changes in retinal pigment epithelium (RPE), an enlarged macular hole, and reopening of the macular hole may be encountered (15,16,31). In their study, Ovali et al. reported detecting cataract formation in 50%, iatrogenic retinotomy during surgery in 2.6%, and increased IOP that responded to postoperative medical treatment in 35.9% of the cases. Moreover, one case manifested retinal detachment and another manifested ERM during follow-up, while one case manifested a reopened macular hole three years from the treatment (15). In a study by Teke et al., no cases demonstrated macular hole opening, 2.4% demonstrated retinal detachment, 3% high IOP controlled by medical treatment, 5.4% parafoveal ERM, and one case (0.6%) an iatrogenic retinal tear in the temporal macula (17). In our study, a temporary increase in IOP was observed in 3 patients (17.6%), retinal detachment in two patients (11.8%) due to an iatrogenic retinal tear, cataract

development in 4 eyes (30.8%), and IS/OS changes in 4 eyes (23.5%).

CONCLUSION

In conclusion, the treatment of idiopathic stage 4 macular holes, 23 gauge PPV and conventional ILM peeling combined with C3F8 or SF6 tamponade provide notable anatomic and functional success. However, the increase in visual acuity remains limited in these cases.

This study was presented as poster presentation at 50th National Congress of Turkish Ophthalmology Society, 9-13 November 2016.

Competing interests: The authors declare that they have no competing interest.

Financial Disclosure: There are no financial supports

Ethical approval: Ethical clearance was obtained from the Ethics and Research Committee of Inonu University,

Seyhan Dikci ORCID: 0000-0003-2062-3515

Soner Demirel ORCID: 0000-0001-6293-9492

Ilknur Tuncer Firat ORCID: 0000-0003-1491-8659

Turgut Yilmaz ORCID: 0000-0001-5028-4214

REFERENCES

- Kelly NE, Wendel RT. Vitreous surgery for idiopathic macular holes. Results a pilot study. Arch Ophthalmol 1991;109:654-9.
- Wendel RT, Patel AC, Kelly NE, et al. Vitreous surgery for macular holes. Ophthalmol 1993;100:1671-6.
- Gass JD. Reappraisal of biomicroscopic classification of stages of development of a macular hole. Am J Ophthalmol 1995;119:752-9.
- Gaudric A, Haouchine B, Massin P, et al. Macular hole formation: new data provided by optical coherence tomography. Arch Ophthalmol 1999;117:744-51.
- Duker JS, Kaiser PK, Binder S, et al. The international vitreomacular traction study group classification of vitreomacular adhesion, traction, and macular hole. Ophthalmol 2013;120:2611-9.
- McCannel CA, Ensminger JL, Diehl NN, et al. Population-based incidence of macular holes. Ophthalmol 2009;116:1366-9.
- Brooks HL Jr. Macular hole surgery with and without internal limiting membrane peeling. Ophthalmol 2000;107:1939-48.
- Johnson RN, Gass JD. Idiopathic macular holes. Observations, stages of formation, and implications for surgical intervention. Ophthalmol 1988;95:917-24.
- Singh SR, Hariprasad SM, Narayanan R. Current management of macular hole. Ophthalmic Surg Lasers Imaging Retina 2019;50:61-8.
- Bardak Y, Çekiç O, Tığ UŞ, ve ark. Maküla deliği cerrahisi sonuçlarımız. Ret-Vit 2007;15:171-5.
- Al-Abdulla NA, Thompson JT, Sjaarda RN. Results of macular hole surgery with and without epiretinal dissection or internal limiting membrane removal. Ophthalmology 2004;111:142-9.
- Park DW, Sipperley JO, Sneed SR, et al. Macular hole surgery with internal-limiting membrane peeling and intravitreal air. Ophthalmology 1999;106:1392-7.
- Avcı R, Yıldız M, Şimşek Ş, ve ark. İdiyopatik maküla deliklerinin tedavisinde indosiyanın yeşili yardımı ile retina iç limitan membranın soyulması. Ret-Vit 2005;13:13-7.
- Öztürk M, Ün Y, Ergen A, İdiyopatik maküla deliği cerrahisi sonuçlarımız. Ret-Vit 2010;18:129-33.
- Ovali T, Erkul SÖ, Ovali Ç, ve ark. İdiyopatik maküla deliği

- tedavisinde pars plana vitrektomi, internal limitan membran soyulması ve bir günlük yatış pozisyonunun anatomik ve fonksiyonel sonuçları. *Ret-Vit* 2009;17:238-44.
16. Yanyalı A, Dinçyıldız A, Çelik G, ve ark. İdiyopatik maküla deliğinde 25-Gauge transkonjonktival sütürsüz vitrektomi. *TOD Dergisi* 2010;40:135-9.
 17. Teke MY, Yılmaz MB, Şen E, ve ark. İdiyopatik maküla deliği olan 167 hastanın tedavi sonuçları. *Ret-Vit* 2012;20:176-84.
 18. Tognetto D, Grandin R, Sanguinetti G, et al. Internal limiting membrane removal during macular hole surgery, results of a multicenter retrospective study. *Ophthalmology* 2006;113:1401-10.
 19. Ullrich S, Haritoglou C, Gass C, et al. Macular hole size as a prognostic factor in macular hole surgery. *Br J Ophthalmol* 2002;86:390-3.
 20. Kwok AK, Lai TY, Man-Chan W, et al.: Indocyanine green assisted internal limiting membrane removal in stage 3 or 4 macular hole surgery. *Br J Ophthalmol* 2003;87:71-74.
 21. Spiteri Cornish K, Lois N, Scott N, et al. Vitrectomy with internal limiting membrane (ILM) peeling versus vitrectomy with no peeling for idiopathic full-thickness macular hole (FTMH). *Cochrane Database Syst Rev* 2013;6:CD009306.
 22. Shukla D, Kalliath J, Neelakantan N, et al. A comparison of brilliant blue G, trypan blue, and indocyanine green dyes to assist internal limiting membrane peeling during macular hole surgery. *Retina* 2011;31:2021-5.
 23. Schumann RG, Gandorfer A, Priglinger SG, et al. Vital dyes for macular surgery: a comparative electronmicroscopy study of the internal limiting membrane. *Retina* 2009;29:669-76.
 24. Ueno A, Hisatomi T, Enaida H, et al. Biocompatibility of brilliant blue G in a rat model of subretinal injection. *Retina* 2007;27:499-504.
 25. Andrew N, Chan WO, Tan M, et al. Modification of the inverted internal limiting membrane flap technique for the treatment of chronic and large macular holes. *Retina* 2016;36:834-7.
 26. Michalewska Z, Michalewski J, Adelman RA, et al. Inverted internal limiting membrane flap technique for large macular holes. *Ophthalmology* 2010;117:2018-25.
 27. Kuriyama S, Hayashi H, Jingami Y, et al. Efficacy of inverted internal limiting membrane flap technique for the treatment of macular hole in high myopia. *Am J Ophthalmol* 2013;156:125-31.e1.
 28. Tornambe PE. Macular hole genesis: the hydration theory. *Retina* 2003;23:421-4.
 29. Elborgy ES, Starr MR, Kotowski JG, et al. No Face-down positioning surgery for the repair of chronic idiopathic macular holes. *Retina* 2018;6.
 30. Eckardt C, Eckert T, Eckardt U, et al. Macular hole surgery with air tamponade and optical coherence tomography based duration of face-down positioning. *Retina* 2008;28:1087-96.
 31. Huynh TH, Johnson MW. The behavior of surgically repaired idiopathic macular holes in the setting of subsequent cystoid macular edema. *Retina* 2007;27:759-63.