



CASE REPORT

Medicine Science 2019;8(2):466-7

Lichenoid hypersensitivity reaction against to dental amalgam: Case report

Merve Nur Guvenc¹, Emine Turkmen Samdanci¹, Ayse Nur Akatli¹, Eren Erdogan², Umit Yolcu²

¹Inonu University, Faculty of Medicine, Department of Medical Pathology, Malatya, Turkey

²Inonu University, Faculty of Dentistry, Department of Oral and Maxillofacial Surgery, Malatya, Turkey

Received 24 November 2018; Accepted 23 December 2018

Available online 30.01.2019 with doi:10.5455/medscience.2018.07.8973

Copyright © 2019 by authors and Medicine Science Publishing Inc.

Abstract

Amalgam or its components may cause delayed hypersensitivity reactions and constitute lesions compatible with lichenoid mucositis in relation to localization. A white colored lesion was detected in the buccal mucosa of a 37-year-old male patient with amalgam filling in the tooth number 46. The lesion was histopathologically reported as lichenoid mucositis. This rare lesion with a specific morphology is presented with the literature.

Keywords: Lichenoid mucositis, amalgam, contact hypersensitivity reaction

Introduction

Amalgam or its components may cause delayed hypersensitivity reactions representing type IV hypersensitivity reaction and constitute lesions compatible with lichenoid mucositis in relation to localization. However, there are very few reported cases of oral lichenoid reaction associated with amalgam fillings in the literature [1-3]. Oral lichenoid reaction is histopathologically similar to oral lichen planus, a chronic inflammatory lesion of the oral cavity, but oral lichen planus generally has not a defined etiological factor [4]. The clinical presentation is similar either but lichenoid reaction associated with amalgam fillings has a definite etiology[1]. The diagnosis of an oral lichenoid reaction associated with amalgam restorations should only be made by combining the medical information, clinical examination and histopathological findings together.

Because of its rarity the case of contact allergic reaction to amalgam leading to lichenoid mucositis is presented herein.

Case Report

A 37-year-old man presented to dental clinic with a white lesion on the mandibular right cheek mucosa. The lesion was unrelated to teeth and bone structures. The patient had not any systemic, autoimmune or dermatologic disease in his medical history. He has not used any medication. On the oral examination of the patient, there was an amalgam filling made five years ago in the tooth number 46 adjacent to the present lesion (Figure 1). The lesion was excised and sent to the pathology department. Microscopic examination of the biopsy revealed necrotic keratinocytes, lymphocyte exocytosis and basal vacuolar degeneration in the keratotic and focally ulcerative hyperplastic squamous epithelium on Hematoxylin&Eosin (H&E) stained sections. (Figure 2). There was band-like lymphoplasmacytic inflammation in the subepithelial area, and the inflammation had a perivascular and paravascular nodular pattern in the deeper areas (Figure 3). The case was reported to be a lichenoid hypersensitivity reaction that has a rare histomorphologic appearance in which dental amalgam can take place in its etiology.

*Corresponding Author: Merve Nur Guvenc , Inonu University, Faculty of Medicine, Department of Medical Pathology, Malatya, Turkey
E-mail: mervenur.guvenc@inonu.edu.tr

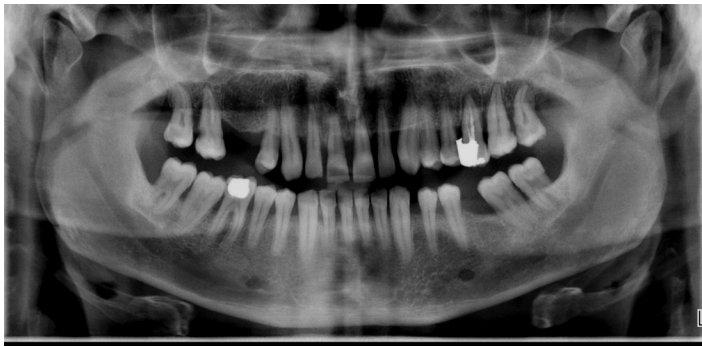

Figure 1. Amalgam filling in tooth 46 in panoramic image

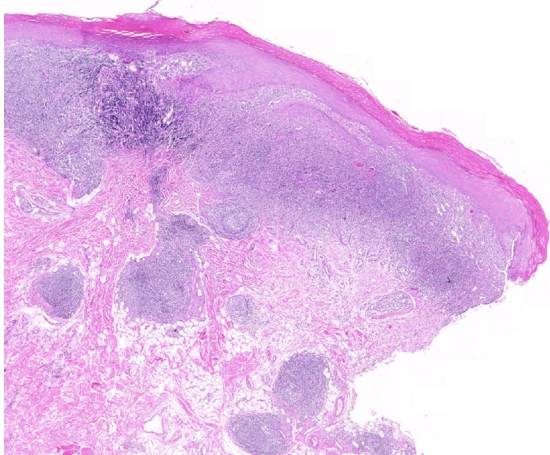


Figure 2. Lymphoplasmacytic inflammation which is band type at subepithelial area, and perivascular and paravascular nodular pattern at the deeper areas. H&E x10

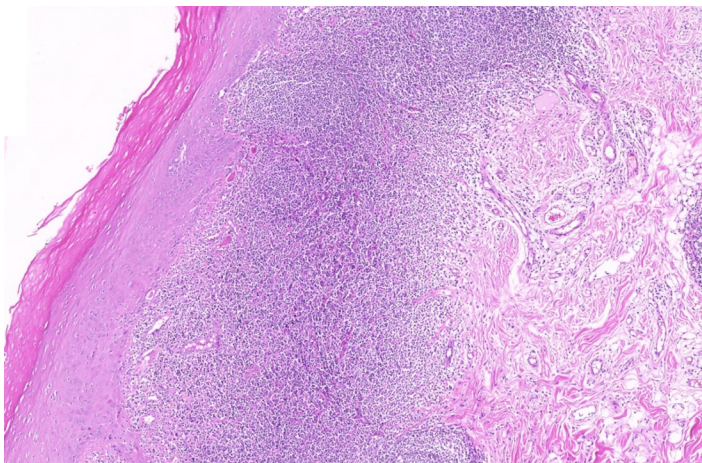


Figure 3. Necrotic keratinocytes, lymphocyte exocytosis and basal vacuolar degeneration were seen in the keratotic and hyperplastic squamous epithelium. H&E x50

Discussion

Although the target antigen has not been identified yet, lichenoid mucositis is considered to be an autoimmune reaction by some investigators. It can be seen in many clinical situations, such as idiopathic, drug-induced, contact, infectious agents, stress, chronic diseases (such as diabetes, hypertension), chronic graft versus host disease [4,8]. Lichenoid lesions have also been associated with dental amalgam, representing type IV hypersensitivity reaction. This reaction occurs in response to some components of metal alloys, particularly mercury. It generally develops after a relatively

long-time period, from months to years [5,6]. The dental amalgam in the present case was placed five years ago, and the patient's complaints started in the last three months.

There are also human and animal studies evaluating the relation between oral lichenoid reaction against to amalgam and patch testing [7,8]. In cases of positive patch test reaction to mercury/amalgam components, partial or complete replacement of the amalgam fillings is advised [8].

Histopathologically, although band-like lymphocyte infiltration as well as epithelial changes is seen in classical lichenoid mucositis, lymphocytes are accompanied by increased plasma cells in our case. Furthermore, as different from classical lichenoid mucositis, lymphoplasmocytic inflammation at perivascular, paravascular region and nodular pattern was seen [4]. In the differential diagnosis, other lesions in the oral mucosa were considered. In clinical examination, the patient does not have any systemic disease or any lesions in the skin and oral mucosa consistent with oral lichen planus. Therefore, it was thought to be associated with amalgam adjacent to the lesion with the support of histopathological evaluation.

Conclusion

The present case is rare, and in the diagnosis of these lesions clinical information is very important for excluding other possibilities. Therefore, the differential diagnosis of lichenoid mucositis was evaluated in terms of relation with amalgam and contact time with amalgam in the context of the literature.

Competing interests

The authors declare that they have no competing interest.

Financial Disclosure

All authors declare no financial support.

Merve Nur Guvenc ORCID: 0000-0001-7717-2132

Emine Turkmen Samdanci ORCID: 0000-0002-0034-5186

Ayşe Nur Akatli ORCID: 0000-0002-9677-2456

Eren Erdogan ORCID: 0000-0001-8368-9429

Umit Yolcu ORCID: 0000-0001-7312-2867

References

- Aggarwal V, Jain A, Kabi D. Oral lichenoid reaction associated with tin component of amalgam restorations: A case report. *Am J Dermatopathol.* 2010;32:46-8.
- Thanyavuthi A, Boonchai W, Kasemsarn P. Amalgam contact allergy in oral lichenoid lesions. *Dermatitis.* 2016;27:215-21.
- McCullough MJ, Tyas MJ. Local adverse effects of amalgam restorations. *Intern Dental J.* 2008;58:3-9.
- Sook-Bin Woo. *Oral Pathology: A Comprehensive atlas and text.* 2nd edition. Elsevier, Philadelphia, 2017. p. 170-8.
- Lopes de Oliveira LM, Batista LHC, Neto APDS, et al. Oral Lichenoid Lesion Manifesting as Desquamative Gingivitis: Unlikely Association? Case Report. *Open Dent J.* 2018;12:679-86.
- Athavale PN, Shum KW, Yeoman CM, et al. Oral lichenoid lesions and contact allergy to dental mercury and gold. *Contact Dermatitis.* 2003;49:264-5.
- Ronald L, Sybren K, Dekker, et al. Oral lichen planus and allergy to dental amalgam restorations. *Arch Dermatol.* 2004;140:1434-8. Dunsche A, Frank MP, Lüttges J, et al. Lichenoid reactions of murine mucosa associated with amalgam. *British J Dermatol.* 2003;148:741-8.