

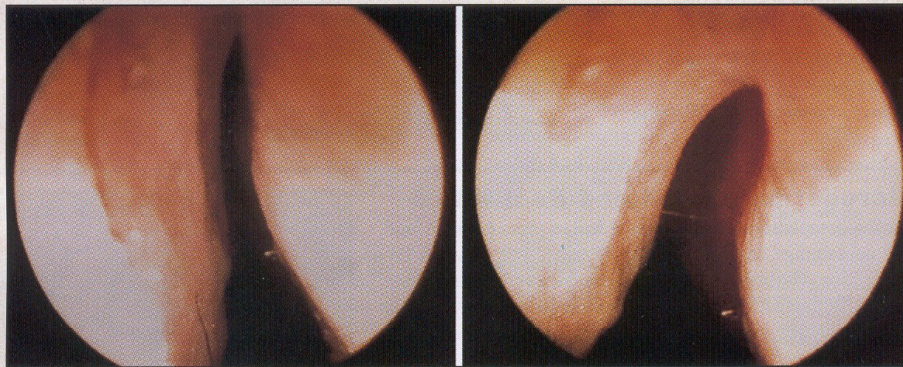
ARCHIVES

OF

FACIAL PLASTIC SURGERY

WWW.ARCHFACIAL.COM

OCTOBER-DECEMBER 2002



Left, Preoperative photograph of the internal nasal valve. Right, Postoperative (17th month) photograph of the same patient's internal nasal valve. See page 258.

AGING ISSUE

COSMETIC USES OF BOTULINUM NEUROTOXIN TYPE A:
AN OVERVIEW

A COMPARATIVE STUDY OF SURGICAL TECHNIQUES
ON THE CERVICOMENTAL ANGLE IN HUMAN CADAVERS

A RETROSPECTIVE COMPARISON OF OPEN AND
ENDOSCOPIC BROW-LIFTS

REJUVENATION OF THE AGING LIP WITH
AN INJECTABLE ACELLULAR DERMAL GRAFT (CYMETRA)

SIMULTANEOUS RHYTIDECTOMY AND FULL-FACE
CARBON DIOXIDE LASER RESURFACING:
A CASE STUDY AND META-ANALYSIS

ACHIEVING SUPERIOR RESURFACING RESULTS
WITH THE ERBIUM:YAG LASER

COMPLETE TABLE OF CONTENTS ON PAGE 211

OFFICIAL PUBLICATION FOR
THE AMERICAN ACADEMY OF FACIAL PLASTIC AND RECONSTRUCTIVE SURGERY, INC.,
AND THE INTERNATIONAL FEDERATION OF FACIAL PLASTIC SURGERY SOCIETIES

JAMA
&
ARCHIVES
JOURNALS
American Medical Association

Bending of the Upper Lateral Cartilages for Nasal Valve Collapse

Orhan Ozturan, MD; Murat Cem Miman, MD; Ahmet Kizilay, MD

Background: As a consequence of removal of the nasal hump, the upper lateral cartilages are separated from the septal cartilage in reductive rhinoplasty. A decrease in the nasal airway cross-sectional area and collapse of the internal nasal valve (INV) are inevitable unless additional surgical measures are taken.

Objective: To determine the efficacy of the horizontal mattress bending suture in treating patients with nasal valve collapse.

Methods: Each upper lateral cartilage was separately bent to a certain degree with a horizontal mattress suture following nasal dorsum reduction in the external septorhinoplasty as a preventive or corrective measure for the INV stenosis. The efficacy of this suture was assessed in 28 patients who presented with tension nose by comparing the INV angles preoperatively and 12 months postop-

eratively, as determined photographically by means of a rigid nasal endoscope.

Results: The mean \pm SD preoperative INV angle was calculated as $9.1^\circ \pm 4.2^\circ$ (range, 0° - 18.3°). The mean postoperative INV angle was increased to $25.3^\circ \pm 3.8^\circ$ (range, 18.4° - 34.5°) ($P < .001$).

Conclusions: This method reconstitutes the normal anatomy of the INV, reestablishes stiffness or resistance of the nasal side walls so that they do not bend inwardly with inspiration, improves the airflow at this area, and avoids postoperative nasal valve stenosis in functional-cosmetic rhinoplasty cases that require considerable nasal hump reduction.

Arch Facial Plast Surg. 2002;4:258-261

THE INTERNAL nasal valve (INV) defines the slitlike cleft between the caudal end of the upper lateral cartilage (ULC) and the septum.¹ Although its function is affected by all the structures that make up the INV area,² an INV angle narrower than 10° to 15° in the nose can certainly cause nasal obstruction.³ According to the Poiseuille law, airflow is proportional to the radius of the nasal passages, raised to the fourth power. Thus, a small change in the angle of the valve will have a large effect on airflow and resistance of the nasal cavity.³ When air flows through a narrow space, such as the INV, it not only speeds up, it also creates an inward pressure owing to the Bernoulli principle, which draws the weakened area further in, leading to a vicious cycle of increasing force and eventual nasal valve collapse.⁴

Surgical resection of the nasal hump permanently disrupts the attachments between the septum and the ULCs, leaving the septum isolated in the midline (**Figure 1**).

Since there is no lateral skeletal connection for the ULCs, they are supported only by the nasal bones cranially. As a consequence of the nasal hump removal, middle nasal vault collapse may occur postoperatively. This collapse narrows the INV, decreases resistance against the negative pressure produced during inhalation, and impairs airflow through the nose. Since nasal surgery involving the INV frequently causes constriction in this essential area,^{2,3} certain preventive measures should be adopted during the primary operation. We describe using a horizontal mattress bending suture for the ULC as a preventive or corrective measure to preclude INV narrowing in reductive rhinoplasty cases.

METHODS

In the last 30 months, 42 patients (18 men and 24 women) with tension nose presenting an obvious nasal hump were treated by either primary rhinoplasty (11 cases) or septorhinoplasty (31 cases) using an external approach by one of us (O.O.). The average patient age

From the Faculty of Medicine, Department of Otorhinolaryngology, Inonu University, Malatya, Turkey. The authors have no commercial, proprietary, or financial interest in the products described in this article.

was 22 years (range, 17-27 years). The nose, particularly the INV, was routinely assessed by rigid endoscopy before surgery. The condition of the INV angle for each side was documented preoperatively by taking endoscopic photographs. Twenty-eight patients who had completed at least 12 months (range, 12-30 months) of the postoperative period were evaluated for the efficacy of the horizontal mattress bending suture. Endoscopic photographs were also taken at least 12 months after the operation.

SURGICAL TECHNIQUE

Submucoperichondrial elevation was performed at the junction between the septal cartilage and ULCs without causing any mucoperichondrial disruption by the extramucosal technique. The cartilaginous and bony hump reductions were performed using the component resection method with a No. 15 blade and a Rubin osteotome, respectively. This dorsal reduction leaves the septum in the midline isolated from the ULC (Figure 1). Following septal correction and tip surgery, each ULC is treated separately with 5-0 polypropylene suture. Basically, this preventive surgical technique is an application of a horizontal mattress suture for each ULC. The needle is inserted near the lateral border at the midlevel of the ULC and moved medially between the inner mucoperichondrium and the cartilage without entering the nasal lumen (Figure 2A). The suture leaves the ULC close to the medial margin, and then the needle is reinserted near the medial edge at the caudal level of the ULC. It is moved laterally between the inner mucoperichondrium and the cartilage again without entering the nasal lumen (Figure 2B). The horizontal mattress bending suture is accurately placed, while one of the blades of a Brown-Adson forceps is placed endonasally and positioned exactly over the mucoperichondrium underneath the ULC and the other blade is placed over the ULC, fixing in the desired positions. The caudal end of the ULC is typically hidden under the cephalic margin of the lateral crus, which is retracted inferiorly using a skin hook for an adequate exposure. An intranasally inserted Freer elevator can also help deliver this area of the ULC into the surgical view. The suture is tied and tightened over the lateral-caudal aspect of the ULC until the cartilage is converted slightly to a convex shape so that it curves outwardly at the INV area (Figure 2C) and increases the INV angle (Figure 3). The ULC on the contralateral side is treated in the same manner.

Following the bending suture application, separated portions of the ULCs were reattached to each other and the septum with two 5-0 polypropylene sutures in 30 cases. In addition to the bending suture, spreader grafts were applied in 12 patients bilaterally when the straightened septal cartilage required support. Harvested septal cartilage was shaped into spreader grafts, which were 1- to 2-mm thick and at least 15-mm long. They were anchored submucoperichondrially between the septal cartilage and the ULCs with two 5-0 chromic catgut sutures. Inferior turbinates were also treated conservatively with either submucosal diathermy or inferior turbinoplasty.

Because of the concern regarding possible adverse cosmetic sequela owing to the horizontal mattress bending suture, one of us (A.K.) did not participate in the surgical procedures and evaluated the appearance of the nose after 12 months using a visual analog scale. Patients were asked whether they were satisfied or dissatisfied with the appearance of their own noses and were requested to score the appearance from 0 (highly dissatisfied) to 10 (highly satisfied).

STATISTICAL ANALYSIS

The differences between preoperative and postoperative nasal valve angles were compared by paired *t* tests. Visual analog scores

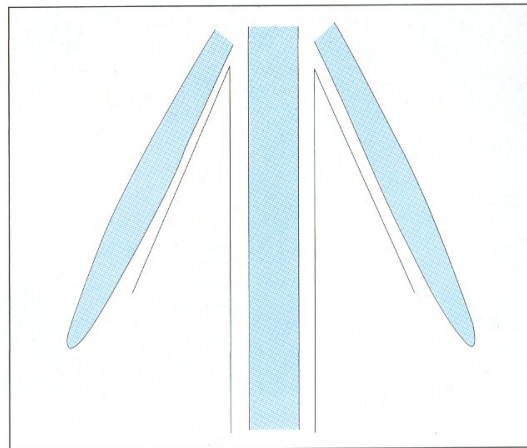


Figure 1. Surgical resection of the hump disrupts the continuity between the septal cartilage and upper lateral cartilages and leaves the septum in the midline.

for cosmesis at 12 months as rated by one of us (A.K.) and the patients were compared by unpaired *t* tests in groups with equal variances. The equality of variances was assessed by the Levene test.

RESULTS

Patients with nasal obstruction complaints were evaluated for all potential causes. Nasal obstruction owing to the INV was not observed in any of the patients. They were all satisfied with the functional and cosmetic results that had been achieved. Therefore, no revision surgery was necessary in this group of patients. Synechia developed and caused a minor degree of nasal obstruction in 2 patients. Cutting and light gelfoam packing relieved this complication. None of the patients complained of any type of feeling regarding knots or experienced suture spitting. Endoscopic photographs taken at least 12 months after the operation documented the improvement in the INV angle compared with the preoperative records (Figure 4A and B). The mean \pm SD preoperative INV angle was calculated as $9.1^\circ \pm 4.2^\circ$ (range, 0° - 18.3°). The mean postoperative INV angle was increased to $25.3^\circ \pm 3.8^\circ$ (range, 18.4° - 34.5°). This enhancement in the angle was statistically significant ($P < .001$).

With regard to cosmetic evaluation, the mean patient visual analog scale score was 8.8 (range, 9.5-8.1) and the mean surgeon visual analog scale score was 8.2 (range, 9.1-7.6). There were no significant differences between surgeon's and patients' scores ($P = .47$).

COMMENT

Rhinoplastic surgeons often overlook the importance of the middle third of the nose, focusing their attention on aesthetic concerns, such as the nasal tip. If surgical reconstruction between the septal cartilage and the ULC is neglected, the patient may develop postoperative problems, such as an S-shaped dorsum, open-roof deformity, cold sensitivity, INV stenosis, dorsal irregularities, and V-shaped shadow on the dorsum.⁶ Patient dissatisfaction can

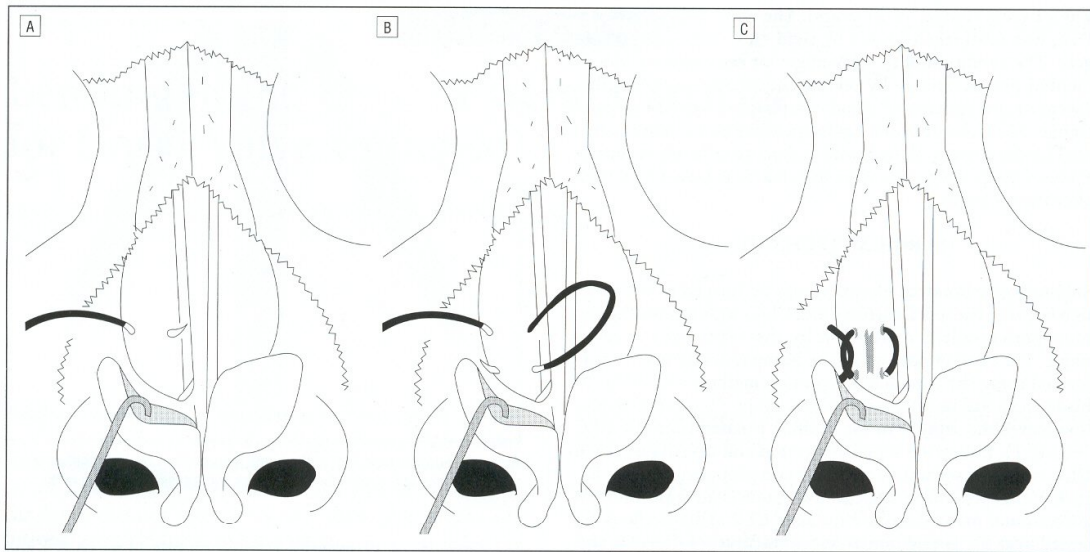


Figure 2. A, The needle is inserted near the lateral border at the midlevel of the upper lateral cartilage (ULC) and moved medially between the inner mucoperichondrium and the cartilage without entering the nasal lumen. B, The suture leaves the ULC close to the medial margin, and then the needle is inserted near the medial edge at the caudal level of the ULC. It is moved laterally between the inner mucoperichondrium and the cartilage again without entering the nasal lumen. C, The suture is tied and tightened over the lateral-caudal aspect of the ULC until the cartilage is converted slightly to a convex shape so that it curves outwardly at the internal nasal valve area.

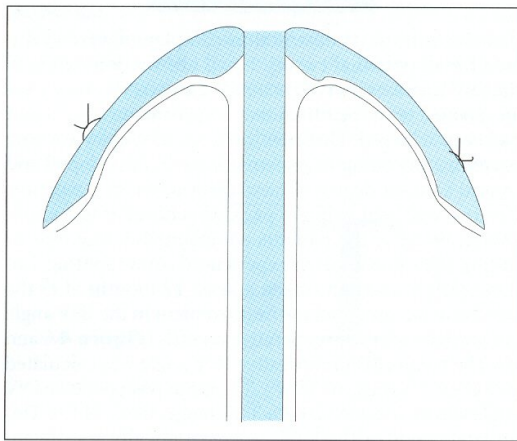


Figure 3. The natural T-shaped configuration can be reconstituted by bending the upper lateral cartilages to a certain degree with the bilateral horizontal mattress suture.

be profound if the surgery provides a good cosmetic result but fails to correct the preoperative nasal obstruction or causes nasal obstruction postoperatively. Constriction of the INV is a common reason for nasal obstruction in patients who have undergone rhinoplasty.¹ Hence, middle nasal vault reconstruction is recommended for all patients with nasal vaults that are predisposed to collapse after rhinoplasty. Predisposing factors include full-thickness mucocartilaginous transection of each ULC from the septum, overresection of the dorsal septum, excessive resection of the ULC, and mucosal scarring with INV synechia.⁷ Since there is a high propensity for INV stenosis to occur postoperatively (Figure 1), this technique was

applied to all of our patients with high predispositions even though some of them had near-normal INV angles preoperatively (Figure 4A and B).

In rhinoplastic surgery, septal deviation must be corrected in accordance with the septal pathologic features. Certain surgical principles, such as routine mucoperichondrial elevation at the junctions between the ULCs and the septum before the hump removal, component removal method of the nasal hump, conservative resection of the lower lateral cartilages and ULCs, high-to-low lateral osteotomy, and meticulous extramucosal dissection techniques, while preserving muscles and mucosa, must be strictly followed. Even after following these rules, reduction rhinoplasty intrinsically decreases the nasal airway cross-sectional area and may cause symptoms of nasal valve collapse unless additional surgical measures are taken to prevent such symptoms. Grymer⁵ demonstrated that rhinoplasty decreases the cross-sectional area of the INV by 25% and the pyriform aperture by 13%.

In normal anatomy the ULCs are fused to the septal cartilage in a T-shaped form, and this fusion acts like a spring, keeping the INV open.⁶ The cartilaginous nasal dorsum is important in terms of postoperative appearance and nasal patency in functional and cosmetic nasal surgery. The aesthetically improved new shape of the cartilaginous vault, although providing a graceful contour, may not solve or may even aggravate nasal breathing problems. Whenever a hump reduction is performed, the stability between the septum and the ULCs should be reestablished by recreation of the T-shaped structure. Bending of the ULCs to a certain degree with bilateral horizontal mattress sutures is a favorable technique that improves the INV angle and directly increases the cross-sectional area of the INV (Figure 3). It

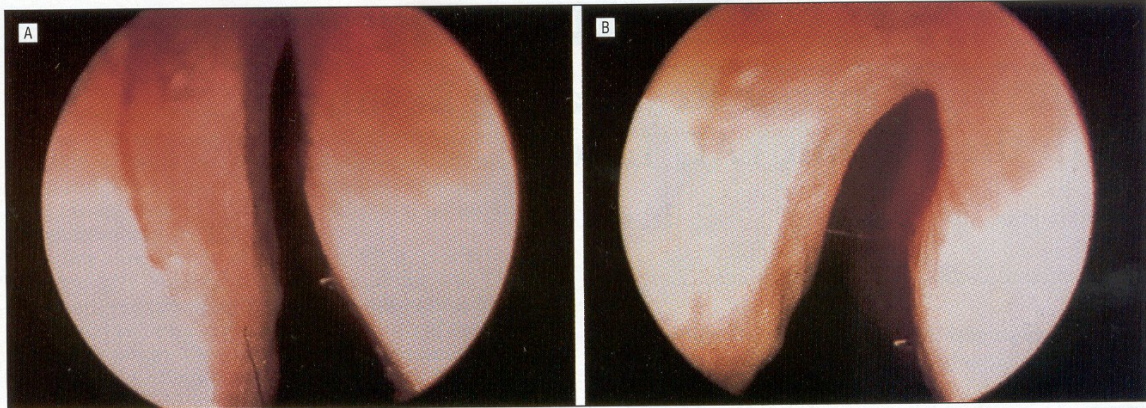


Figure 4. A, Preoperative photograph of the internal nasal valve. B, Postoperative photograph (at 17 months) of the same patient's internal nasal valve.

also enhances the strength of the lateral nasal wall to resist inward bowing with intranasal negative pressure by means of its convex shape, preventing middle vault collapse. Application of the bending suture requires the open approach for an adequate exposure. On the other hand, the surgeon must be cautious against overtightening the horizontal mattress bending suture because that may cause an aesthetic disfigurement. Although not statistically significant, our patients seemed to be more satisfied than the rating surgeon with the cosmetic results at 12 months. The use of horizontal mattress bending sutures for the ULCs is an attempt to reconstruct the normal anatomy of the ULC-septal complex. Although the bending suture converts the inverted V form that occurs after dorsal hump resection to the T shape, the cartilaginous dorsum eventually widens and attains a natural appearance, instead of an "operated-on" look.

Spreader grafts have more aesthetic than functional importance.⁷ They act to widen the middle nasal vault and aid in repositioning the ULCs but do not provide increased support to the lateral nasal walls.^{8,9} Therefore, their additional application is unnecessary, unless they are required for the reinforcement of the septal cartilage. Bending sutures can be performed without spreader grafts when the nasal septum is straight and sufficiently strong.

We did not use any rating method for the level of preoperative and postoperative nasal obstruction declared by the patients because postoperative nasal obstruction could be caused by multiple reasons other than the INV stenosis. Acoustic rhinometry could be an alternative to investigate the efficacy of the surgical technique. However, an improved result in the nasal valve area detected by an acoustic rhinometry would not allow us to infer the value of the suture technique because positive contributions of the septal correction and turbinate reduction steps of the surgery also have clear roles for enhancement of the nasal valve area. Since the INV is the center of the discussion, a direct objective view via rigid endoscopy and photographs was evaluated as the best and most reliable method for the investigation of the efficacy of our technique. Preoperative and postoperative angles were measured numerically on the photographs and studied statistically.

In conclusion, the ULC bending suture and submucoperichondrial dissection for the reconstruction of the INV through an external approach can eliminate postoperative INV constriction. Primary goals of the ULC bending with suture are as follows: to reconstitute the normal anatomy of the INV, to reestablish stiffness or resistance of the nasal side walls so that they do not bend inwardly with inspiration, and to improve the airflow at this area. This technique is particularly indicated for patients with tension nose. Dorsal projection is not altered by this suture. Surgeons should avoid creating postoperative nasal valve stenosis by including this simple suture to their surgical armamentarium. We have applied this technique to more than 40 cases with INV stenosis in the last 2½ years, with favorable subjective inquiries and objective nasal endoscopic findings. We also recommend this technique for those cases with a tendency to develop INV constriction postoperatively.

Accepted for publication February 6, 2002.

Corresponding author and reprints: Orhan Ozturan, MD, Faculty of Medicine, Department of Otorhinolaryngology, Inonu University, Malatya, 44300 Turkey (e-mail: orhanent@yahoo.com).

REFERENCES

1. Kasperbauer JL, Kern BE. Nasal valve physiology: implications in nasal surgery. *Otolaryngol Clin North Am.* 1987;20:699-719.
2. Teichgraber JF, Wainwright DJ. The treatment of nasal valve obstruction. *Plast Reconstr Surg.* 1994;93:1174-1182.
3. Broker BJ, Berman WE. Nasal valve obstruction complicating rhinoplasty: prevention and treatment, part I. *Ear Nose Throat J.* 1997;76:77-78.
4. Holt RG. Septorhinoplasty: form versus function. *Otolaryngol Clin North Am.* 1999;32:1-6.
5. Grymer LF. Reduction rhinoplasty and nasal patency: change in the cross-sectional area of the nose evaluated by acoustic rhinometry. *Laryngoscope.* 1995;105:429-431.
6. McKinney P, Johnson P, Walloch J. Anatomy of the nasal hump. *Plast Reconstr Surg.* 1986;77:404-405.
7. Guyuron B, Michelow BJ, Englehardt C. Upper lateral splay graft. *Plast Reconstr Surg.* 1998;102:2169-2177.
8. Toriumi DM, Josen J, Weinberger M, Tardy JE. Use of alar batten graft for correction of nasal valve collapse. *Arch Otolaryngol Head Neck Surg.* 1997;123:802-808.
9. Schlosser RJ, Park SS. Functional nasal surgery. *Otolaryngol Clin North Am.* 1999;32:37-51.