

Mid-term results of treatment with curettage and grafting in tumor-like cysts of long bones

Mehmet Esref Encan, Resit Sevimli

Inonu University Faculty of Medicine, Department of Orthopaedics and Traumatology, Malatya, Turkey

Abstract

Aim: Curettage and bone grafting are common methods in the treatment of tumor-like cysts in the bone. In this study, we present our treatment results of curettage and bone grafting in patients with tumor-like bone cysts.

Material and Methods: Ninety-three patients (57 males, 36 females, mean age: 33 years; range: 3 to 67 years) who were diagnosed with the tumor-like bone cysts in our clinic between March 2009 and December 2016, were evaluated. Curettage and bone grafting treatment were applied to all patients. The efficacy of the treatments was evaluated according to the Neer/Cole classification, and recurrence rates were recorded.

Results: Of the treated 93 patients, 35 had a non-ossifying fibroma (NOF), 22 had an aneurysmal bone cyst (ABC), 21 had a unicameral bone cyst (UBC), and 15 had fibrous dysplasia (FD). Thirty-nine of these cysts were located in the femur, 23 in the tibia, 22 in the humerus, six in the fibula, and three in the radius. Recurrence rates were observed as 14.3% (n=3) in UBCs, 13.6% (n=3) in ABCs, and 2.9% (n=1) in NOFs. In the tumor-like bone cysts, post-treatment complications were as follows: infection in five patients (5.3%), wound site problems in 11 patients (11.8%), deformity, fracture, coxa vara, limitation of the range of motion, and lower extremity shortness in nine patients (9.6%).

Conclusion: These study results show that curettage and bone grafting for the patients who are admitted to the hospital with tumor-like lesions are effective and useful treatment modalities in the orthopedic oncology.

Keywords: Benign Tumor, Cyst; Curettage; Recurrence; Bone Grafting.

INTRODUCTION

Long bones, especially the femur and tibia, are subjected to most of the load during daily activities and they are crucial for skeletal mobility. They grow primarily by elongation of the diaphysis, with an epiphysis at each end of the growing bone (1). Bone tumors are classified as benign and malignant according to the tissue they originate, their growth and behavior patterns (2, 3).

The majority of bone tumors seen in childhood are benign, and many of these tumors can be diagnosed with specific radiographic and clinical findings without the need of biopsy (4). Tumor-like lesions in the bone seen in childhood are caused by different tissues. Non-ossifying fibromas (NOFs) and fibrous dysplasia (FD) are fibrous tissue-related lesions, while unicameral bone cysts (UBCs) and aneurysmal bone cysts (ABCs) are mixed tissue-related lesions (6).

Tumor-like bone cysts are more commonly seen in

childhood when bone maturation is not complete, and they are usually asymptomatic. Benign bone cysts are not often seen in 0-5 years old (6). Unicameral bone cysts represent about 3% of all bone tumors in which biopsy is not performed. They occur mostly in children aged between 4 and 10 years, and which are almost always seen in the first two years of life (6). It is more commonly seen in males with a male-to-female ratio of 2:1 (7).

Aneurysmal bone cysts represent about 1% of all primary bone tumors in which biopsy is performed, and about 70% of affected patients are between 5 and 20 years old (8). However, this lesion has been also reported in infants (9). Non-ossifying fibromas are common lesions in childhood. The prevalence of FD is unknown; however, it is not a rare primary bone tumor. In particular, polyostotic shape is more common in women, compared to men (10). Although most of the lesions are probably present in early childhood, they are usually not recognized until late childhood or adolescence period (11).

Received: 01.12.2017 **Accepted:** 13.12.2017

Corresponding Author: Resit Sevimli, Inonu University Faculty of Medicine Department of Orthopaedics and Traumatology, Malatya Turkey, E-mail: resitsevimli@hotmail.com

In this study, we present our treatment results of curettage and bone grafting in patients with tumor-like bone cysts and evaluated recurrence rates.

MATERIAL and METHODS

Between March 2009 and December 2016, a total of 127 patients with tumors and tumor-like cysts in their long tubular bones following the incidental, symptomatic or pathological fractures, and who received curettage and bone grafting treatment were evaluated. Of these patients, 23 were not included in the study, since their pathological diagnosis was a tumoral bone cyst, and 11 patients with a tumor-like bone cyst were also not included in the study due to missing data. In addition, three patients with tumor-like bone cysts treated with steroid injection were also excluded from the study. The remaining 93 patients (UBC, ABC, NOF, and FD cases) were included in the study. The data of these cases were obtained from archive files, operation notes, pathology results and radiological data system. The demographic characteristics, complaints and treatment outcomes of these cases were evaluated, and the results were compared.

A written informed consent was obtained from each patient. The study was conducted in accordance with the principles of the Declaration of Helsinki.

Surgical method operated following the general necessary preparations for the surgery. The location of the lesion was determined in fluoroscopy control. Then, the skin and subcutaneous were passed

The tourniquet was washed, stained, and covered after it was applied to the extremity through the longitudinal incision, and the fascia was reached under general anesthesia. The fascia was opened longitudinally, the muscles were split and the bone was reached. The cavity and cyst contents were debrided with a high speed burr. The whole cavity wall was cauterized and reached by opening an oval window in the cortex, where the lesion was located, via the motor or osteotoma. The cyst content was curetted and sent to the pathology. The cavity wall cleaned with burr. The surgical site was washed with the sterile physiological saline, and the inside of the cavity was completely filled with potassium iodide. It was re-washed with the sterile physiological saline one minute later. Then, the inside of the cavity was filled with an allograft, autograft, allograft + autograft, cement, cement + allograft or autograft according to the diagnosis of the lesion. After the cavity was seen to be consolidated through fluoroscopy, the cortical bone was placed after it was debrided and cleaned. The internal or external fixation was or not performed depending on the diagnosis, and localization and size of the cyst. Following the washing process, a Hemovac® drain was placed, and the layers were sutured in accordance to their anatomy. Operation was completed with the wound dressing.

In the evaluation of the treatment response of tumor-like bone cysts, the Neer/Cole classification was used in the postoperative radiographies at postoperative one

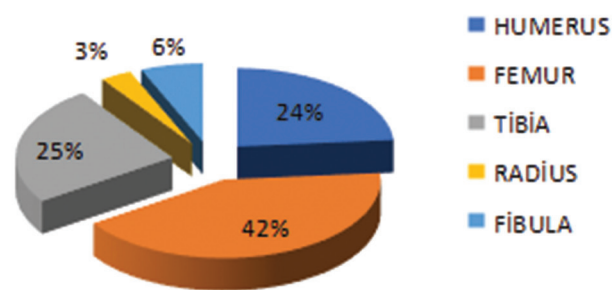
year. The Neer/Cole classification was not used in the postoperative first year radiographies of the cases treated with cement.

RESULTS

Of the patients with tumor-like bone cysts, 48 patients (52%) were diagnosed mostly after referring with pain or another symptom. Twenty patients (21%) were diagnosed after a pathological fracture, and 25 (27%) were diagnosed incidentally (Table 1).

| | |
|---------|-----------------------------------------------|
| Grade 1 | Complete recovery |
| Grade 2 | Recovery higher than 50% (partial recovery) |
| Grade 3 | Recovery lower than 50% (incomplete recovery) |
| Grade 4 | Recurrence (no recovery) |

Sixteen patients (33%) with tumor-like bone cysts who were admitted with the complaint of pain or other symptoms were found to be NOF cases. Of the symptomatic cases, 14 (29%) were observed to have UBC, nine of them (19%) had ABC, and nine (19%) of them had FD. Nine patients (45%) who were admitted with a pathological fracture were mostly the ABC cases. Some of the patients with tumor-like bone cyst referred to our clinic for different reasons, and these patients were incidentally diagnosed. Sixteen of them (64%) had a NOF. Fourteen of 21 patients with UBCs (66.7%), nine of 22 patients with ABCs (40.9%), sixteen of 35 patients with NOFs (45.7%), and nine of 15 patients with FD (60%) were admitted to the clinic with pain or another symptom (Graph 1).



Graph 1. Long bones of the cases

Of the tumor-like bone cysts, 39 (41.9%) were found to be located in the femur. The other 23 cysts (24.7%) were found to be located in the tibia and six (6.5%) in the fibula. A total of 78 (73.1%) of tumor-like bone cysts were located in the lower extremity of the long bones, which carry the majority of the load. In the upper extremity, 22 cysts (23.7%) were located in the humerus and three (3.2%) in the radius.

Eleven of the UBCs (52.4%) were located in the humerus. Other nine (42.9%) were located in the femur and one (4.8%) in the fibula. Nine of ABCs (40.9%) were located in the humerus. Other six cysts (27.3%) were located in the femur, three (13.6%) were located in the fibula, two

(9.1%) were located in the tibia, and other two were (9.1%) located in the radius. Nineteen of the NOF cysts (54.3%) were located in the tibia. Other 12 cysts (34.3%) were located in the femur, two (5.7%) in the fibula, one (2.9%) in the humerus, and other one (2.9%) in the radius. Twelve of FD cysts (80%) were located in the femur. The other two (13.3%) were located in the tibia, and one (6.7%) in the humerus.

According to this, the Neer/Cole classification was able to be done in 78 cases at the end of the first year. The Neer/Cole classification was determined as Grade 1 in 42 cases (54%), Grade 2 in 21 cases (27%), Grade 3 in 8 cases (10%) and Grade 4 in seven cases (9%). Grade 4 recurrence was only seen in seven of 78 cases (7.5%).

According to the Neer/Cole classification, three of the seven patients with Grade 4 were observed to have UBC, and three of them had ABC. A remaining case was found to have NOF (Table 2).

Of the 21 patients with UBC, 10 (47.6%) were observed to have Grade 1 complete recovery, and three (14.3%) of them were observed to have Grade 2 recovery. Grade 3 incomplete recovery was found in five (23.8%) cases, and Grade 4 recurrence was found in three (14.3%) cases (Table 3).

The Neer/Cole classification was able to be done in 30 of 35 cases with NOF cyst. Of these patients, 16 (53.3%) were observed to have Grade 1 complete recovery, and 13 (43.3%) were observed to have Grade 2 recovery. Grade 4 recurrence was observed in one case (3.3%). Grade 3 was not determined in any case. Recurrence was only observed in one of 35 cases (2.9%) (Figure 1).

The Neer/Cole classification was able to be done in 11 of 15 cases with FD cyst. Of these patients, eight (72.7%) were observed to have Grade 1 complete recovery, and three (27.3%) were observed to have Grade 2 recovery. There was no case with Grade 3 and 4.

Table 2. The reasons of admission before the diagnosis

| Before diagnosis p=0.005 | Unicameral bone cyst (UBC) | Aneurysmal bone cyst (ABC) | Non-ossifying fibroma (NOF) | Fibrous dysplasia (FD) | Total |
|-----------------------------|----------------------------|----------------------------|-----------------------------|------------------------|-------------|
| Symptomatic | 14 29.2% | 9 18.8% | 16 33.3% | 9 18.8% | 48 100% |
| Pathological fracture | 6 66.7% | 9 40.9% | 3 45.7% | 2 60% | 20 51.6% |
| Incidental | 1 30% | 4 45% | 16 15% | 4 10% | 25 100% |
| | 4 28.6% | 3 40.9% | 3 8.6% | 3 13.3% | 13 21.5% |
| | 1 4% | 4 16% | 16 64% | 4 16% | 25 100% |
| | 4.8% | 18.2% | 45.7% | 26.7% | 26.9% |

Table 3. Postoperative first year Neer/Cole classification of the 78 patients undergone bone grafting

| Neer/Cole classification p=0.592 | Unicameral bone cyst (UBC) | Aneurysmal bone cyst (ABC) | Non-ossifying fibroma (NOF) | Fibrous dysplasia (FD) | Total |
|-------------------------------------|----------------------------|----------------------------|-----------------------------|------------------------|-------------|
| Grade 1 | 10 23.8% | 8 19% | 16 38.1% | 8 19% | 42 100% |
| Grade 2 | 3 47.6% | 2 50% | 13 53.3% | 3 72.7% | 21 53.8% |
| Grade 3 | 5 14.3% | 3 12.5% | 3 43.3% | 3 27.3% | 8 26.9% |
| Grade 4 | 3 62.5% | 3 37.5% | 0 0 | 0 0 | 3 100% |
| | 3 23.8% | 3 18.7% | 1 3.3% | 0 0 | 7 10.3% |
| Total | 21 42.8% | 16 42.8% | 30 14.4% | 11 0 | 78 100% |

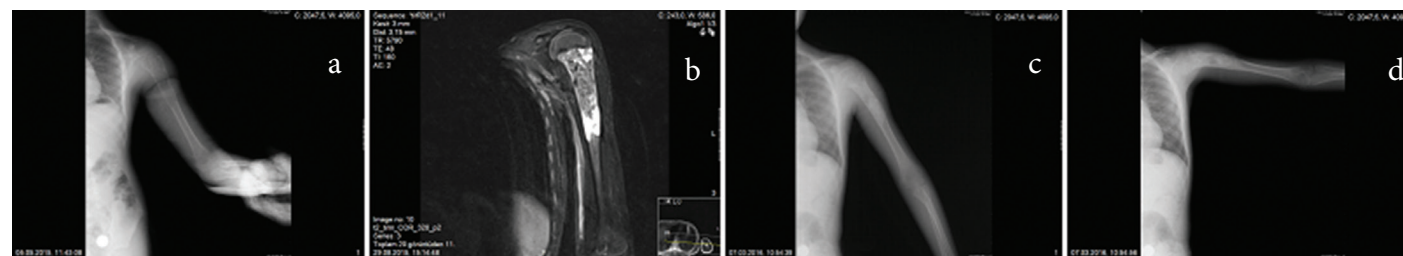


Figure 1a. Anteroposterior (AP) direct radiography of the preoperative humerus of a 10-year-old male patient with an UBC. **Figure 1b.** Preoperative MRI image of the patient. **Figure 1c and 1d.** AP-lateral radiography of the humerus of the patient in the postoperative first year.

Discussion

In the treatment of UBC, curettage and bone grafting, corticosteroid injection into the cysts, autologous bone marrow injection and decompression of the cysts with multiple drilling are performed. In ABCs, adjuvant therapies such as cementing, cryotherapy or embolization should also be considered as well as curettage and bone grafting due to the high local recurrence. If the cyst is located in an expandable bone such as costa or fibula, surgery can be performed with wide or en-block resection. In the treatment of ABCs, Dexamethasone Oral and multiple Kirschner wires inserted into the cyst can be used. Radiation therapy can be also used. Treatment is not required for the fibrous cortical defects (FCD). Non-ossifying fibromas are treated if they have the risk of symptomatic or pathological fracture development. They are treated with curettage and bone grafting. Internal fixation should be often applied in addition to the curettage and bone grafting in the treatment of FD. Cortical strut allografts or cements should be used since they are resorbed (7).

In our study, the patients with UBCs were admitted to our clinic with complaint of severe pain, those with ABCs with pain and pathological fractures, those with NOFs with incidental pain, and those with FD with pain. Review of the literature reveals that patients with UBCs are mostly admitted with incidental and pathological fractures (6,17). Since ABCs are superficial, pain and swelling are the most common symptoms of them. Trauma is responsible for the symptoms in a third of cases (11). Non-ossifying fibromas are usually asymptomatic and incidentally diagnosed; however, cortical expansion may create an aggressive appearance particularly in thin bones such as fibula (15,16). Many patients are asymptomatic in FDs (18). These may rarely occur with pain, deformity or pathological fracture (19). The fact that our clinic is in a central hospital in the region and the symptomatic patients who were initially diagnosed in the external centers which are referred to our center for the treatment is the reason for high rate of symptomatic patients in our study than the previous studies.

According to the anatomic locations of the long bones in our study, UBCs were located in the humerus and femur in a majority of cases. Aneurysmal bone cysts were also located in the humerus and femur mostly. Non-ossifying fibromas showed tibial and femoral involvement, and FDs showed femur involvement mostly. In previous studies in the literature, UBCs were more commonly seen in the proximal humerus and proximal femur (6). Aneurysmal bone cysts were most commonly located around the knee, NOFs in the femur and tibia, and FD most commonly showed femoral involvement (6,12,15-17). The involvement areas of our cases are, thus, in consistent with the literature.

All patients were treated with curettage and bone grafting in our study. Implantation was performed in 30 patients in addition to the curettage and bone grafting. En-block resection was performed to an ABC located proximal to the fibula after the recurrence.

In the literature review, Oppenheim et al. (10), compared the curettage and bone grafting with the steroid injection method in the treatment of UBCs in 1984, and they reported that no difference was observed. In 1986, Campanacci et al. (9), and then in 1992, Myelle et al. (20) reported that steroid injection method was superior to the curettage and bone grafting. Later on, these two techniques were compared in many studies, and it could not be shown that which method is superior (21-23). In 1995, Gennari et al. (35) compared the osteosynthesis technique with the abovementioned two techniques; however, they did not see any differences in the results. Then, Bensahel et al. (24) claimed that the resection and myoplasty techniques were superior to the steroid injection. Tsuchiya et al. (25) compared multiple drilling, cannulated screw fixation, steroid injection and myoplasty methods in 2002, and they did not find any significant difference between these methods. In the same year, Chang et al. (26), and in 2007, Cho et al. (27) reported that steroid and autologous bone marrow injections gave the same results. Chuo et al. (28) compared the internal fixation method with the cannulated screw method in 2003, and they found the same results. In 2006, Sancthis (29) emphasized that continuous drainage could be achieved in the cyst through the elastic stable intramedullary nailing, and reported 66% complete and 34% partial recovery according to Capanna's radiological criteria. Myelle et al. (9) aimed to improve the success by adding steroid to the curettage and bone grafting treatment; however, these treatment modalities were not found to be superior to steroid injection. Donaldson et al. (30) wrote an evidence-based article on the treatment of UBC after they examined Level I-III studies between 1966 and 2010. Most of the cases were treated with the methods of curettage and bone grafting, and also steroid injection.

Asymptomatic lesions in NOFs and lesions, of which bone involvement did not exceed the half of the bone diameter, were followed. These lesions are recommended to be followed since they have lower risk of pathological fractures. Since the risk of pain or pathological fracture is high in lesions, which involved more than 50% of the cortex diameter and were larger than 5 cm and located at high stress points, curettage and bone grafting is recommended for these cases. Protective internal fixation may be required in the areas where the stress is high such as the proximal femur (17).

Fibrous dysplasia can be followed conservatively, if it does not pose a risk of deformity or fracture. The risk of pathological fracture is increased in large lesions. Age of the patient, number, width and anatomical location (the region which carries the majority of the load) and biological behavior of the lesion, deformity, risk of pathological fracture and accompanying metabolic disorders (such as phosphaturia) should be considered for prophylactic fixation.

In the present study, 20 of our patients were admitted to our clinic due to the pathological fracture. Curettage and

bone grafting were performed in our all cases. Implants were used mostly in cases with lower extremity fractures. In the literature, fixation is recommended for lower extremity fractures (6,17). Fixation is recommended in impending fractures particularly in cases such as femur proximal involvement.

Mostly recurrence and wound site problems were seen as complications in cases with tumor-like bone cysts which were treated with curettage and bone grafting. In total, 40 complications were developed in 31 of 93 cases. Osteomyelitis developed in two of the five cases who were infected. Fracture was observed in one of three cases intraoperatively, and in two cases postoperatively. After the treatment, one of two cases had a shortening of 6 cm in his/her height, and the other case had 3 cm shortening. Coxa vara was developed in a case with FD. In the other studies, mostly recurrence and wound site problems have been developed (5,6,8,17). Complications in our study was found to be similar with the literature.

Postoperative first year radiographies of 78 cases, to whom cement was not used, were evaluated. According to the Neer/Cole classification, seven cases were observed to have Grade 4 recurrence. Recurrence was observed in 7.5% of the 93 cases. In conclusion, these cases were re-operated. A case with UBC was operated 3 times. Of the cases that developed Grade 4 recurrence, three had UBC, three had ABC and one had NOF whereas no recurrence was observed in FD cases. Accordingly, recurrence was observed in 14.3% (three cases) of the 21 cases with UBC; 13.6% (three cases) of the 22 cases with ABC; and 2.9% (one case) of the 35 cases with NOF. No recurrence was observed to be developed in 15 cases with FD. When we look at the literature, high recurrence rates (30%) have been reported in UBCs after curettage and bone grafting (9). Capanna (10) reduced the recurrence rate to 13.5% with the steroid injection technique, and reported the risk factors for relapse as multiloculation, cyst size and age of the patient. In ABC cases, 20% recurrence has been reported in marginal excision (13,14). Almost all of the ABCs are recovered with curettage and bone grafting (sometimes embolization may be required); however, 10 to 15% recurrence has been reported.

Papagelopoulos et al. (31) reported that adjuvant radiotherapy may be required in aggressive pelvis and sacrum in ABCs, and recurrences may be retained in 15%. In a study by Gibbs et al. (32), the cortex was cleaned with a burr drill in addition to the curettage and bone grafting, and the recurrence rate was reported as 10%, and patients with open physes were reported as the greatest risk factor for this recurrence. George et al. (33), who injected ethibloc into the cyst, published a successful long follow-up series with 58% complete recovery, 35.5% partial recovery, and 6.5% recurrence. In addition to the curettage and bone grafting, they also used argon beam coagulation as an adjuvant, and reported that they did not found any recurrence (34). Therefore, recurrence was very common after the intra-lesional curettage and bone

grafting interventions (35). No recurrence was observed in our patients with FD who were operated in our clinic.

Conclusion

In conclusion, tumor-like bone cysts were found to be in consistent with the literature in terms of their diagnosis, treatment and complications in our study. The only difference is that the cases, which were diagnosed incidentally in previous studies, were symptomatic in our study. This can be explained by that the symptomatic cases are mostly referred to our center, since our hospital is a third stage hospital in a central place. Even if different methods are used in the literature, patients are mainly treated with curettage and bone grafting in our centers, and our recurrence rate is relatively low, compared to the literature. Based on our study results, we suggest that curettage and bone grafting are successful treatment protocols in patients with tumor-like bone cysts in long bones.

References

1. Enneking WF. Musculoskeletal tumor surgery, New York: Churchill Livingstone, 1983; 1:20
2. Pettersson H, Springfield DS, Enneking WF. Radiologic management of musculoskeletal sarcoma. Clin Orthop 1980;153:106.
3. Enneking WF, Spanier SS, Goodman MA. A system for the surgical staging of musculoskeletal sarcoma. Clin Orthop Relat Res 1980;(153):106-20.
4. Aboulafia, A.J., Kennon, RE, Jelinek, JS. Benign bone tumors of childhood. J Am Acad Orthop Surg 1999;7(6):377-88.
5. Düzgün F, Örgüç Ş, Çocuklarda benign ve malign kemik tümörleri. Celal Bayar Üniversitesi Tıp Fakültesi, Radyoloji Ana Bilim Dalı, Manisa. Selçuk Pediatri 2014;2(1):106-17.
6. Çullu E, Çocuk Ortopedisi, Türk Ortopedi ve Travmatoloji Birliği Derneği, 2012; 2:978.
7. Herring JA. Selim muskuloskeletal tümörler, çeviri Erol B., Tachdjian's Pediatric Orthopaedics 2002; 3: 4
8. Özbarlas S. Basit ve anevrizmal kemik kistleri (simple and aneurysmal bone cysts), Özel Ortopedia Hastanesi, Adana, TOTBİD Dergisi, 2013;(12):539-46.
9. Campanacci M, Capanna R, Picci P. Unicameral and aneurysmal bone cysts. Clin Orthop Relat Res 1986;(204):25-36.
10. Capanna R, Dal Monte A, Gitelis S, Campanacci M. The natural history of unicameral bone cyst after steroid injection. Clin Orthop Relat Res 1982;(166):204-11.
11. Dabezies EJ, D'Ambrosia RD, Chuinard RG, Ferguson AB Jr. Aneurysmal bone cyst after fracture. A report of three cases. J Bone Joint Surg Am 1982;64(4):617-21.
12. Kransdorf MJ, Sweet DE. Aneurysmal bone cyst: concept, controversy, clinical presentation, and imaging. AJR Am J Roentgenol 1995;164(3):573-80.
13. Brastianos P, Gokaslan Z, McCarthy EF. Aneurysmal bone cysts of the sacrum: a report of ten cases and review of the literature. Iowa Orthop J 2009;29:74-8.
14. Marcove RC, Sheth DS, Takemoto S, Healey JS. The treatment of aneurysmal bone cyst. Clin Orthop Relat Res 1995;(311):157-63.
15. Arkun R, Argin M. Pitfalls in MR imaging of musculoskeletal tumors. Semin Musculoskelet Radiol 2014;18(1):63-78.
16. Smith SE, Kransdorf MJ. Primary musculoskeletal tumors of fibrous origin. Semin Musculoskelet Radiol 2000;4(1):73-88.
17. Dabak N, Multidisipliner yaklaşımla Kemik ve Yumuşak Doku Tümörleri, Ortopedi ve Travmatoloji Derneği Birliği 2013; 5: 4
18. Biermann JS. Common benign lesions of bone in children and adolescents. J Pediatr Orthop 2002;22(2):268-73.

19. Shah ZK, Peh WC, Koh WL, Shek TW. Magnetic resonance imaging appearances of fibrous dysplasia. *Br J Radiol* 2005;78(936):1104-15.
20. Oppenheim WL, Galleno H. Operative treatment versus steroid injection in the management of unicameral bone cysts. *J Pediatr Orthop* 1984;4(1):1-7.
21. Farber JM, Stanton RP. Treatment options in unicameral bone cysts. *Orthopedics* 1990;13(1):25-32.
22. Bovill DF, Skinner HB. Unicameral bone cysts. A comparison of treatment options. *Orthop Rev* 1989;18(4):420-7.
23. Pentimalli G, Tudisco C, Scola E, Farsetti P, Ippolito E. Unicameral bone cysts – comparison between surgical and steroid injection treatment. *Arch Orthop Trauma Surg* 1987;106(4):251-6.
24. Bensahel H, Jehanno P, Desgrippes Y, Pennecot GF. Solitary bone cyst: controversies and treatment. *J Pediatr Orthop B* 1998;7(4):257-61.
25. Cho HS, Oh JH, Kim HS, Kang HG, Lee SH. Unicameral bone cysts: a comparison of injection of steroid and grafting with autologous bone marrow. *J Bone Joint Surg Br* 2007;89(2):222-6.
26. Chang CH, Stanton RP, Glutting J. Unicameral bone cysts treated by injection of bone marrow or methylprednisolone. *J Bone Joint Surg Br* 2002;84(3):407-12.
27. Tsuchiya H, Abdel-Wanis ME, Uehara K, Tomita K, Takagi Y, Yasutake H. Cannulation of simple bone cysts. *J Bone Joint Surg Br* 2002;84(2):245-8.
28. Chuo CY, Fu YC, Chien SH, Lin GT, Wang GJ. Management strategy for unicameral bone cyst. *Kaohsiung J Med Sci* 2003;19(6):289-95.
29. de Sanctis N, Andreacchio A. Elastic stable intramedullary nailing is the best treatment of unicameral bone cysts of the long bones in children: Prospective long-term study. *J Pediatr Orthop* 2006;26(4):520-5.
30. Donaldson S, Chundamala J, Yandow S, Wright JG. Treatment for unicameral bone cysts in long bones: an evidence based review. *Orthop Rev (Pavia)* 2010;2(1):e13.
31. Papagelopoulos PJ, Choudhury SN, Frassica FJ, Bond JR, Unni KK, Sim FH. Treatment of aneurysmal bone cyst of the pelvis and sacrum. *J Bone Joint Surg Am* 2001;83-A(11):1674-81.
32. Gibbs CP Jr, Hefele MC, Peabody TD, Montag AG, Aithal V, Simon MA. Aneurysmal bone cyst of the extremities. Factors related to local recurrence after curettage with high-speed burr. *J Bone Joint Surg Am* 1999;81(12):1671-8.
33. George HL, Unnikrishnan PN, Gak NK, Sampath JS, Bass A, Bruce CE. Long-term follow-up Ethibloc injection in aneurysmal bone cysts. *J Pediatr Orthop B* 2009;18(6):375-80.
34. Cummings JE, Smith RA, Heck RK Jr. Argon beam coagulation as adjuvant treatment after curettage of aneurysmal bone cysts: a preliminary study. *Clin Orthop Relat Res* 2010;468(1):231-7.
35. Gennari JM, Merrot TH, Piclet/Legre B, Bergoin M. The choice of treatment for simple bone cysts of the upper third of the femur in children. *Eur J Pediatr Surg* 1996;6(2):95-9.