



Rare Translocations in Two Newborns with Down Syndrome

Emine Yaşar¹, Cemal Ekici, Serap Savacı, Serdar Karatoprak, İbrahim Tekedereli

İnönü University, Faculty of Medicine, Department of Medical Biology and Genetics, Malatya, Turkey

Abstract

Trisomy 21 is the most common chromosomal aneuploidy in humans with a frequency of about 1:700 live births. Free trisomy 21 constitutes about 95% of all cases, also known as standard Down syndrome. Nonclassic trisomies constitutes 5% and within this group almost half have 14/21 while the remainder carry 21/21, 15/21, and other Robertsonian translocations and mosaic trisomies. Although there are no phenotypic differences between standard and translocation trisomy 21, the latter could be the result of the possibility that one of the parents is a carrier for translocation. Therefore, parents' karyotypes should be evaluated in such cases. In this study, we report the process of diagnosis, comorbid conditions, and genetic counseling in two newborn patients with Down syndrome in the light of current literature.

Keywords: Trisomy 21; Translocation; Genetic Counseling.

Down Sendromlu İki Yenidoğanda Nadir Translokasyonlar

Özet

Trizomi 21, insanlarda en sık görülen kromozomal anöploidi olup sıklığı yaklaşık olarak 700 canlı doğumda 1'dir (1:700). Olguların %95'i klasik tip Down sendromu olup, fazla olan 21. kromozom serbesttir. Kalan vakaların yaklaşık yarısı 14/21 translokasyonu ile meydana gelirken, yarısını ise 21/21, 15/21 gibi diğer Robertsonian tipi translokasyonlar ve mozaik trizomiler oluşturur. Klasik ya da translokasyon tipi Down sendromu arasında fenotipik fark olmamasına rağmen, translokasyon tipi Down sendromunda ebeveynlerin taşıyıcı olma ihtimali gözönüne alınarak, anne-baba kromozom analizi yapılması gereklidir.

Bu çalışmada Down sendromu bulguları nedeni ile başvuran iki yenidoğanın tanı, komorbid durumlar ve genetik danışmanlık süreci literatür bilgileri ışığında değerlendirilerek sunulmuştur.

Anahtar Kelimeler: Trizomi 21; Translokasyon; Genetik Danışmanlık.

INTRODUCTION

Down syndrome (DS) is the most common genetic cause of mental retardation that can be determined (1). Facial features are often typical and especially accompanied minor anomalies affecting the cardiovascular and gastrointestinal systems. DS patients carry risks of many acquired medical complications like thyroid hormone disorders, hematological disorders, audiological pathologies, and respiratory and neurological conditions (2).

DS is caused by the trisomy of 21st chromosome. In 95% of the cases, the reason is usually non-disjunction which results in standard DS. The remaining 5% consists of Robertsonian translocation and mosaic DS cases (2, 3).

Robertsonian type trisomy 21 cases are rare and they are usually De novo albeit it is very rarely passed onto children when one of the parents carry rob (21; 21). Should one of the parents have rob (21;21), the parents will be phenotypically normal but the result will either be children with Down's syndrome or miscarriage (8). DS is one of the rare autosomal trisomies directly in relation with life. This has partly been explained by 21st chromosome lacking in genes. DS prevalence is directly

related to increased maternal age; the risk for DS in mothers over 40 years of age is significantly high (4). By affecting various organs and systems, DS leads to increased morbidity and mortality. For example, neonatal mortality is 4,3 times higher in DS compared to the general population while infant mortality rate is also 8,3 times more in DS. Although life expectancy is shorter than normal, average life expectancy has increased to about 50 years of age as a result of the developments in the field of medicine (5).

CASE REPORT

Case 1

A 33-day-old infant was referred to our clinic with DS findings. The patient was the third living child of unrelated parents (mother at 39 and father at 43) while the other two siblings (at 18 and 16, respectively) were in good health. The mother did not have a medical history of miscarriage or stillbirth. Upon developing annular pancreas-related intestinal obstruction within the third day of its birth, the patient had undergone duodenojejunostomy. The patient was apathetic on physical examination with a flat occiput, low nuchal hairline, short neck, open anterior fontanelle (2x2 cm), and closed rear fontanelle. We also found hypertelorism and epicanthus along with an extensive nose bridge;

nostrils had an anteverted position and the mouth was open with a palate. The patient had a surgical scar on the abdomen. In addition, the distance between the 1st and 2nd toes in the left foot was found to be increased.

Because the phenotype of the patient was compatible with DS, the echocardiography conducted for the detection of possible cardiac pathologies showed ductus opening and intermediate type AVSD. We also detected hypothyroidism in thyroid function tests. The family history informed us about a 14-year-old boy diagnosed with DS due to the marriage between two of paternal cousins.

Case 2

The patient was the first child of unrelated parents; a 39-year-old mother and a 36-year-old father. The pregnancy had not been followed and the 17-day-old infant was referred to our clinic with a preliminary diagnosis for Down syndrome due to its Mongoloid face.

The initial examination showed a microcephalic patient with an open anterior fontanelle (3x2 cm), closed rear fontanelle, low ears, small jaws, and flat and large nasal bridge with nostrils in anteverted position. The patient also had epicanthus and hypertelorism. We detected a bilateral single transverse line (simian). In addition we also detected patent foramen ovale in the echocardiographic examination and hypothyroidism in the thyroid function test. We evaluated the metaphase culture results obtained from the peripheral venous blood samples of patients suspected of Trisomy 21 and recorded them according to the international nomenclature guidelines (ISCN 2013). Examining the preparations by light microscopy, we detected 46, XY, +21, and rob (21; 21) (q10; q10) in all metaphase areas of Case 1 (Figure 1).

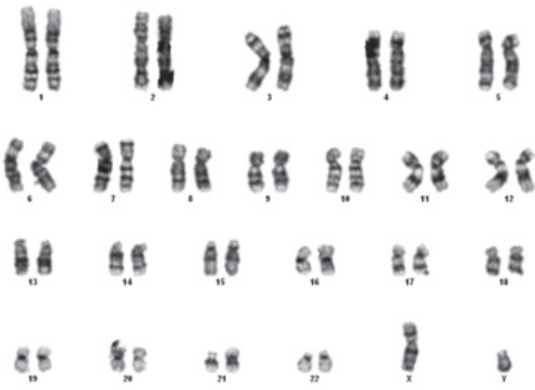


Figure 1. The karyotype image of the first case with DS.

All metaphase areas of Case 2 were evaluated as 46, XY, +21, rob (14; 21) (q10; q10) (Figure 2). Taking into account the possibility that parents might also have Robertsonian translocation, we applied chromosome analysis to the parents. Both mothers had karyotypes of 46, XX while both fathers' karyotypes were 46, XY.

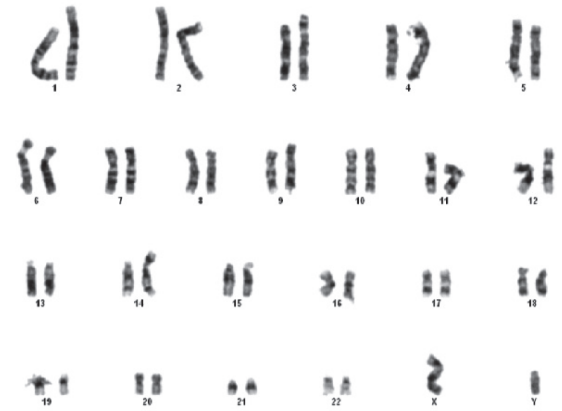

Figure 2. The karyotype image of the second case with DS.

DISCUSSION

Specifically, it is 21q22 duplication that causes Down syndrome (2). 21q22.1~21q22.3 regions, which are known as the Down syndrome critical regions (DSCR), contains genes such as SOD1, RCAN1, RUNX1, DYRK1A, GIRK2, DSCAM, and D21S44 (6). The duplication of this region usually results in the following symptoms that are frequently found in patients with Down syndrome: short stature, mental retardation, microcephaly, brachycephaly, epicanthal fold, flat nasal bridge, flat facial appearance, open mouth, high arched palate, small dysmorphic ears, short neck, brachydactyly, clinodactyly, single transverse palmar crease, and hypotonia. This critical region is also responsible from cardiac anomalies and duodenal atresia, both of which are frequently associated with DS (6). In these two comorbid conditions, heart diseases accompany DS by up to 40-50%, which is influential on survival. Perimembranous VSD, the most common associated anomaly, is followed by endocardial cushion defect, PDA, ostium primum ASD type, tetralogy of Fallot, and other abnormalities, respectively (2). Affecting 35% of newborns with DS, the second most common comorbid condition is duodenal atresia. Hirschsprung's disease, duplication cysts, and anal stenosis are also common with duodenal atresia and they all require timely and correct treatment (2). The following conditions may accompany DS: mental retardation, seizures, stereotypic movements, early onset Alzheimer's, neurological symptoms such as hypotonia, hypothyroidism, testicular insufficiency, bilateral undescended testes, increased levels of LH and FSH, endocrine problems such as decreased bone mineral density, hypoplastic iris, Brushfield spots, congenital cataracts, amblyopia, ophthalmic pathologies such as accommodation of weakness; eustachian tube dysfunction, cochlear duct hypoplasia, audiological findings such as transmission issues and mixed hearing losses, scoliosis, hallux valgus, pes planus, musculoskeletal complaints problems like joint laxity, and oral and dental problems such as delayed milk teeth, microdonty, taurodontism (having teeth with broad and vertical pulp chambers, short stems, roots longer than teeth bodies), poor chewing, teeth grinding, and maxillary asymmetry. Besides DS

patients also carry increased risk of learning difficulties, communication problems, increased depression, psychosis, and a markedly high risk of leukaemia (2).

Kallen et al's study on 5581 children with Down syndrome has shown that DS increases the annular pancreatic risk 300-fold compared to normal population (9). Annular pancreas is a very rare pathology among health population but our first patient had annular pancreas and was operated for this problem. In a study conducted by Roberts et al., it has been put forward that the risk of congenital hypothyroidism in children with Down syndrome is 35 times higher than the normal population (10). Both of our cases had hypothyroidism and DS patients with hypothyroidism must be under lifetime monitoring. Sometimes hormonal values of these patients may improve but they can still catch hypothyroidism due to their susceptibility to autoimmune diseases.

The two DS patients we have presented here are consistent with the literature as they had concomitant hypothyroidism, congenital heart diseases, typical facial features, and annular pancreas. However, both of cases have come to life due to two rare translocations. Translocations are the most frequent chromosomal rearrangements in humans. Robertsonian translocations (rob) are made of the fusion two acrocentric chromosomes and their incidence is 1 in 1000 live births (1:1000). In DS, only 2-4% of cases are formed in this way. The most common Robertsonian translocations in DS are rob (14;21) and rea (21; 21). These translocations do not affect patient's phenotype or clinical picture but the risk of recurrence in subsequent pregnancies is high if translocation source is either of the parents. Recurrence risk of rea (21;21) is 100% in every pregnancy (8). In translocations of the 21st chromosome with other afrocentric chromosomes, the risk is still higher than the general population by 5% if one of the parents is a carrier (5). For this reason, in Down syndrome patients with Robertsonian translocation especially, parents' karyotypes should be considered; if needed, karyotypes of siblings can also be examined. If

one of the parents is a rob carrier, parents must be offered a preimplantation genetic diagnosis; if this option fails, practitioners must prefer a prenatal diagnosis (7).

In both of the cases presented, we provided the families with genetic counselling by explaining DS, its probable causes, accompanying diseases, risk of recurrence in subsequent pregnancies and we added them to our follow-up patient lists.

REFERENCES

1. Antonarakis S. Ten years of genomics chromosome 21 and DS. *Genomics* 1998;51:1-16.
2. Alasdair G.W. Hunter. *Management of Genetic Syndromes*, Third Edition, Edited by Suzanne B. Cassidy and Judith E. Allanson 2010;23:309-32.
3. Shaffer LG, McCaskillCh, Haller V, Brown JA, Jackson-Cokk CK. Further characterization of 19 cases of rea (21q;21q) and delinination as isochromosomes of Rob. *Translocation in DS. Am J. Med. Genetics* 1993;47:1218-22.
4. Ceylan G, Erol D, Yüce H. Denevo 21/21 Translokasyonu Olan Down Sendromlu İki Olgu: Literatür Araştırması. *Firat Tıp Dergisi* 2009;14(4):280-2.
5. Dieter K, Albert S. Paternal meiotic origin of der(21;21)(q10;q10) mosaicism [46,XX/46,XX,der(21;21)(q10;q10), + 21] in a girl with mild Down syndrome. *European Journal of Human Genetics* 2000;(8):709-12.
6. Park J, Chung KC. New Perspectives of Dyrk1A Role in Neurogenesis and Neuropathologic Features of Down Syndrome. *Exp Neurobiol* 2013 Dec;22(4):244-8.
7. Scriven PN, Flinter FA, Braude PR, Ogilvie CM. Robertsonian translocations-reproductive risks and indications for preimplantation genetic diagnosis. *Hum Reprod* 2001;16:2267-73.
8. Kolgeci S1, Azemi M, Ahmeti H, Dervishi Z, Sopjani M, Kolgeci J. Recurrent abortions and down syndrome resulting from Robertsonian translocation 21q; 21q. *Med Arch.* 2012;66(5):350-2.
9. Källén B1, Mastroiacovo P, Robert E. Major congenital malformations in Down syndrome. *Am J Med Genet.* 1996 Oct 16;65(2):160-6.
10. Roberts HE, Moore CA, Fernhoff PM, Brown AL, Khoury MJ. Population study of congenital hypotiroidism and associated birth defects, *Am. J. Med. Genet.* 1997;71:29-32.

Received/Başvuru: 03.08.2014, Accepted/Kabul: 134.10.2014

Correspondence/İletişim

Emine YAŞAR
İnönü Üniversitesi Tıp Fakültesi, Tıbbi Biyoloji ve Genetik
Anabilim Dalı, MALATYA, TÜRKİYE
E-mail: emineyasar1042@gmail.com

For citing/Atf için

Yasar E, Ekici C, Savaci S, Karatoprak S, Tekedereli I. Rare translocations in two newborn with down syndrome. *J Turgut Ozal Med Cent* 2015;22:194-6
DOI: 1 0.7247/jtomc.2014.2353