

Important considerations in the echocardiographic assessment of tricuspid regurgitation and right ventricular function

Julide Akaycan¹, Siho Hidayet¹, Zeynep Ulutas², Yucel Karaca¹

¹Inonu University, Faculty of Medicine, Department of Cardiology, Malatya, Turkey

²Elazig State Hospital, Clinic of Cardiology, Elazig Turkey

Copyright © 2020 by authors and Annals of Medical Research Publishing Inc.

Abstract

Tricuspid regurgitation (TR) and right ventricular dysfunction, which have been traditionally underemphasized, are known to be associated with increased morbidity and mortality, particularly in patients undergoing left-sided cardiac valvular surgery. Echocardiographic assessments are of utmost importance in terms of timely management and proper patient selection. In this review, our aim was to assess tricuspid failure as well as right ventricular functions using echocardiography.

Keywords: Echocardiography; right ventricle; tricuspid regurgitation

INTRODUCTION

Tricuspid regurgitation (TR) and right ventricular dysfunction, which have been traditionally underemphasized, are known to be associated with increased morbidity and mortality, particularly in patients undergoing left-sided cardiac valvular surgery. In this regard, echocardiographic assessments are of utmost importance in terms of timely management and proper patient selection. In this review, our aim was to assess tricuspid failure as well as right ventricular functions using echocardiography.

Evaluation of Tricuspid Regurgitation

Until recently, clinicians held the view that tricuspid regurgitation could be improved or corrected following left-sided valve surgery. However recent studies failed to demonstrate such benefits of such surgery (1). For instance, in a study involving 5200 patients with a 4-year follow-up, moderately and severe TR were found to be an independent predictor of increased mortality, regardless of left ventricular failure and pulmonary artery pressure (2). In patients undergoing left-sided cardiac valvular surgery, the 5-year survival was found to be decreased to

74% in the presence of significant tricuspid regurgitation, with further reductions in survival over time (3). In almost half of all patients with prosthetic mitral valves, significant TR develops in subsequent years (4).

Echocardiography is an important assessment tool that assists in determining timely management and proper therapeutic strategies in patients with cardiac valvular disease. Echocardiographic criteria used in both 2017 European valvular heart disease guidelines as well as in high-risk patients undergoing different types of interventional procedures in ongoing clinical studies are quite similar (5,6).

Initial echocardiographic assessments should target at determining the cause of the regurgitation (i.e. the structure of the leaflets), followed by evaluation of the severity of the regurgitation, annulus dimensions, right ventricular functions, and pulmonary artery pressure. A detailed examination of the etiology of TR shows that actually 90% of the patients have TR secondary to ventricular and annular dilatation caused by pulmonary hypertension, left-sided cardiac and valvular diseases, right ventricular dysfunction, and atrial fibrillation. On the other hand, the

Received: 28.10.2019 Accepted: 29.01.2020 Available online: 20.02.2020

Corresponding Author: Julide Akaycan, Inonu University, Faculty of Medicine, Department of Cardiology, Malatya, Turkey

E-mail: julideyagmur@hotmail.com

primary tricuspid failure results from the disruption of the structure of the leaflets and chordae. Rheumatic cardiac disorders leading to limitation of motion and thickening in the leaflets, vegetation associated with endocarditis, traumatic rupture of the chordae, thickness and fixed open position in leaflet cause by carcinoid syndrome, prolapsus of the leaflets, and pacemaker trauma which in recent years comprises nearly 30% of the primary causes of TR, are among the etiological factors associated with primary tricuspid failure.

In assessing the structure of the valve, a 3D (three-dimensional) echocardiographic examination provides detailed information regarding the problematic valves. It is almost impossible to visualize all 3 leaflets using the same window in 2D (two-dimensional) imaging studies. Inadvertent slight angular alterations of the probe may affect the process of imaging of the leaflets. In other words, we may actually be visualizing the posterior leaflet when we believe that we are visualizing the anterior leaflet. When compared with 3D multi-plane reconstruction (MPR) echocardiography, in the 4-chamber view; the septal leaflet adjacent to the septum is visualized if the left ventricular outflow into the view window, we will display the anterior leaflet and if we take the coronary sinus into the view window, we will visualize the posterior leaflet.

The anterior leaflet distant from the right ventricular inlet window (i.e. the one that is close to the aorta) may actually be the septal leaflet at the opposite wall or may be the posterior leaflet. If the septum is included in the imaging window, then the septal leaflet can be clearly discriminated. Similar difficulties may also be experienced in the parasternal short-axis window. The anterior or septal leaflet adjacent to the aorta may actually be the posterior or anterior leaflet on the opposite site. If a single leaflet is visualized through that window, inclusion of the anterior leaflet or the left ventricular outflow in the window allows visualization of the septal and posterior leaflet (7).

If 3D assessment of the leaflets is not possible, 2D imaging should always involve imaging through multiple windows. In secondary TR, dilatation of the right ventricle and annulus occur due to secondary causes, and as a result of remodeling and dilatation of the RV, the papillary muscles are displaced superiorly, chordae are stretched, leaflets fail to merge completely above the level of annulus, leading to a disarrangement in the structural associations between leaflets, annulus, chordae, papillary muscles, and the myocardium with consequent secondary TR. TR itself causes further RV dilatation and dysfunction, initiating a vicious cycle.

The annulus is a non-planar 3-dimensional oval and saddle shaped structure that has two superior parts extending to the right atrium and two inferior parts that extend to the apex. As the annulus starts to expand, its expansion occurs in the direction of the antero-posterior leaflet due to the fixed position of the septal part, giving it a more planar and circular form. The dimensions of the annulus are related to the severity of the TR, even to the extent that in patients scheduled for surgery due to left

valvular disease, the degree of annular dilatation carries more significance than the severity of the regurgitation itself. The annular dimensions are measured at the end of the diastole using the apical 4-chamber view (septal-lateral) allowing good visualization of the right-ventricle focused free wall. Particularly in patients referred for left valvular surgery, a measurement over 40 mm or 21 mm/m² based the body surface area (BSA) are considered significant. However, if the distance between the annulus and the tips of the leaflets is > 8 mm and the tenting area is > 1.6 cm, annuloplasty alone does not suffice, and concomitant valve strengthening surgery is required (8). 2D measurements may not be accurate due to the non-planary shape of the annulus. If available, 3D imaging should be preferred, especially for patients undergoing surgery, in order to gauge the actual width of the annulus as well as the tenting volume (9).

2017 American Guideline for the Management of Patients with Valvular Heart Disease recommends the use of quantitative measurements of the vena contracta, effective regurgitant orifice area, and regurgitant volume, particularly in patients where qualitative methods are inconclusive (10).

Findings suggestive of advanced TR include a valvular entry wave greater than 1 cm/sec with pulsed wave Doppler, systolic regurgitation of the hepatic vein in the subcostal vein, and early peaking of the failure jet with marked triangular shape due to pressure equalization as evidenced by continuous flow Doppler examination. Also, in color Doppler, marked color flow in the right atrium along the systole as well as a color flow area of greater than 10 cm² are supportive of severe TR (Figure 1).

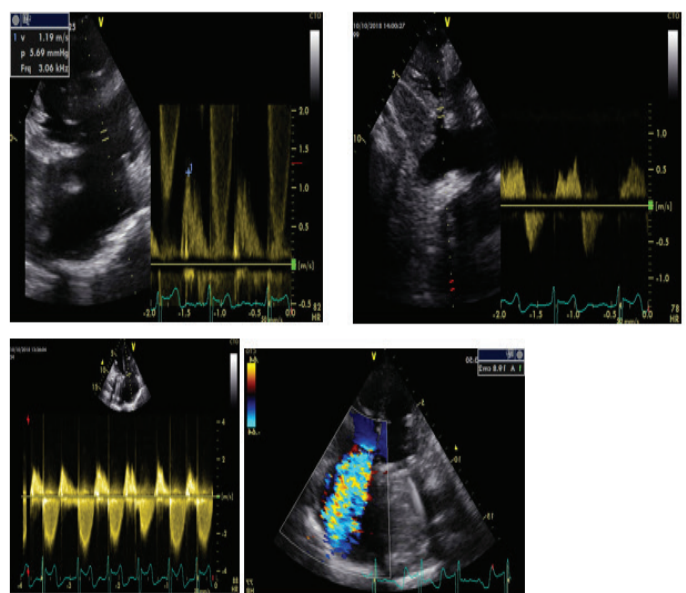


Figure 1. Echocardiographic examples of severe TR; a valvular entry wave greater than 1 cm/sec with pulsed wave doppler , systolic reversal of hepatic vein flow , early peaking of the failure jet with marked triangular shape, a color flow area of greater than 10 cm²

Vena contracta, which is the narrowest part of the failure flow at the level of the valve, can be rapidly and easily measured. A measurement exceeding 7 mm is suggestive of severe TR. However, multiple color flow recordings and non-circumferential orifices may lead to misleading measurements. Orifice is rarely circular in TR due to secondary causes. A 3D examination actually shows an oval or star shaped appearance of the orifice (9). Vena contracta surface measurements performed with 3D imaging provides much more accurate information than 2D imaging. Vena contracta area $> 40 \text{ mm}^2$ shows the presence of advanced TR. Proximal Isovelocity Surface Area (PISA) represents another important measurement tool, which is carried out by reducing the color scale to 15-40 cm/sec in the direction of the flow velocity at the mid-systole in apical 4-chamber views. The failure peak flow rate is measured using continuous Doppler in order to calculate the failure volume and effective regurgitant orifice area. An EROA $\geq 40 \text{ mm}^2$ and a regurgitant volume $>45 \text{ mL}$ also suggest severe TR (Figure 2).

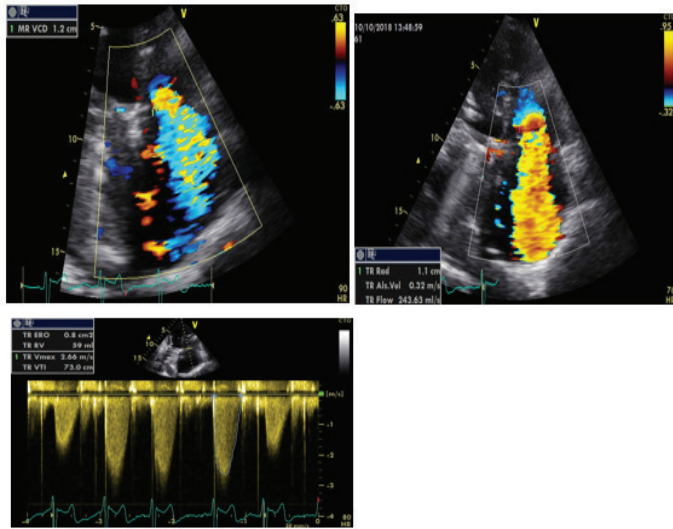


Figure 2. In the severe central TR, the VC is $> 7 \text{ mm}$, an EROA greater than 40 mm^2 and an RVol greater than 45 mL

Similarly, 3D can also be used under this circumstances, since the orifice of the failure is not circumferential. respiratory activity increases blood flow and decreases failure flow jet, leading to variability in PISA according to the phase of respiration. Thus, average of several measurements must always be obtained.

Right Ventricular Assessment

Three dimensional anatomical structure of the right ventricle is complex and consists of three parts, namely the inlet, apex, and outlet that are perpendicular to each other. Due to intense trabeculation, endocardial delineation is challenging. The image quality is poor due to its course behind the sternum and is affected by volume loads. Therefore, assessment of both the structure and functions of the right ventricle using 2D echocardiography is very difficult.

Two guidelines have been issued for the assessment of the right ventricle, one in 2010, and another in 2015 with modifications in certain measurements (11,12). Initial assessment is visual. Visual assessment of the RV size may be performed from the apical four-chamber view using an approximation that the area of normal RV should not exceed two-thirds of the LV. It is worth noting that this assumption may be misleading in patients with LV dilatation. In parasternal short axis views, we may roughly assume the presence of RV volume or pressure load if the interventricular septum is straightened and if the left ventricle assumes a D shape. Straightening occurring at the end of the diastole is suggestive of volume overload, while that occurring at the end of the systole is more suggestive of pressure overload.

Dilation of right ventricle is a prerequisite for quantitative echocardiographic assessment. Varying measurements may be obtained in the apical 4-chamber window due to slight angulation of the probe. The guidelines recommend an end-diastolic measurement in the apical 4-chamber window, right ventricle focused measurements for the assessment of the right ventricle. Again, in the apical 4-chamber view, the guidelines recommend measurement of the basal, mid-cavitary, and longitudinal diameters of the right ventricle; also, the right ventricular outflow tract (RVOT) should be measured in the parasternal long and short axis windows. Normal RV measurements in 2D echocardiography are as follows: basal apex length $< 8.6 \text{ cm}$, midcavitary diameter $< 3.5 \text{ cm}$, basal diameter $< 4.2 \text{ cm}$, RVOT parasternal short axis $< 2.7 \text{ cm}$, RVOT parasternal long axis $< 3.3 \text{ cm}$. Values exceeding these show dilation of the right ventricle.

How to Assess Systolic Functions of The Right Ventricle?

Guidelines recommend the simultaneous use of comprehensive and multiple parameters for the assessment of the right ventricle, in order to increase the diagnostic accuracy. The first measurement involves the tricuspid annular plane systolic excursion (TAPSE), which is a simple and commonly used variable showing the longitudinal contraction of the right ventricle in a regional manner. Values below 17 mm show the presence of right ventricular dysfunction (Figure 3). This parameter is dependent on the angular and volume load and is affected by cardiac movements. In severe tricuspid regurgitation, this value may be elevated even if right ventricular functions are impaired.

Another method involves the systolic wave (S') measurement obtained at the tricuspid lateral side level using tissue Doppler. It is a simple, reproducible, and reliable parameter with respect to right ventricular systolic functions. Care should be exercised to place the circle as parallel as possible to the Doppler beam. A value below 9.5 cm/sec show the presence of dysfunction (Figure 4).

Myocardial performance index (Tei index) has been introduced as a simple parameter that reflects both systolic and diastolic cardiac functions and that correlates

well with invasive measurements. It is derived by dividing the isovolemic contraction and relaxation times by the ejection time, and is affected by the volume load. In patients with severe tricuspid failure and if the right atrial pressure is high, this measurement may be misleadingly low. Therefore, it is recommended that Tei index be used in conjunction with other methods, rather than as a standalone technique. It may be measured with pulsed or tissue Doppler. Normal Tei index is < 0.40 and < 0.54 with pulsed Doppler and tissue Doppler, respectively (Figure 5).

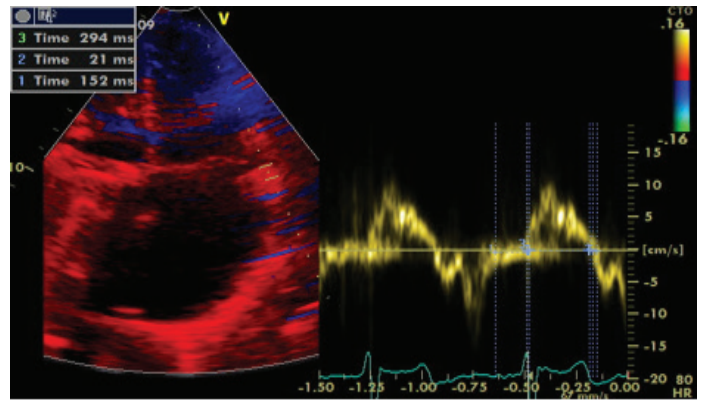


Figure 5. Myocardial performance index is 0.58 (>0.54)

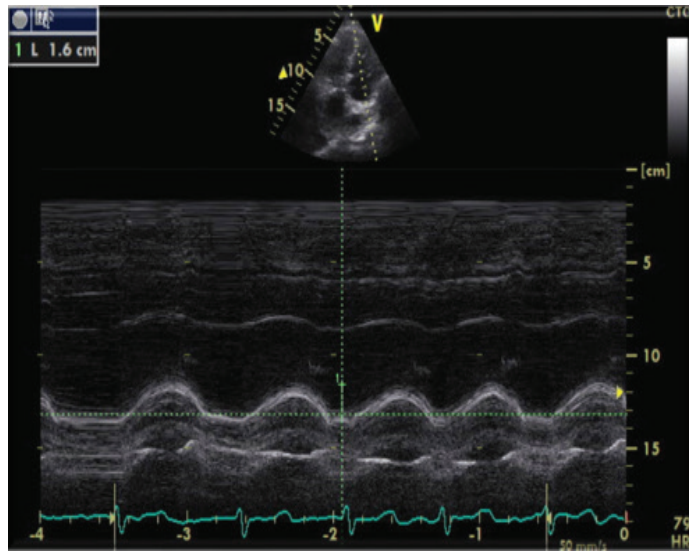


Figure 3. TAPSE measurement using M-mode methodology

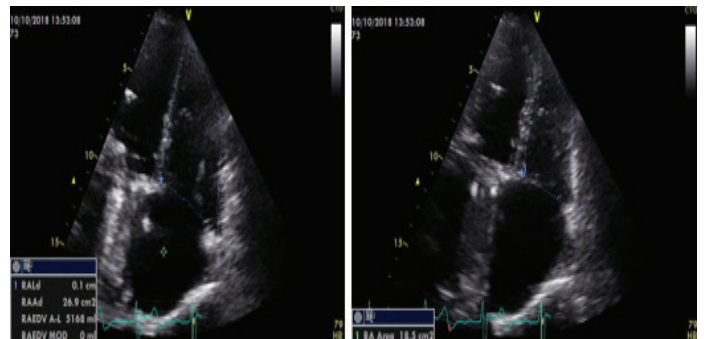


Figure 6. Fractional area change is = (26.9-18.5/26.9)x100= %31 (<%35)

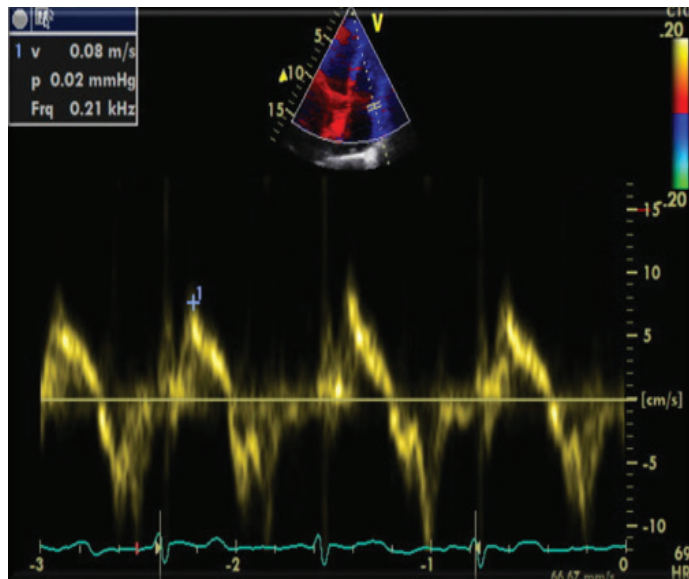


Figure 4. Pulsed tissue Doppler S' wave (cm/s)

Fractional area change is obtained on the basis of end-diastolic and end-systolic area calculations. It evaluates the global right ventricular systolic function, although it disregards the ventricular outflow tract. A good image window is required, as the endocardial delineation is challenging. A value below 35% shows systolic RV dysfunction (Figure 6). Routine clinical use is recommended.

2 dimensional speckle-tracking is a method developed for the quantitative assessment of the global and regional myocardial performance that shows the percentage and the velocity of systolic shortening in the free wall and septum of the right ventricle (from basal to apex, 3 or 6 segments). It is independent of the cardiac motility and examines the regional myocardial deformation of different right ventricular segments. It may difficult to mark due to thinness of the RV wall. Speckles should include the myocardium and exclude the pericardium. It is a predictor of survival in patients with pulmonary hypertension. A free wall tension of less than -20% shows the reduced right ventricular function (Figure 7).

For the assessment of right ventricular volume, 3D imaging is recommended rather than 2D images. It is the only method that shows the right ventricular global systolic function as it also includes the RVOT. Studies have shown equivalence of 3D echocardiography and the gold standard method, i.e. magnetic resonance imaging, in the assessment of the right ventricular functions. According to the guidelines, volume assessment with 3D echocardiography is recommended if there is enough expertise in such measurements. Also, reference values for right ventricular volumes according to age, gender, and body surface area have been specified. A right ventricular EF < 45% shows systolic dysfunction. However, for 3D imaging, good imaging quality as well as special software are required. Based on 3D echocardiographic analysis of the right ventricle, an end-diastolic RV diameter of 87

ml/m² and 74 ml/m² in men and women, and an end-systolic RV diameter of 44 ml/m² and 36 ml/m² in men and women are considered as the upper limit of normal, respectively (Figure 8).

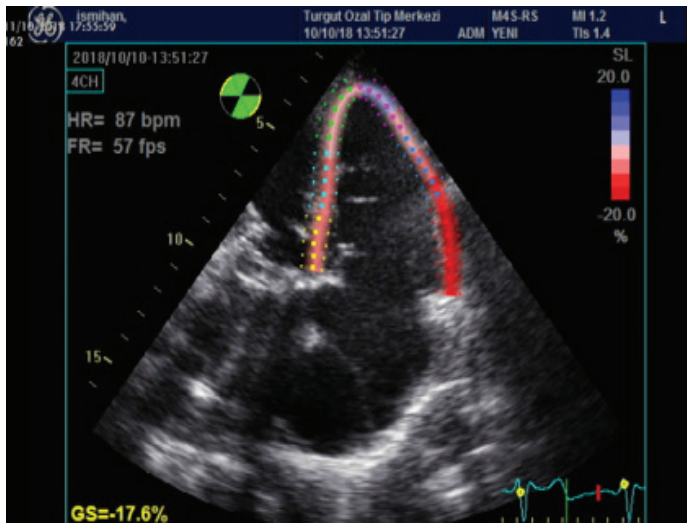


Figure 7. Global systolic longitudinal strain (LS) of the right ventricular (RV) free wall and interventricular septum obtained with two-dimensional speckle-tracking analysis

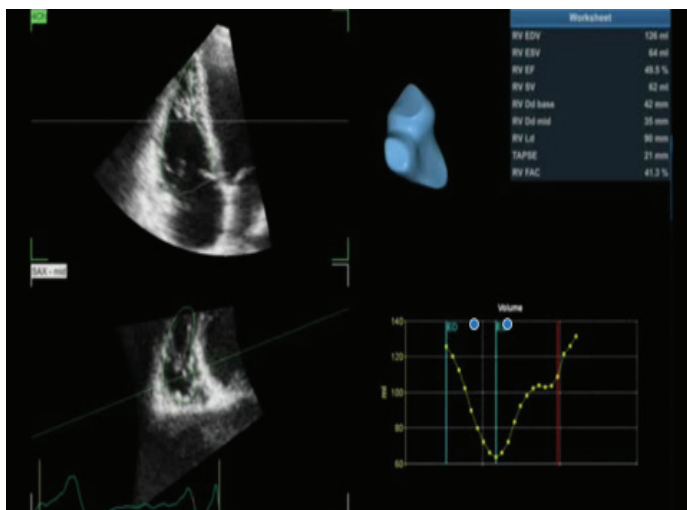


Figure 8. A three-dimensional data set of the right ventricle volumes

Assessment Of The Right Atrium

Guidelines recommend area, length, and volume measurements obtained from apical four-chamber window. The normal right atrial volumes in women and men are 21 ± 6 ml/m² and 25 ± 7 ml/m², respectively. Also, a RA area > 18 cm² is associated with severe TR and dilation of the annulus (Figure 9).

Pulmonary Artery Pressure

PAP can be calculated for TR, pulmonary regurgitation or pulmonary acceleration time. However, since the pressure between the right atrium and right ventricle are equalized in advanced TR, the TR flow velocity will be underestimated.

Also, the right atrial pressure should be added using the inferior vena cava diameter and inspiratory collapse rate, rather than the sole use of estimations.

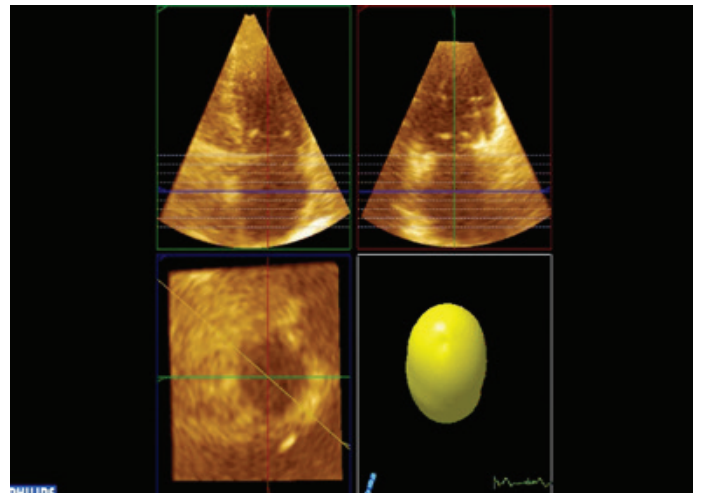


Figure 9. A three-dimensional data set of the right atrial volume

CONCLUSIONS

Annular diameter, pulmonary artery pressure, and right ventricular width as well as the function should be taken into consideration in addition to the sole use of the grading of the failure in assessing the tricuspid regurgitation. 3D imaging provides better information on the structure of the leaflets and also represents a more reliable method, particularly for assessing annulus width and grading of secondary TR. Since the traditional 2D echocardiography presents certain challenges in the evaluation of the structure and function of RV, methods such as 3D echocardiography and 2D speckle-tracking echocardiography will provide more reliable results.

Competing interests: The authors declare that they have no competing interest.

Financial Disclosure: There are no financial supports.

Ethical approval: No consent of ethics.

Julide Akaycan ORCID: 0000-0002-9174-6777

Siho Hidayet ORCID: 0000-0002-4103-9345

Zeynep Ulutas ORCID: 0000-0001-6078-7480

Yucel Karaca ORCID: 0000-0002-5184-5308

REFERENCES

- Braunwald NS, Ross J Jr, Morrow AG. Conservative management of tricuspid regurgitation in patients undergoing mitral valve replacement. *Circulation* 1967;35:63-9.
- Nath J, Foster E, Heidenreich PA. Impact of tricuspid regurgitation on long-term survival. *J Am Coll Cardiol* 2004;43:405-9.
- Lee JW, Song JM, Park JP, et al. *Circ J* 2010;7:375-80.
- Kara I, Koksall C, Erkin A, et al. Outcomes of Mild to Moderate Functional Tricuspid Regurgitation in Patients Undergoing Mitral Valve Operations: A

- Meta-Analysis of 2,488 Patients. *Ann Thorac Surg* 2015;100:2398-407.
5. Falk V, Baumgartner H, Bax JJ et al. 2017 ESC/EACTS Guidelines for the management of valvular heart disease. *Eur J Cardiothorac Surg* 2017;52:616-64.
 6. Asmarats L, Puri R, Latib A, et al. Transcatheter Tricuspid Valve Interventions: Landscape, Challenges, and Future Directions. *J Am Coll Cardiol* 2018;71:2935-56.
 7. Addetia K, Yamat M, Mediratta A, et al. Comprehensive Two-Dimensional Interrogation of the Tricuspid Valve Using Knowledge Derived from Three-Dimensional Echocardiography. *J Am Soc Echocardiogr* 2016;29:74-82.
 8. Dreyfus GD, Raja SG, John Chan KM. Tricuspid leaflet augmentation to address severe tethering in functional tricuspid regurgitation. *Eur J Cardiothorac Surg* 2008;34:908-10.
 9. Muraru D, Surkova E, Badano LP. Revisit of Functional Tricuspid Regurgitation; Current Trends in the Diagnosis and Management. *Korean Circ J* 2016;46:443-55.
 10. William A. Zoghbi, David Adams, et al. Recommendations for Noninvasive Evaluation of Native Valvular Regurgitation. *J Am Soc Echocardiogr* 2017;30:3.
 11. Rudski LG, Lai WW, Afilalo J, et al. Guidelines for the echocardiographic assessment of the right heart in adults: a report from the American Society of Echocardiography endorsed by the European Association of Echocardiography, a registered branch of the European Society of Cardiology, and the Canadian Society of Echocardiography. *J Am Soc Echocardiogr* 2010;23:685-713.
 12. Lang RM, Badano LP, Mor-Avi V, et al. Recommendations for cardiac chamber quantification by echocardiography in adults: an update from the American Society of Echocardiography and the European Association of Cardiovascular Imaging. *Eur Heart J Cardiovasc Imaging*. 2015;16:233-70.