

Surgical intervention for traumatic facial paralysis: an analysis of 15 patients

Elif Baysal¹, Secaattin Gülşen², İsmail Aytaç², Sercan Çıkrıkçı², Burhanettin Gönüldaş²,
Cengiz Durucu², Semih Mumucu², Muzaffer Kanlıkama²

¹Department of Otorbinolaryngology, Faculty of Medicine, İnönü University, Malatya, Turkey

²Department of Otorbinolaryngology, Faculty of Medicine, Gaziantep University, Gaziantep, Turkey

Abstract

Objective: The aim of the present study was to analyze patients who underwent facial nerve decompression.

Methods: A retrospective data analysis was performed on 15 patients operated between January 2005 and January 2015. All patients were evaluated with high-resolution temporal computed tomography, House-Brackmann grading system, and electrodiagnostic tools (electromyography or electroneurography).

Results: There were 8 female and 7 male patients with a mean age of 20.56 (range: 2 to 59) years. All of the patients underwent facial decompression surgery via a transmastoid approach.

Conclusion: Transmastoid approach in patients with facial nerve injuries within the first genu and the digastric ridge is appropriate, and the increase in the amplitude observed in the postoperative EMG records obtained from musculus orbicularis oculi may be considered as significant indicator of nerve recovery that occurs before clinical improvement.

Keywords: Traumatic facial paralysis, transmastoid approach, electromyography.

Özet: Travmatik fasiyal paraliziye yönelik cerrahi: 15 hastanın analizi

Amaç: Bu çalışmanın amacı fasiyal sinir dekompresyonu yapılan hastaları analiz etmektir.

Yöntem: 2005 Ocak – 2015 Ocak tarihleri arasında cerrahi geçiren 15 hastanın verileri geriye dönük incelendi. Bütün hastalar yüksek rezolüsyonlu temporal tomografi, House-Brackmann derecelendirme sistemi, elektrodagnostik testler elektromiyografi ya da elektronörografi ile değerlendirilmiştir.

Bulgular: Çalışmaya yaş ortalaması 20.56 (aralık: 2–59) yıl olan 8 kadın ve 7 erkek hasta katılmıştır. Hastaların tümüne transmastoid yolla fasiyal dekompresyon uygulanmıştır.

Sonuç: Transmastoid yaklaşım fasiyal sinir birinci dirseği ve digastric ridge arasında hasar olanlarda uygun olmaktadır. Postoperatif elektromiyografi bulgularındaki orbikularis okuli kasındaki amplitüd artışı klinik iyileşme öncesinde sinirdeki iyileşmenin anlamlı indikatörü olarak bulunmuştur.

Anahtar sözcükler: Travmatik fasiyal paralizi, transmastoid yaklaşım, elektromiyografi.

Temporal bone fractures primarily result from head trauma secondary to traffic accidents and falls.^[1] Temporal bone trauma can result in facial paralysis, which occurs in 5–10% of patients, depending on the type of fracture. The other manifestations of temporal trauma are hearing loss (sensorineural, conductive or mixed) and cerebrospinal fluid leakage.

Temporal bone fractures are usually classified as longitudinal, transverse or mixed based on the course of the

fracture line according to the long axis of the petrous bone.^[1]

The timing and type of surgery employed for patients with traumatic facial paralysis from temporal bone trauma are very important and can be challenging at times.^[2] Electrodiagnostic tests and temporal bone imaging techniques provide important parameters that affect the decision regarding surgery and can be used to predict facial functional outcomes.^[2]

Correspondence: Elif Baysal, MD. Department of Otorhinolaryngology, Faculty of Medicine, İnönü University, 44280, Malatya, Turkey.
e-mail: baysalelif@yahoo.com

Received: April 15, 2016; **Accepted:** June 11, 2016

Online available at:
www.entupdates.org
doi:10.2399/jmu.2016002006
QR code:



Materials and Methods

This was a retrospective review of the data from 15 patients who underwent facial nerve decompression in the Gaziantep University Otolaryngology Department between January 2005 and January 2015. The local ethics committee approved the study. All patients presented with facial paralysis immediately after the trauma. All patients were evaluated with high-resolution temporal computed tomography (HRCT) and the House-Brackmann grading system (HBG), and electrodiagnostic tools [electromyography (EMG) or electroneurography (Enog), if possible] were used to evaluate the facial function.

Surgical technique

All patients underwent facial decompression surgery via a transmastoid approach. After a standard mastoidectomy, the facial nerve was decompressed from the second genu to the digastric ridge, a posterior tympanotomy was performed, the incudostapedial joint was separated and the incus was removed. Then, the decompression was continued from the second genu to the geniculate ganglion. After finding and repairing the injured side, the operation was complete. There was no need to perform a middle fossa approach in these patients because of the site of the injuries.

Results

Seven of the patients were male and 8 were female, and their ages ranged from 2–59 (average 20.56) years. All patients had unilateral fractures; 8 had transverse fractures, 3 had mixed fractures and 4 had longitudinal-type fractures. **Fig. 1** shows the transverse type of temporal bone fracture.

The following types of trauma occurred: 8 patients were in traffic accidents (3 were motorcycle accidents), 5 patients fell from a height and 2 patients were struck by a falling television. Seven patients had total sensorineural hearing loss (>120 dB), 4 patients had moderate mixed-type hearing loss (average air conduction between 38–50 dB) and 2 patients had mild conductive hearing loss (average air conduction between 28–35 dB). Two patients had normal hearing. In thirteen patients, the laceration was found in the tympanic segment; in 2 patients, the laceration was found in the 1st genu; and in 2 patients, the laceration was found in the 2nd genu of the facial nerve. The intraoperative findings correlated with the HRCT findings that were obtained before the operation. Ossicular chain reconstruction with incus transposition or bone cement was performed for the conductive hearing loss. A transmastoid approach was planned based on the site of the lesion of the facial nerve.

The intraoperative findings, was summarized in **Table 1**. The timing of the surgery ranged from 2 days to 3 months after the injury (average of 39.38 days), as shown in **Table 1**. The main findings were edema, granulation tissue and a partial or complete split of the facial nerve.

Three patients underwent Enog and 12 patients underwent EMG prior to the operation. Four patients had total axonal degeneration, and the remaining patients had no voluntary motor unit potential (MUP). The preoperative and postoperative House-Brackmann grading system is summarized in **Table 2**. Five patients had House-Brackmann grade 2 facial paralysis and 10 patients had House-Brackmann Grade 3 facial paralysis during the postoperative follow-up.

An electrophysiological evaluation was performed 6 months after the surgery. There were no major complications after the surgery.

Discussion

This study reviewed 15 patients with traumatic facial paralysis. Traffic accidents were the cause of the trauma in 8 patients (3 of them were motorcycle accidents), falls from a height were the cause of trauma in 5 patients and strikes from a falling television were the cause of trauma in 2 patients. The number of falls was relatively high because sleeping on the roof is a common habit in the southeastern region of Turkey. According to Ulrich^[3] and McHugh,^[4] temporal bone fractures can be classified as longitudinal, transverse and mixed according to the axis of the petrous pyramid. In our study, 8 fractures were transverse, 4 were

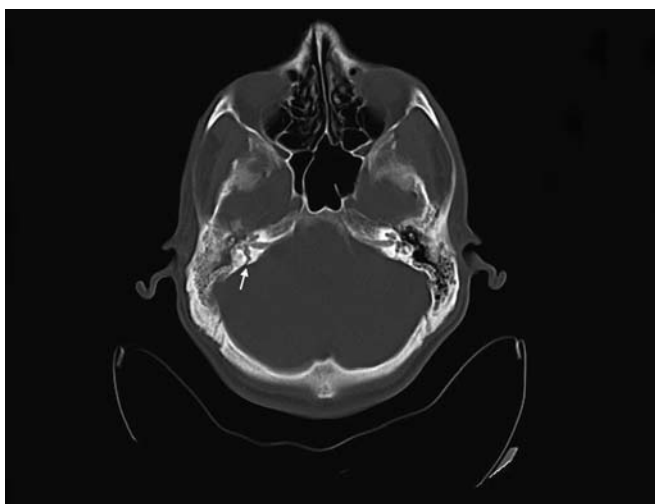


Fig. 1. Thirty-year-old male with transverse temporal bone fracture (Number 2 patient in the table). This temporal bone HRCT shows right side transverse temporal bone fracture includes labyrinth (arrow).

Table 1. Intraoperative findings of the patients underwent facial decompression.

	Site	Fracture	Approach	Hearing loss	Facial nerve findings (location & nerve condition)		
					Lesion location	Operative findings	FN integrity
1	RE	TF	TM	SNHL	TS	Fractured bony fragments and edema	Intact
2	RE	TF	TM	SNHL	TS	Granulation tissue	Intact
3	LE	MF	TM	SNHL	TS	Partial laceration and fibrosis and edema	Intact
4	RE	LF	TM	MIXED	TS-MS	Completely split, granulation and edema	Impaired
5	RE	MF	TM	SNHL	LS-TS	Bony fragments, partial laceration, edema and fibrosis	Intact
6	RE	LF	TM	CHL	TS	Completely split, fibrosis	Impaired
7	RE	LF	TM	Normal hearing	TS-MS	Completely split, edema	Impaired
8	LE	TF	TM	SNHL	TS	Completely split, granulation tissue	Impaired
9	RE	TF	TM	SNHL	TS	Partial laceration and fibrosis, granulation tissue	Intact
10	LE	TF	TM	SNHL	TS	Completely split and fractured bony fragments	Impaired
11	RE	TF	TM	SNHL	GG-TS	Granulation tissue and edema	Intact
12	LE	TF	TM	SNHL	TS	Granulation tissue and edema	Intact
13	LE	LF	TM	CHL	GG-TS	Fractured bony fragments and fibrosis	Intact
14	RE	TF	TM	SNHL	TS	Partial laceration and edema	Intact
15	LE	MF	TM	CHL	TS	Completely split, granulation tissue and edema	Impaired

CHL: conductive hearing loss; GG: geniculate ganglion; LE: left; LF: longitudinal-type fracture; LS: labyrinthine segment; MF: mixed fracture; MS: mastoid segment; RE: right, SNHL: sensorineural hearing loss; TF: transverse fracture; TM: transmastoid; TS: tympanic segment.

longitudinal and 3 were mixed-type fractures. In two of the patients with longitudinal fractures, there was disruption of the facial nerve.

Some controversies remain regarding the timing of and the approach used for surgery. The type of injury, the onset

of paralysis, the localization of the injury, comorbidities (cranial injuries) and the results of the electrophysiologic tests are the main determinates for both the timing of and the approach used for the surgery. Horizontal segment and geniculate ganglion injuries can be exposed by the transmas-

Table 2. Intraoperative findings of the patients underwent facial decompression.

Patient No	Timing	EMG/ENoG Pre-op	Loss (%)	EMG Post-op (6 months-1 years)	Pre- op HBG	Post- op HBG
1	7 days	Total axonal degeneration	...	mOOC; amp R; 1.1, L; 3.0 mV	5	2
2	2 months	mOOC; amp R; 0.1, L; 1.6 Mv/No voluntary MUP	93%	mOOC; amp R; 0.9, L; 2.9 mV/voluntary MUP+	6	3
3	2 days	Total axonal degeneration	...	mOOC; amp R; 2.3, L; 1.1 mV	5	2
4	2.5 months	mOOC; amp R; 0.3, L; 2.0 Mv/No voluntary MUP	85%	mOOC; amp R; 1.0, L; 2.3 mV	5	3
5	3 months	mOOC; amp R; 0.3, L; 2.7 Mv/No voluntary MUP	88%	mOOC; amp R; 1.2, L; 2.9 Mv/voluntary MUP+	5	2
6	1 month	mOOC; amp R; 0.3, L; 2.2 Mv/No voluntary MUP	86%	mOOC; amp R; 1.4, L; 2.9 Mv/voluntary MUP+	5	3
7	4 days	Total axonal degeneration	...	mOOC; amp R; 0.7, L; 2.8 Mv/voluntary MUP+	6	3
8	1 month	mOOC; amp R; 2.3, L; 0.2 Mv/No voluntary MUP	95%	mOOC; amp R; 2.1, L; 0.9 mV	6	3
9	1.5 month	mOOC; amp R; 0.3, L; 1.7 Mv	82%	mOOC; amp R; 0.9, L; 1.9 Mv	5	3
10	2 months	mOOC; amp R; 0.2, L; 3.0 Mv/No voluntary MUP	93%	mOOC; amp R; 1.4, L; 3.4 Mv/voluntary MUP+	6	3
11	1 month	mOOC; amp R; 0.3, L; 3.4 Mv/No voluntary MUP	91%	mOOC; amp R; 2.1, L; 3.7 Mv/voluntary MUP+	6	3
12	1.5 month	mOOC; amp R; 2.0, L; 0.1 Mv	95%	mOOC; amp R; 2.2, L; 1.2 Mv	5	2
13	1.5 month	mOOC; amp R; 1.6, L; 0.3 Mv/No voluntary MUP	81%	mOOC; amp R; 2.1, L; 0.9 Mv	5	2
14	2 months	mOOC; amp R; 0.2, L; 3.1 Mv/No voluntary MUP	93%	mOOC; amp R; 1.2, L; 3.3 Mv/voluntary MUP+	5	3
16	1.5 month	mOOC; amp R; 2.4, L; 0.3 Mv/No voluntary MUP	87%	mOOC; amp R; 2.7, L; 1.2 Mv/voluntary MUP+	6	3

amp: amplitude; L: left; mOOC: musculus orbicularis oculi; MUP: motor unit potential; Mv: microvolt; R: right

toid approach.^[5-7] The majority of the patients in our series had transverse fractures that were associated with the involvement of part of the facial nerve between the first genu and the digastric ridge. Edema, the formation of granulation tissue, and the presence of bone chips in the facial nerve were the major intraoperative findings. Transmastoid facial nerve decompression was performed in our series based on the preoperative HRCT and intraoperative findings. We preferred to perform a posterior tympanotomy to inspect the middle ear and decompress the mastoid segment of the facial nerve. Conductive hearing loss was restored by ossicular chain reconstruction. All of the patients had HBG-6 initially, and the rate of recovery was measured by EMG and HBG. Ten of the 15 patients recovered to HBG III, and 5 recovered to HBG II. According to the EMG results, there was an increase in the MUP and amplitudes of the orbicularis oculi muscle.

The small number of patients evaluated is the major limitation of this study; however, the authors propose that using the transmastoid approach in patients with facial nerve injuries within the first genu and digastric ridge is appropriate. The timing is another challenging issue; however, the patient who underwent surgical intervention after 3 months had HBG II and voluntary MUP 6 months after the surgery.

Conclusion

The authors propose that the transmastoid approach in patients with facial nerve injuries within the first genu and

the digastric ridge is appropriate, and the increase in the amplitude observed in the postoperative EMG records obtained from musculus orbicularis oculi may be considered as significant indicator of nerve recovery that occurs before clinical improvement.

Conflict of Interest: No conflicts declared.

References

1. Serin GM, Derinsu U, Sari M, et al. Cochlear implantation in patients with bilateral cochlear trauma. *Am J Otolaryngol* 2010; 31:350–5.
2. Ulug T, Arif Ulubil S. Management of facial paralysis in temporal bone fractures: a prospective study analyzing 11 operated fractures. *Am J Otolaryngol* 2005;26:230–8.
3. Ulrich K. Verletzungen des Gehörorgans bei Schädelbasisfrakturen (Eine histologische und klinische Studie). *Acta Otolaryngol Suppl* 1926;6:1–150.
4. McHugh HE. The surgical treatment of facial paralysis and traumatic conductive deafness in fractures of the temporal bone. *Ann Otol Rhinol Laryngol* 1959;68:855–9.
5. May M. Total facial nerve exploration: transmastoid, extralabyrinthine, and subtemporal indications and results. *Laryngoscope* 1979;89:906–17.
6. Pellicer M, Quesada P. The use of a CT scan to predict the feasibility of decompression of the first segment of the facial nerve via the transsattical approach. *J Laryngol Otol* 1995;109:935–40.
7. Yetiser, S, Satar B, Kazkayasi M. Immunologic abnormalities and surgical experiences in recurrent facial nerve paralysis. *Otol Neurotol* 2002;23:772–8.

This is an open access article distributed under the terms of the Creative Commons Attribution-NonCommercial-NoDerivs 3.0 Unported (CC BY-NC-ND3.0) Licence (<http://creativecommons.org/licenses/by-nc-nd/3.0/>) which permits unrestricted noncommercial use, distribution, and reproduction in any medium, provided the original work is properly cited.

Please cite this article as: Baysal E, Gülşen S, Aytaç İ, Çıkrıkçı S, Gönültaş B, Durucu C, Mumbuç S, Kanlıkama M. Surgical intervention for traumatic facial paralysis: an analysis of 15 patients. *ENT Updates* 2016;6(2):74–77.