

Transgastric removal of a polycystic liver disease using mini-laparoscopic excision

FATIH SUMER, CUNEYT KAYAALP*, YILMAZ POLAT, ISMAIL ERTUGRUL,
SERVET KARAGUL

Department of Surgery, Inonu University, Malatya, Turkey

*Corresponding author: Prof. Cuneyt Kayaalp, MD; Department of Surgery, Inonu University, Malatya 44315, Turkey;
Phone: +90 422 341 06 60; Fax: +90 422 341 02 29; E-mail: cuneytkayaalp@hotmail.com

(Received: January 17, 2016; Revised manuscript received: May 7, 2016; Accepted: May 9, 2016)

Abstract: Surgical treatment is often necessary for patients with symptomatic or complicated polycystic liver diseases (PLD). In this paper, we describe a 52-year-old female with symptomatic PLD that had resulted in the formation of liver cysts, the largest of which was 23 cm in diameter. The patient underwent mini-laparoscopic fenestration through 5-mm abdominal trocars. The walls of the cysts were unroofed using a harmonic scalpel. Four thickened rubber-like pieces of specimens (sizes ranged between $9 \times 6 \times 0.5$ cm and $6 \times 3 \times 0.1$ cm) were not suitable for extraction through the 5-mm trocars. A gastrotomy was performed, and the specimens were extracted through the stomach with the help of an endoscope. Transoral removal of the specimens was completed without any complications, and the gastrotomy was closed intracorporeally. The patient was permitted to take fluids on day one, and oral intake was gradually increased. She was discharged on day four and was asymptomatic after two months of follow-up. The combination of mini-laparoscopy and intraoperative endoscopic specimen extraction represented a minimally invasive surgical approach for the treatment of PLD. To the best of our knowledge, this was the first case report of the transoral extraction of a liver specimen.

Keywords: liver cyst, endoscopy, laparoscopy, natural orifice surgery, natural orifice specimen extraction, transgastric removal

Introduction

Polycystic liver disease (PLD) is an autosomal dominant disease that is observed more commonly in adult women. Surgical treatment is required only in symptomatic patients and for cysts that result in complications. Fenestration and/or hepatic resection are the most common surgical procedures that are used to treat PLD, and both can be performed by open or laparoscopic techniques. Liver transplantation is often the most suitable option for patients who experience liver failure and clinical deterioration as a result of the development of large cysts. A recent study demonstrated that prior open surgeries when compared to prior minimally invasive surgeries for PLD were associated with an increased risk of morbidity and mortality in liver transplantation [1].

Like other forms of gastrointestinal surgery, laparoscopic surgery is increasingly being acknowledged as a preferable and superior approach to open surgery for the treatment of liver diseases [2]. Laparoscopic surgery is particularly beneficial because of the decreased

dimensions of the laparoscopic trocars that are used in combination with mini-laparoscopic techniques and the fact that it is possible to remove specimens via natural orifices and, therefore, avoid additional abdominal incisions [3]. The objective of the surgery performed in this case report was to utilize a minimally invasive approach to liver surgery via a combination of mini-laparoscopy and natural orifice specimen extraction.

Case Report

A 52-year-old female patient was admitted with abdominal pain and swelling. She was known to have been suffering from polycystic liver and kidney diseases for five years. No interventional therapeutic procedure had previously been performed, and no medical treatment modality had been attempted. The patient was recommended for surgery because she was experiencing increased abdominal distension, pain, nausea, and vomiting. She had no comorbidities, and her ASA (American Society of Anesthesiologists) performance score was I.

This is an open-access article distributed under the terms of the Creative Commons Attribution License, which permits unrestricted use, distribution, and reproduction in any medium for non-commercial purposes, provided the original author and source are credited.

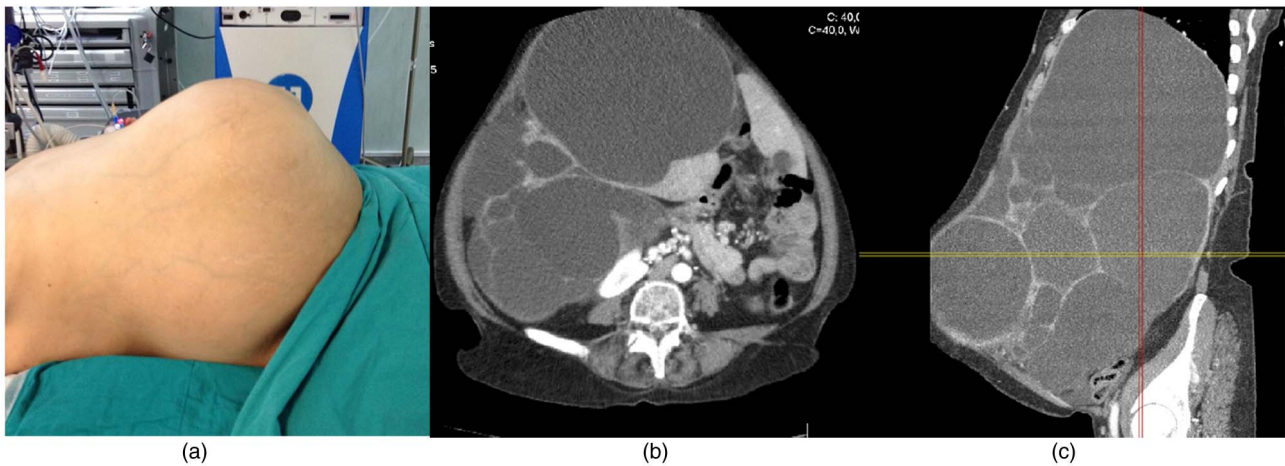


Fig. 1. Preoperative patient and computed tomography images

Physical examination revealed a severe abdominal distention and a hard mass that filled the entire abdomen except the pelvis (*Fig. 1a*). The computed tomography revealed that there were multiple cysts filling the liver, with the largest of these being up to 23 cm in diameter (*Figs 1b* and *1c*). Tests revealed that the patient's liver and kidney function and hematological tests were within normal limits with the exception of indications of mild anemia and hypoalbuminemia: hemoglobin 12.3 g/dL (normal ranges 13.6–17.2 g/dL), white blood count 7,100/mm³, platelets 220,000/mm³, INR 1.1, prothrombin time 12.9 s, activated partial thromboplastin time 37.2 s, urea 15 mg/dL, creatinine 0.67 mg/dL, albumin 2.4 g/dL (normal range 3.5–5.0 g/dL), total bilirubin 0.48 mg/dL, direct bilirubin 0.25 mg/dL, aspartate aminotransferase 29 U/L, alanine aminotransferase 24 U/L, alkaline phosphatase 139 U/L, and gamma-glutamyl transpeptidase 62 U/L. Laparoscopic liver cyst fenestration was planned for the patient, and she was provided with detailed information about the novel surgical procedure before informed consent was taken.

The patient was operated on in the supine position. It was determined that the use of pneumoperitoneum was not safe due to the distention of some of the cysts. As such, the two largest cysts in the right liver lobe were first percutaneously aspirated by Veres needle under the guidance of computed tomography images. After the cysts had been reduced in size, the pneumoperitoneum was then created from the hypogastrium with the Veres needle and a 5-mm trocar was inserted through the hypogastrium for the camera. The peak intra-abdominal pressure was 12 mmHg. There were multiple, bilobar, thin-, and thick-walled liver cysts. Two 5-mm trocars were inserted through the right and left lower abdominal quadrants. The thickened walls of the major cysts were unroofed as much as possible using a harmonic scalpel and their contents were aspirated. The large anterior cyst was full of hematoma, and this was believed to be the

cause of the patient's recent abdominal pain. Four thick-walled cysts (two were dominant) were fenestrated, and the specimens were collected in one of the fenestrated cysts.

A 2-cm long gastrotomy was performed to the stomach corpus using a harmonic scalpel. Intraoperative gastroscopy was performed. One by one, the specimens were grasped by an endoscopic snare and extracted through the mouth (*Figs 2a* and *2b*). Four pieces of cyst walls with diameters ranging from 9 × 6 × 0.5 cm to 6 × 3 × 0.1 cm were removed through the stomach by intraoperative endoscopy (*Fig. 2c*). The gastrotomy was closed in two continuous rows using 3/0 polypropylene intracorporeal sutures. The falciform ligament was fixed into the nearest fenestrated cyst, and a drain was placed to the same cyst through the left trocar site. A total of 5,000 mL of cyst content was aspirated, intraoperative blood loss was 300 mL (mainly from the cyst walls and hematoma), and the duration of surgery was 270 min. At the end of the surgery, the patient's abdominal distention had decreased significantly (*Fig. 3a*). On day one, the patient was permitted to take fluids and oral intake was increased gradually. The amount of serosanguineous drainage was 800 mL on day one, and this decreased on day two. The drain was removed on day three. The postoperative course of recovery was smooth, and the patient suffered only mild degrees of pain. A computed tomography that was performed on day four revealed that the major cysts had shrunk (*Figs 3b* and *3c*). The patient was discharged on day four and was asymptomatic at the two-month follow-up. The histological examination of the specimens revealed that they were benign.

Discussion

Recent innovations in minimally invasive surgery have reached another level with surgeons now having the ability

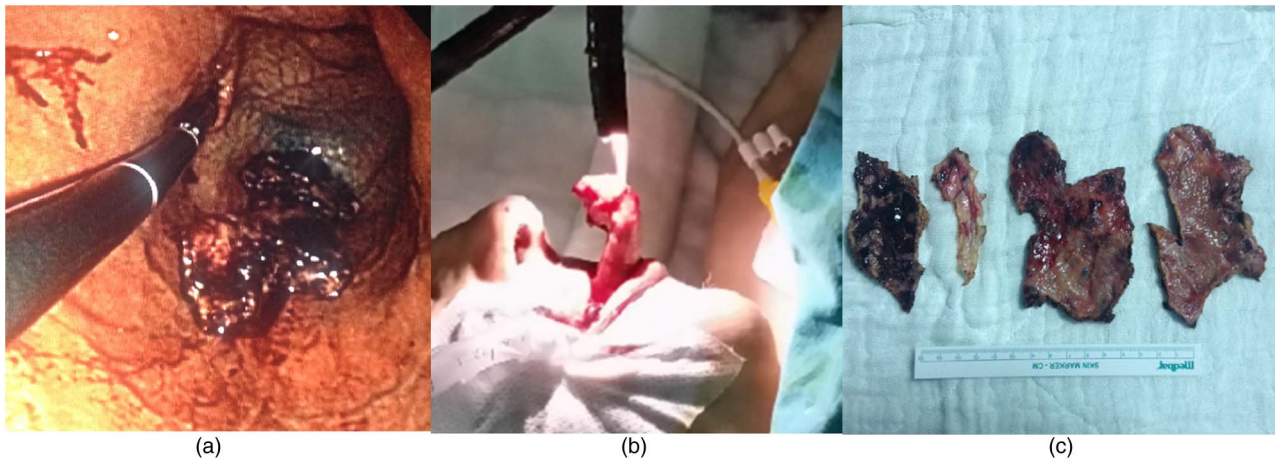


Fig. 2. Intraoperative findings of transgastric extraction (a), transoral removal (b), and the removed specimens (c)

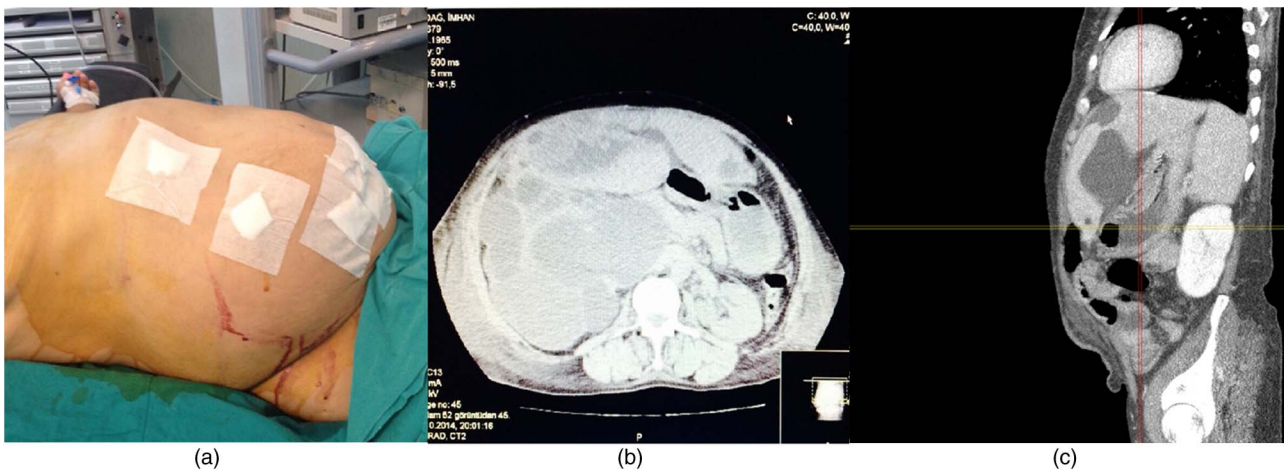


Fig. 3. View of the abdomen in the early postoperative period and computed tomography images before hospital discharge

to perform surgery via smaller entrances to the body and natural orifices. The objective of these novel approaches is to minimize the abdominal wall incision while also allowing the surgeon to reach the intra-abdominal pathology. This allows surgeons to minimize the surgical trauma, which results in more rapid patient recovery, less pain, better cosmesis, and fewer wound-related early and late complications such as infections or hernias.

There are four potential natural orifices: transgastric, transanal, transvaginal, and transurethral. The use of the transvaginal and transgastric paths does not seem to cause significant risks from the viewpoint of infections [4]. The feasibility of transgastric surgery has been demonstrated in the experimental models; however, closing the gastrotomy using only an endoscopic approach remains a challenge [4, 5]. The use of a mini-laparoscopic approach in combination with endoscopy has been found to result in safer intra-abdominal excision, easier extraction, and safer closing of the gastrotomy [6]. Jurczak and Pouset [6] reported mini-laparoscopic cholecystectomy and transgastric extraction in 63 patients without any

complications related to the gastrotomy. Previous clinical and experimental studies in the literature and our previous experiences have revealed that transgastric approach allows a port that can be easily reached with rapid healing [6, 7]. When the resected organ and the extraction organ, the liver and the stomach, respectively, are located in the same area (here the upper abdomen), the surgeon benefits from the added advantage of being able to perform surgical manipulations. Here, there was no need to change the position of the patient or the camera. The stomach is a well-vascularized organ that can be opened and closed safely during laparoscopic surgery [6]. Unlike the transvaginal approach, the transgastric approach also allows specimens to be extracted in both genders.

At the beginning of the natural orifice surgery program in our center, we had already tested several natural orifice surgery techniques [8–14]. Our previous experiences demonstrated that some specimens in similar size of this could be extracted safely through the mouth. We had previously extracted gallbladders, an appendix, and adrenal gland specimens through the stomach. Recently, we demonstrated

that a gallbladder with stones could be extracted through the jejunum via a Roux-en-Y gastric bypass [7]. Here, we used only 5-mm ports during surgery. As shown in *Fig. 2c*, the size of the specimens entailed that they could not be extracted through 5- or even 12-mm trocar port sites. In fact, it was not possible to extract the resected liver cyst walls from the port sites unless they were enlarged to 20–25 mm. Moreover, the cyst walls were as stiff as rubber and were as thick as 5 mm in some pieces. It was for this reason that the transgastric approach was preferred as opposed to extending the trocar sites for specimen extraction. All the procedures were completed with only three trocars, each of which was 5 mm in diameter.

To conclude, a combination of advanced laparoendoscopic procedures (mini-laparoscopy and natural orifice specimen) and intraoperative endoscopy provided a more minimally invasive surgery by which the cysts could be removed from the patient's liver. To the best of our knowledge, this was the first case report of transoral extraction of a specimen from a subject's liver.

* * *

Funding sources: None.

Authors' contribution: FS, CK: designed the study. FS, YP, IE: performed the procedure. CK, SK, FS: wrote the manuscript.

Conflict of interest: Authors declare that none of them have a conflict of interest.

Ethics: An informed consent was obtained from the patient for publication of this case report and accompanying images.

References

1. Baber JT, Hiatt JR, Busuttill RW, Agopian VG: A 20-year experience with liver transplantation for polycystic liver disease: Does

- previous palliative surgical intervention affect outcomes? *J Am Coll Surg* 219, 695–703 (2014)
2. Schiffman SC, Kim KH, Tsung A, Marsh JW, Geller DA: Laparoscopic versus open liver resection for metastatic colorectal cancer: A metaanalysis of 610 patients. *Surgery* 157, 211–222 (2015)
3. Kayaalp C: Minilaparoscopy combined with natural orifice surgery: Benefits can be beyond the cosmesis. *J Nippon Med Sch* 81, 406 (2014)
4. Lukovich P, Zsirka-Klein A, Vanca T, Szpaskij L, Benko P: Getting ready for surgery through natural orifice. *Interv Med Appl Sci* 2, 121–125 (2010)
5. Fuchs KH, Breithaupt W, Schulz T, Ferencz S, Varga G, Weber G: Transgastric small bowel resection and anastomosis: A survival study. *Surg Endosc* 25, 1791–1796 (2011)
6. Jurczak F, Pousset JP: Laparoscopic cholecystectomy combined using miniaturised instruments in transgastric gall bladder removal: Performed on 63 patients. *Minim Invasive Surg* 2010, 582763 (2010)
7. Kayaalp C, Tardu A, Yagci MA, Sumer F: Transjejunal extraction of gallbladder after mini-laparoscopic cholecystectomy in patients with previous Roux-en-Y gastric bypass: A small case series. *J Laparoendosc Adv Surg Tech A* 25, 577–580 (2015)
8. Yagci MA, Kayaalp C, Ates M: Transvaginal appendectomy in morbidly obese patient. *Case Rep Surg* 2014, 368640 (2014)
9. Yagci MA, Kayaalp C, Kutluturk K: Laparoscopic right colectomy with transvaginal extraction in a patient with prior pancreaticoduodenectomy. *G Chir* 35, 209–212 (2014)
10. Kayaalp C, Yagci MA, Soyer V: Hybrid transvaginal incisional hernia repair. *J Laparoendosc Adv Surg Tech A* 24, 497–501 (2014)
11. Yagci MA, Kayaalp C, Novruzov NH: Intracorporeal mesenteric division of the colon can make the specimen more suitable for natural orifice extraction. *J Laparoendosc Adv Surg Tech A* 24, 484–486 (2014)
12. Alam AH, Soyer V, Sabuncuoglu MZ, Otan E, Kayaalp C: Natural orifice specimen extraction (NOSE) and transanal extracorporeal anvil placement during laparoscopic low anterior resection. *Tech Coloproctol* 18, 669–671 (2014)
13. Kayaalp C, Yagci MA: Laparoscopic right colon resection with transvaginal extraction: A systematic review of 90 cases. *Surg Laparosc Endosc Percutan Tech* 25, 384–391 (2015)
14. Yagci MA, Kayaalp C: Transvaginal appendectomy: A systematic review. *Minim Invasive Surg* 2014, 384706 (2014)