

## Brief Report

# Pseudoachondroplasia in a child with prolapse of the mitral valve

Cemşit Karakurt, Selmin Karademir, Çiğdem Üner

*Dr. Sami Ulus Childrens' Hospital, Ankara, Turkey*

**Abstract** Pseudoachondroplasia is an autosomal dominant variant of osteochondroplasia that results in mild to severe short-limb dwarfism and early-onset of osteoarthritis. It has been linked to results from mutations in the gene for cartilage oligomeric matrix protein. We describe a 4-year-old boy with pseudoachondroplasia who also had prolapse of the mitral valve. To the best of our knowledge, this association has not previously been reported.

Keywords: Short-limb dwarfism; systemic abnormalities; prolapse of the leaflet

**P**SEUDOACHONDROPLASIA IS A SPONDYLO-EPI-metaphyseal dysplasia characterised by disproportionate short stature, generalised ligamentous laxity, and precocious osteoarthritis. It was first delineated clearly by Maroteaux and Lamy under the title “pseudoachondroplastic spondyloepiphyseal dysplasia”. According to current terminology, the condition would be called the pseudoachondroplastic variant of spondylo-epi-metaphyseal dysplasia.<sup>1</sup>

Pseudoachondroplasia shows a wide range in the severity of bony abnormalities in different affected individuals. No other systemic abnormalities are known.<sup>2</sup> We describe here a 4-year-old child who has developed both pseudoachondroplasia and prolapse of the leaflets of the mitral valve. To the best of our knowledge, this combination has not previously been described.

## Case report

A 4-year-old boy was admitted to our hospital because of short stature and a waddling gait. There was no parental consanguinity. The boy is the second child of the family, and his 10-year-old brother was of normal stature and was neurodevelopmentally normal. The father has six brothers, however, four

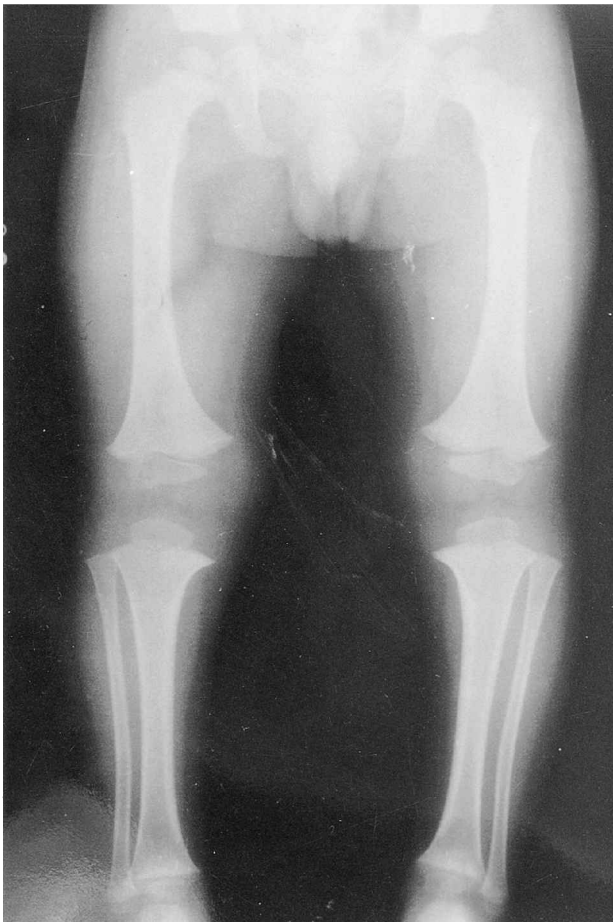having short stature, and the other two being of average height. Our patient had exhibited normal neurodevelopment in infancy except for some gross development skills. He sat alone at 12 months, and walked at 3 years old. When first seen, the child weighed 12.8 kg, being between the 3rd and 10th centiles, was 84.5 cm high, which is below the 3rd centile. He had a cranial circumference of 51 cm, at the 50th centile, and the ratio between his arms and legs was 1.6. He was disproportionally short, had a lumbar lordosis, and exhibited a bowlegged deformity.

By cardiac examination, we determined that the heart rate was 126 beats per minute, and regular. A 2/6 degree late systolic murmur was heard at the apex, along with a mid systolic click. Radiographic examination demonstrated the bowlegged deformity, and showed widening of the femoral, humeral, and tibial metaphyses (Fig. 1). Cranial and vertebral radiographic findings were normal except for the lumbar lordosis. Electrocardiographic findings were normal.

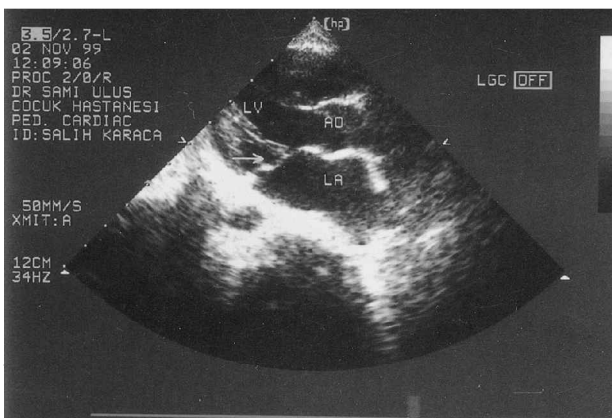
Echocardiography revealed prolapse of the aortic leaflet of the mitral valve towards the left atrium during systole. Colour Doppler interrogation revealed moderate mitral regurgitation, with midsystolic peaking, and maximum velocity across the valve approaching 50 mm/s (Fig. 2).

The father was 30 years old, 145 cm high, this being below the 3rd centile, weighed 58.7 kg, and had a cranial circumference of 58 cm. Radiographic examination of the father showed short metacarpal

Correspondence to: Cemşit Karakurt, Dr. Sami Ulus Childrens' Hospital Babür Cad. Örnek Mah. Ankara, Turkey. Tel: +90 312 317 07 07; Fax: +90 312 311 47 77; Email: ckarakurt@yahoo.com



**Figure 1.**  
The radiographic images of the legs show the bowlegged deformity, together with widening of the femoral, and tibial metaphyses.



**Figure 2.**  
The cross-sectional echocardiogram, in parasternal long axis, show prolapse of the aortic leaflet of the mitral valve.

bones, short and broad tubular bones, a decrease of the angle of the femoral neck, a long tibial medial condyl, "V" shaped distal ulnar metaphyses, and broad ribs. Cranial radiography was normal, but vertebral radiography revealed lumbar lordosis.

The clinical appearances for both our patient and his father indicated a mild form of pseudoachondroplasia with a wide-based gait, bowlegged deformity, but normal facial features and cranial circumference.

## Discussion

Pseudoachondroplasia is a short limb dwarfing condition whose clinical and radiographic manifestations have been described in many articles. Individuals with pseudoachondroplasia have normal faces and heads, shortening of the limbs, irregular epiphyses, scoliosis, lordosis, bowlegged deformity, and marked shortening of the bones in the hands and feet.<sup>3</sup> Premature osteoarthritis often occurs in the third decade, and may be disabling by middle age. Milder cases of pseudoachondroplasia exhibit similar features, but short stature is less pronounced, and there is less deformity than in more severe cases.<sup>1,2,4</sup> The clinical appearance and radiographic findings in our patient and his father show they have the mild form of pseudoachondroplasia.

Idiopathic prolapse of the leaflets of the mitral valve is a common disorder, but many cases are clinically subtle. The prevalence of clinically important prolapse is estimated at between 3 and 8%.<sup>5</sup> In most instances, the prolapse is primary, and is due to an inherited abnormality of the leaflets and their supporting tendinous cords. Rupture or dysfunction of papillary muscles due to myocardial ischemia or endocarditis, or abnormal motion of the left ventricular wall due to myocardial abnormality, can cause secondary prolapse.

Prolapse may be associated with several other cardiovascular and noncardiovascular abnormalities. It occurs as a pleiotropic manifestation of several of the most common heritable disorders of connective tissue, such as Marfan's syndrome or Ehler-Danlos syndrome. Skeletal abnormalities of the chest and spine including, midline narrowing of the thoracic cavity, pigeon breast, straight back, scoliosis and narrow anteroposterior diameter, have been reported in two-third of patients with prolapsing mitral valves.<sup>5,6,7</sup> The precise relationship between prolapse, heritable disorders of connective tissue, and the skeletal abnormalities is not clear. It has been suggested that patients with myxomatous changes in the mitral valve, some of whom have midline narrowing of the thoracic cavity or scoliosis, are manifesting a variant of Marfan's syndrome. It is argued that they have a basic disorder of the connective tissues that leads to myxomatous changes in the leaflets of the mitral valve, along with skeletal abnormalities. A second possibility for this coincidence may reflect development. Differentiation of the mitral valve, and chondrification and ossification of the vertebral column and thoracic cage, begin at the same

time, namely between 35th and 42nd day of fetal development.<sup>5</sup> Any influence at this stage of development might affect both the mitral valve and the thorax. Mechanical pressure on the heart is known to cause distortion of the mitral valve in patients with an extremely shallow chest.<sup>7,8</sup>

Ultrastructural analysis of chondrocytes from patients with pseudoachondroplasia shows distinctive and enormous vesicles of the rough endoplasmic reticulum. A possible mechanism for impaired function of cartilage could be related to the intracellular accumulation of mutant molecules reflected by these enlarged vesicles. This could lead to a deficiency of extracellular matrix components, or possibly adversely affect chondrocyte metabolism or proliferation.<sup>9,10</sup> Intracellular storage of oligomeric matrix protein in chondrocytes results in a deficiency of the structural components of cartilage leading to impaired growth and maintenance.<sup>4</sup>

To the best of our knowledge, association of prolapse of the mitral valve and pseudoachondroplasia has not previously been defined. The short stature, and lumbar lordosis, of our patient in itself could cause mitral valvar prolapse. We consider, nonetheless, that pseudoachondroplasia is the more probable cause because of the defects of structural components and growth of cartilage in pseudoachondroplasia.

## References

1. Maroteaux P, Stanescu R, Stanescu V, Fontaine G. The mild form of pseudoachondroplasia. *Eur J Pediatr* 1980; 133: 227–231.
2. Gellis SS, Feingold M. Picture of the month. Pseudoachondroplasia. *Am J Dis Child* 1974; 128: 833–834.
3. Dähnert W. *Radiology Review Manual*, 4th edition. Williams & Wilkins, Maryland, USA, 1999, pp 119.
4. Maddox BK, Keene DR, Sakai LY, Charbonneau NL, Morris NP, Ridgway CC, Boswell BA, Sussman WA, Bachinger H, Hecht JT. The fate of cartilage oligomeric matrix protein is determined by the cell type in the case of a novel mutation in pseudoachondroplasia. *J Biol Chem Online* 1997; 272(49): 30993–30997.
5. Boudoulas H, Wooley C. Mitral Valve Prolapse. Moss AJ. In: Adams FH, Emmanouilides GC, Riemenschneider TA (eds). *Heart disease in infants, children and adolescents*, 4th edition. Williams & Wilkins, Baltimore, Md., USA 1989, pp 1063–1086.
6. Salomon J, Shah PM, Heinle RA. Thoracic Skeletal Abnormalities in Idiopathic Mitral Valve Prolapse. *Am J Cardiol* 1975; 36: 32–36.
7. Glesby MJ, Pyeritz RE. Association of mitral valve prolapse and systemic abnormalities of connective tissue: phenotypic continuum. *JAMA* 1989; 262: 523–528.
8. Carl P, Bon Tempo, James A, Ronan, Antonio C, De Leon, Homer L, Twigg. Radiographic appearance of the thorax in systolic click-late systolic murmur syndrome. *Am J Cardiol* 1975; 36: 27–31.
9. Briggs MD, Mortier GR, Cole WG, King LM, Golik SS, Bonaventure J, Nuytinck L, Paepe AD, Leroy JG, Biesecker L, Lipson M, Wilcox WR, Lachman RS, Rimoin DL, Knowlton RG, Cohn DH. Diverse mutations in the gene for cartilage oligomeric matrix protein in the pseudoachondroplasia – multiple ephyseal dysplasia disease spectrum. *Am J Hum Genet* 1998; 62: 311–319.
10. Hedbom E, Antonsson P, Hjerpe A, Aeschlimann D, Paulsson M, Rosa-Pimental E, Sommarin Y. Cartilage matrix protein (COMP) detected only in cartilage. *J Biol Chem* 1992; 267: 6132–6136.