

## Case Report

# Traumatic central cord syndrome in a 2-year-old child: minor trauma but major complication

Neslihan Yücel<sup>1</sup>, Cem Ertan<sup>2</sup>, Mustafa S. Pepele<sup>1</sup>, Ahmet Sığirci<sup>3</sup>

<sup>1</sup> Inonu University Faculty of Medicine, Department of Emergency Medicine, Malatya, Turkey

<sup>2</sup> Izmir University Faculty of Medicine, Department of Emergency Medicine, Izmir, Turkey

<sup>3</sup> Inonu University Faculty of Medicine, Department of Radiology, Malatya, Turkey

Corresponding Author: Cem Ertan, Email: cem\_ertan@hotmail.com

**BACKGROUND:** Traumatic central cord syndrome (TCCS) is the most frequently encountered incomplete spinal cord injury, and it is a relatively rare situation in children younger than 15 years, but may have serious consequences.

**METHODS:** We report the case of a 2-year-old female child with upper extremity weakness following a simple fall. All vitals and systemic examination findings were normal, except for 2/5 muscular strength in the upper extremities. While radiographic imaging showed no pathologic findings, MRI exposed spinal injury. The patient was treated conservatively with medication only. The medical treatment of the patient consisted of anti-edema treatment with methylprednisolone in the first 24 hours; 330 mg of methylprednisolone infused in the first hour, followed by 59 mg per hour during the next 23 hours. Along with pharmacological treatment, she received physiotherapy sessions during her 11-day hospitalization period.

**RESULTS:** The child had full recovery within 6 months after conservative treatment.

**CONCLUSION:** Neurological deficit without plain radiographic evidence in pediatric spinal trauma patients is a rare but significant incident.

**KEY WORDS:** Trauma; Emergency department; Spinal cord injury

World J Emerg Med 2014;5(2):151-153

DOI: 10.5847/wjem.j.issn.1920-8642.2014.02.014

## INTRODUCTION

Traumatic central cord syndrome (TCCS) is the most frequently encountered incomplete spinal cord injury and is predominantly a white matter injury of the spinal cord which causes a rather disproportionate motor weakness in the upper extremities other than lower parts and a variable amount of sensory loss below the level of injury.<sup>[1,2]</sup> The precise anatomic location of neuronal injury and the etiology of clinical manifestations are poorly understood.<sup>[3]</sup> The condition is mostly noted as an injury of young adults and the elderly.<sup>[2]</sup> Spinal cord injury (SCI) in children younger than 15 years of age is a relatively rare situation, but may have serious consequences.<sup>[3]</sup> Here we present a pediatric case of TCCS without radiographic abnormality

after a simple fall without any other obvious systemic injuries.

## CASE REPORT

A 2-year-old female child with no previously diagnosed chronic diseases was admitted to our emergency department (ED) because of weakness of the upper extremities. Her parents stated that, she fell down on the ground while she was running and her mother saw her right after the incident. They denied any obviously witnessed head trauma. They also stated that the weakness was recognized 3 to 4 hours after the trauma.

The patient was referred to our department for

further evaluation by another hospital at which no relevant pathology was diagnosed. The patient was alert at presentation to ED and her Glasgow coma scale score (GCS) was 15. Her blood pressure was 90/50 mmHg, heart rate was 125 beats/min, respiratory rate was 22 breath/min and SPO<sub>2</sub> value was 98. On neurological examination, upper extremity strength was determined to be 2/5 for both extremities, according to the Medical Research Council Scale. Examinations of other systems were normal.

Laboratory values and radiological evaluation were within normal ranges, including anteroposterior (AP) and lateral cervical X-rays and CT of the brain. A cervical magnetic resonance imaging (MRI) sequence was deemed necessary for further evaluation. The cervical MRI showed an expansible appearance in the spinal cord, along with signal alterations which were iso-to-mildly hyper-intense in T1 weighed images and, hyper-intense in T2 weighed and short-tau inversion-recovery (STIR)

images suggesting hyper-acute and acute hemorrhage foci between the inferior portion of the medulla oblongata and T2 vertebra level (Figures 1 and 2).

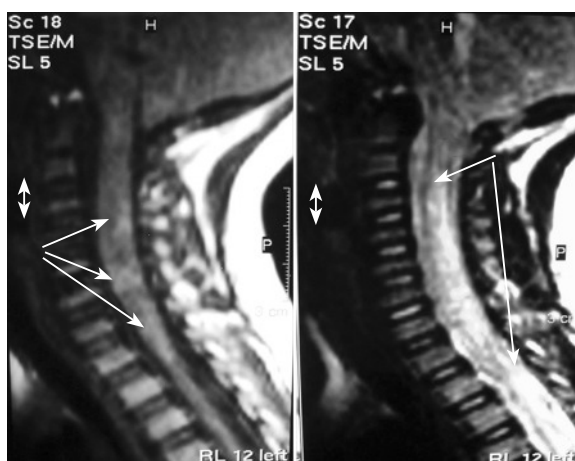
The patient was evaluated neurosurgically in the ED and she was hospitalized for further evaluation and treatment. The patient was treated conservatively with medication only. The medical treatment of the patient consisted of anti-edema treatment with methylprednisolone in the first 24 hours: 330 mg of methylprednisolone infused in the first hour, followed by 59 mg per hour during the next 23 hours. Along with pharmacological treatment, the patient received physiotherapy sessions during her 11-day hospitalization period. Although there was 1/5 motor deficit at discharge from hospital, no deficit was detected on examination at the 6<sup>th</sup> month.

## DISCUSSION

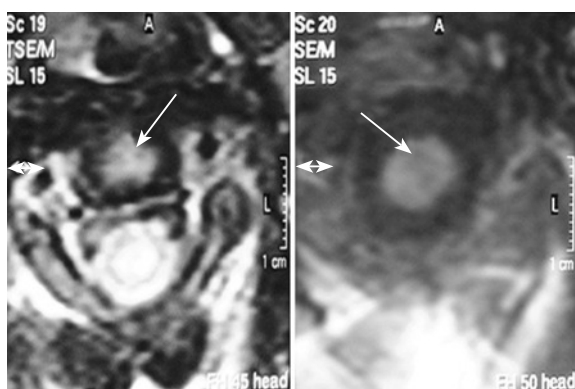
Traumatic central cord syndrome, regardless of its biomechanics, is the most frequently encountered incomplete spinal cord injury.<sup>[1,2]</sup> Patients with TCCS may present with disproportionate weakness of the upper extremities, variable sensory loss and bladder dysfunction.<sup>[3]</sup> Fractures and/or subluxations, forced hyperextension, and herniated nucleus pulposus are the main pathogenic mechanisms. Our patient had pronounced weakness of the upper extremity at presentation. The pathological mechanism of the injury was probably hyperextension due to a fall.

Pediatric TCCS is a relatively rare injury. Two large retrospective studies of the pediatric trauma databases by Patel et al<sup>[4]</sup> and Apple et al<sup>[5]</sup> found the incidences of TCCS were 1.5% and 5% respectively. Hofbauer et al<sup>[6]</sup> reported in their cohort review of polytraumatized children with spinal injury within an 18-year period that, only 3.1% of the severely injured children had a spinal injury and only three children younger than 4 years had cervical spinal injuries (0.3%). Our patient, who was only two years old, had no systemic injuries other than suspected minor head and neck trauma. An insignificant mechanism of trauma, such as simply falling on the ground, as an etiology of central cord syndrome is not commonly encountered.

Significant radiographic pathologic views may or may not accompany the injury in plain radiographs. The absence of radiographic evidence is more frequent in children younger than 8 years and in those with high injury severity scores (ISS).<sup>[7,8]</sup> Martin et al<sup>[7]</sup> reported in



**Figure 1.** T1 and T2 weighed images of the vertical sections of the spinal cord. Arrows showing the lesions in the cord.



**Figure 2.** T1 and T2 weighed images of the transverse sections of the spinal cord. Arrows showing the lesions in the cord.

2004 that 0.15% of pediatric trauma patients or 4.5% of spine injured children showed no evidence of fractures or dislocations in radiographic studies. Plain radiographs were evaluated in normal range in our patients, but the presence of myelopathy findings guided our decision for MRI, revealing the spinal injuries.

More than one-half of these patients experienced spontaneous recovery of motor weakness; however, as time went on, lack of manual dexterity, neuropathic pain, spasticity, bladder dysfunction, and imbalance of gait rendered their activities of daily living nearly impossible.<sup>[8]</sup> Our patient, being one of the lucky half, experienced no long-term complications at all after conservative treatment.

In conclusion, neurological deficit without plain radiographic evidence in pediatric spinal trauma patients is a rare but significant incident. Thorough neurologic evaluation and suspicion of central cord injury, even in the face of obviously minor trauma, are essential for timely diagnosis and treatment.

## ACKNOWLEDGEMENTS

This study is presented as a poster in 7th European Congress on Emergency Medicine in Antalya, Turkey, October 2011. There are no conflicts of interest that authors are aware of.

**Funding:** None.

**Ethical approval:** Not needed.

**Conflicts of interest:** The authors declare that there is no conflict of interest.

**Contributors:** Yücel N and Ertan C designed the report, Yücel N and Pepele MS analyzed the data, Ertan C wrote the paper, Sığırıcı A reviewed the radiological data. All authors read and approved the final version.

## REFERENCES

- 1 Yamazaki T, Yanaka K, Fujita K, Kamezaki T, Uemura K, Nose T. Traumatic central cord syndrome: analysis of factors affecting the outcome. *Surg Neurol* 2005; 63: 95–99; 99–100.
- 2 Li XF, Dai LY. Acute central cord syndrome: injury mechanisms and stress features. *Spine* 2010; 1; 35: E955–64.
- 3 Parent S, Mac-Thiong JM, Roy-Beaudry M, Sosa JF, Labelle H. Spinal cord injury in the pediatric population: a systematic review of the literature. *J Neurotrauma* 2011; 28: 1515–1524.
- 4 Patel JC, Tepas JJ, Mollitt DL, Pieper P. Pediatric cervical spine injuries: defining the disease. *J Pediatr Surg* 2001; 36: 373–376.
- 5 Apple DF, Anson CA, Hunter JD, Bell RB. Spinal cord injury in youth. *Clinical Pediatrics* 1995; 34: 90–95.
- 6 Hofbauer M, Jaendl M, Höchtll LL, Ostermann RC, Kdolsky R, Aldrian S. Spine injuries in polytraumatized pediatric patients: characteristics and experience from a Level I trauma center over two decades. *J Trauma Acute Care Surg* 2012; 73: 156–1561.
- 7 Martin BW, Dykes E, Lecky FE. Patterns and risks in spinal trauma. *Arch Dis Child* 2004; 89: 860–865.
- 8 Aarabi B, Koltz M, Ibrahimi D. Hyperextension cervical spine injuries and traumatic central cord syndrome. *Neurosurg Focus* 2008; 25: E9.

Received August 11, 2013

Accepted after revision January 20, 2014