



Angiographic embolization in epistaxis: Our clinical experience and results

 Mehmet Turan Cicek¹,  Ismail Okan Yildirim²,  Tuba Bayindir¹,  Kaya Sarac²,  Mehmet Tan¹,  Mehmet Aslan¹,  Ebru Ozer Ozturk¹

¹Department of Otorhinolaryngology Head and Neck Surgery, Faculty of Medicine, Inonu University, Malatya, Turkey

²Department of Radiology, Faculty of Medicine, Inonu University, Malatya, Turkey

Copyright@Author(s) - Available online at www.annalsmedres.org

Content of this journal is licensed under a Creative Commons Attribution-NonCommercial 4.0 International License.



Abstract

Aim: Nosebleed, more commonly called epistaxis is a general clinical problem, and the most of bleedings can be treated non-invasive approach. However, because of persistent and sometimes life-threatening bleeding, additional treatment such as super-selective embolization may be required. In this study, we report our data on the endovascular treatment of persistent epistaxis.

Materials and Methods: Between January 2010 and December 2019, all patients who were followed up at Inonu University Turgut Ozal Medical Center Otorhinolaryngology Clinic due to recurrent persistent nosebleed and required endovascular treatment were retrospectively screened. Demographic data, cause of epistaxis, localization of the bleeding, the clinical significance of the bleeding, interventional approach, complications related to treatment, and results were evaluated.

Results: All of 18 patients with intractable epistaxis were included in the study. Depending on the etiology of epistaxis, patients were determined into three groups: idiopathic epistaxis (10/18), iatrogenic or traumatic epistaxis (7/18), and nasopharyngeal cancer (1/18). Nine of 18 patients required blood transfusions. The internal maxillary artery was embolized unilaterally in 12 of 18 (66%) and bilaterally in 2 of 18 (11%) procedures. Four patients were not embolized because of bleeding originated from ethmoidal branches of the ophthalmic artery. These four patients were operated on (endoscopic ethmoidectomy and bleeding control). Long-term success rates of embolization were 14 of 14. Major complications (transient hemiparesis) occurred in one patient after embolization.

Conclusion: Endovascular approach proves to be effective for intractable and fatal epistaxis. Embolization has a good risk-benefit ratio in persistent bleeding. However, if bleeding is originated by the ethmoidal branches of the ophthalmic artery, embolization may not be performed to avoid visual complications.

Keywords: Epistaxis; interventional radiology; selective percutaneous embolization

INTRODUCTION

Epistaxis occurs up to 60% of the adult population at any point in their life. Clinically, there are two types of nosebleed: anterior (more common), and posterior (less common but more serious). About 80% of cases consist of anterior nosebleed (1). Luckily, most of the nosebleed is self-limited, with only 6% requiring medical attention (2). However, non-invasive treatments are not always effective for bleeding from the posterior nasal passage and may require further treatment strategies such as surgery or percutaneous artery embolization. Epistaxis is almost equally distributed between the sexes, but persistent posterior epistaxis is more common in older men. Studies show a soft peak in epistaxis cases in the first two decades, followed by an increase after the fourth decade. Many factors could cause nosebleed, including head and face trauma, digital trauma, postoperative

complications, hypertension, inflammation and infections, cancers, vascular anomalies, and especially anticoagulant medication use.

The blood flow of the nasal cavity originates from both the internal carotid artery and the external carotid artery. The anterior and posterior ethmoid arteries originate from the ophthalmic artery that branches off from the internal carotid artery. The facial artery and internal maxillary artery are separated from the external carotid artery. The terminal branch of the internal maxillary artery is the sphenopalatine artery, which usually provides blood flow to the lateral nasal wall and septum (3).

Even in the absence of a vascular malformation, there are several potential connections between the internal and external carotid artery, such as anastomoses between the right and left arterial systems. Therefore, nosebleed may continue despite unilateral arterial embolization. In

Received: 11.03.2020 **Accepted:** 13.04.2021 **Available online:** 23.11.2021

Corresponding Author: Ebru Ozer Ozturk, Department of Otorhinolaryngology Head and Neck Surgery, Faculty of Medicine, Inonu University, Malatya, Turkey **E-mail:** drozerebru@gmail.com

addition, pre-existing anastomoses can be opened due to increased pressure during embolization and undesirable embolization of the internal carotid artery or ophthalmic artery may occur (4,5). Therefore, embolization is contraindicated in the presence of an anastomosis between the external and internal carotid artery or in cases of bleeding in the ethmoid artery, a branch of the ophthalmic artery, due to the risk of blindness (1,2,6).

Angiographic embolization is the accepted invasive treatment option for severe refractory epistaxis. The aim of this study was to evaluate the success and complication rates of angiographic embolization, which has been applied for many years in a tertiary medical center.

MATERIALS and METHODS

Study Population

All patients presenting with intractable epistaxis, which required endovascular treatment at the Department of Invasive Radiology in Inonu University Turgut Ozal Medical Center between January 2010 and December 2019, were retrospectively evaluated. The tenets of Helsinki Declaration were followed and the study protocol was approved by the Local Ethics Committee (Reference number: 2020/574). The patients were classified according to the etiology of the bleeding. Demographic factors (age, gender) of patients, concomitant diseases, the origin of bleeding, the period of hospitalization, interventional approach (target artery), complications, and short and long-term outcomes were evaluated.

Embolization

All endovascular procedures were performed under local anesthesia and a transfemoral approach. In each procedure, bilateral angiography of the internal and external carotid artery was performed primarily, and vascular anastomoses or arteriovenous malformations were evaluated. A microcatheter was advanced to the ECA branches with a micro guidewire. After reaching the internal maxillary artery, a branch of the external carotid, the micro-catheter was placed more distally towards the sphenopalatine artery. Embolization was performed using a 0.014 0 micro-catheter (Excel™-14, Boston Scientific, USA) that allowed medium-sized particles and coils to be injected appropriately. Vascular closure was checked on the fluoroscopy screen with repeated angiograms after embolization. The embolization process was terminated when the blood flow in the capillary bed and distal to the occluded artery ceased. Embolizing injection anastomoses were applied slowly and carefully in order not to escape back to the internal carotid artery.

In cases where active bleeding was detected during angiography, only the bleeding side was embolized. In patients who did not have active bleeding during angiography, the side suspected in their pre-procedure examination was embolized. If the bleeding continues and the source could not be identified, the counter sphenopalatine artery was also embolized. Nasal packings applied before the procedure was removed the next day.

Statistical Analysis

SPSS for Windows statistical software (ver. 22.0; IBM Corp., Armonk, NY, USA) was used for the analyses. The results are expressed as mean \pm standard deviation (min-max).

RESULTS

Within ten years, 18 patients (11 males and seven females; mean age 48.5 ± 19.5 (19–88) years suffering from persistent epistaxis underwent angiography and selective intra-arterial intervention at our center. Before the endovascular intervention, non-invasive methods (cauterization with the help of endoscopy under local anesthesia and anterior and / or posterior repetitive nasal packing) were applied. A selective intra-arterial approach was used for nosebleed that was unsuccessful by non-invasive methods. The mean hemoglobin before endovascular treatment was 10.1 ± 1.6 g/dl (6,8–14.2). Nine of 18 (22%) patients received blood transfusions. No cardiopulmonary resuscitation or advanced cardiac life support was required during hospitalization. In 6 of 18 (33%) procedures, the bleeding source could be visualized angiographically (Figure 1). Twelve patients underwent embolization prophylactically according to clinical information. In all of the 14 patients, endovascular treatment resulted in the immediate ending of epistaxis: an initial success rate of 100 %. Four patients (2 traumatic and two idiopathic) were not embolized because of bleeding originated from ethmoidal branches of the ophthalmic artery. These patients were operated on (endoscopic ethmoidectomy and coagulation of the ethmoidal artery).

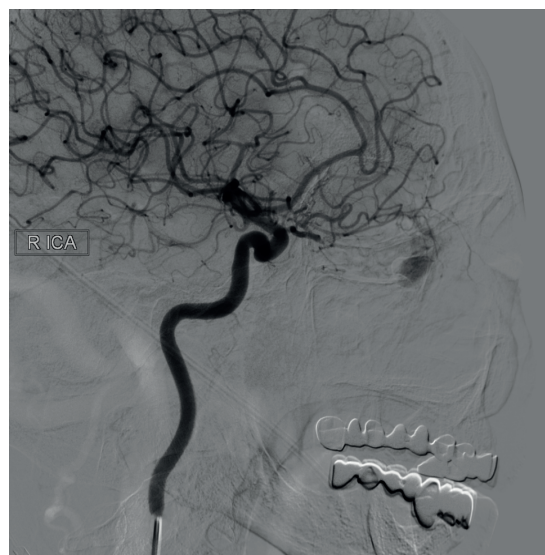


Figure 1. The origin of epistaxis which visualized angiographically. The internal maxillary artery was embolized at different levels in 14 patients. Unilateral embolization of this artery was performed in 12 of 14 (85.7%) patients (Figure 2) and bilateral embolization in 2 of 14 (14.2%) patients. Additional embolization did not require in any patients.

The average hospitalization before embolization was 1.3 ± 1.2 (0–4) days, and the average hospitalization after

embolization was 4.4 ± 2.4 (1–9) days. Angioembolization was used as the first choice in the treatment of nosebleed, which were attempted but failed in another center, applied to our clinic.

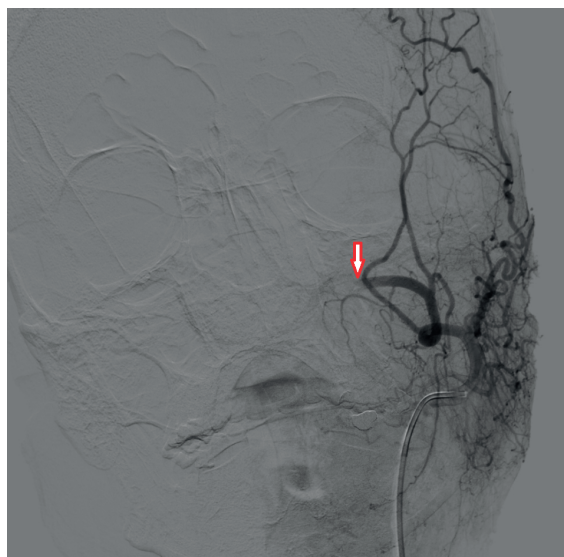


Figure 2. Unilateral embolization of the internal maxillary artery

In 10 of 18 patients, the cause of epistaxis was unknown and was considered idiopathic. In 4 of this idiopathic group, there were cardiovascular risk factors such as hypertension and anticoagulant use, which predispose to epistaxis. Embolization was not applied to two idiopathic patients whose bleeding was originated from the ethmoidal branches of the ophthalmic artery. The other eight patients were embolized, and all succeeded.

Five of 18 patients (27%) who underwent septal surgery (three patients), transsphenoidal pituitary surgery (two patients) suffered from postoperative bleedings. The internal maxillary artery of two patients was bilaterally embolized due to bleeding after transsphenoidal pituitary surgery. Other cases were embolized unilaterally. Two of 18 cases occurred due to post-traumatic ethmoidal or maxillary bone fractures. Two patients (one posttraumatic and one after septal surgery) were not embolized because of bleeding originated from ethmoidal branches of the ophthalmic artery.

Unilateral embolization was applied to a patient who was followed up for nasopharyngeal cancer and had resistant nasal bleeding. There was no bleeding after embolization.

Transient left-sided weakness occurred in only one patient after right internal maxillary artery embolization.

DISCUSSION

Nosebleed is a common emergency and usually resolves with non-invasive methods, but it is a frightening condition for patient. Fortunately, persistent recurrent and fatal nosebleed rarely occurs. However, interventional procedures such as endovascular or surgical treatment are required in these bleeding where conventional treatment cannot provide hemostasis. The procedure

was successful in all 14 patients in our series, with a low rate of complications. In our study, the success rate of endovascular treatment was quite high (100%; 14/14), which is consistent with the findings of other studies reporting success rates ranging from 93% to 100% (7-12).

In our study, bilateral embolization of the internal maxillary artery was performed in 11% of patients and unilateral embolization in 66% of patients. In previous studies, the success of unilateral internal maxillary artery embolization was reported to be 74% (7,13,14). The reason for continuing nosebleeds despite successful embolization is anterior ethmoid artery bleeding and/or mucosal tears caused by nasal packing (8,15-17).

In the literature, major complications, such as blindness, ipsilateral facial paralysis, cerebrovascular accidents, necrosis of the soft tissue of the cheek or nose, have been reported (6,8,14,15,18). In our study, temporary local dental, oral, nasal pain reported in one-third of patients, was the major complaint, and also one patient suffered from transient hemiparesis after unilateral embolization of the internal maxillary artery. These complications were thought to be caused by the powerful injection of the embolic agent and the backflow of particles into the internal carotid artery (7).

Other treatment strategies for prolonged epistaxis show complication rates similar to percutaneous embolization. Surgical intervention for persistent nosebleeds originating from the internal maxillary artery also has a complication rate of 3 to 47% (1,7,13,19-22).

In addition, percutaneous embolization can be performed quickly and easily repeated if necessary. Unlike surgical intervention, percutaneous embolization can be performed under local anesthesia and selectively obliterated, focusing on the most distal blood vessels from which the bleeding originates. Additionally, vascular anomalies and the exact location of bleeding can be determined by angiography before embolization. In our cases, vascular hemorrhage was detected in 6 (33%) of 18 cases and 4 of them originated from the ethmoid artery. Our patients were treated about 1 day before the embolization, but the average hospital stay after embolization is about 4 days. In addition, in 9 (50%) of 18 patients, blood transfusion was required before embolization due to excessive bleeding. Therefore, we think that early endovascular interventions may reduce the length of hospital stay and the need for blood transfusion.

CONCLUSION

Transarterial embolization applied in the interventional radiology clinic is an effective method in the treatment of epistaxis that is resistant to non-invasive traditional treatment. Obliteration focused on distal blood vessels causing persistent nosebleeds can be applied to most patients. In most cases, it can be performed under local anesthesia without requiring general anesthesia. Serious complications can be seen, but the complication rates related to the procedure are very low in experienced hands.

Competing Interests: The authors declare that they have no competing interest.

Financial Disclosure: There are no financial supports.

Ethical Approval: The study protocol was approved by the Inonu University Scientific Research and Publishing Ethics Committee (Reference number: 2020/574).

REFERENCES

1. Schaitkin B, Strauss M, Houck JR. Epistaxis: medical versus surgical therapy: a comparison of efficacy, complications, and economic considerations. *Laryngoscope* 1987;97:1392-6.
2. Small M, Murray JA, Maran AG. A study of patients with epistaxis requiring admission to hospital. *Health Bull (Edinb)* 1982;40:20-9.
3. Leppanen M, Seppanen S, Laranne J et al. Microcatheter embolization of intractable idiopathic epistaxis. *Cardiovasc Intervent Radiol* 1999;22:499-503.
4. Pope LE, Hobbs CG. Epistaxis: an update on current management. *Postgrad Med J* 2005;81:309-14.
5. Willems PW, Farb RI, Agid R. Endovascular treatment of epistaxis. *AJNR Am J Neuroradiol* 2009;30:1637-45.
6. Strach K, Schrock A, Wilhelm K. Endovascular treatment of epistaxis: Indications, management, and outcome. *Cardiovasc Inter-vent Radiol* 2011;34:1190-8.
7. Vitek J. Idiopathic intractable epistaxis: endovascular therapy. *Radiology* 1991;181:113-6.
8. Tseng EY, Narducci CA, Willing SJ, et al. Angiographic embolization for epistaxis: a review of 114 cases. *Laryngoscope* 1998;108:615-9.
9. Oguni T, Korogi Y, Yasunaga T, et al. Superselective embolisation for intractable idiopathic epistaxis. *Br J Radiol* 2000;73:1148-53.
10. Duncan IC, Fourie PA, le Grange CE, et al. Endovascular treatment of intractable epistaxis—results of a 4-year local audit. *S Afr Med J* 2004;94:373-8.
11. Sadri M, Midwinter K, Ahmed A, et al. Assessment of safety and efficacy of arterial embolisation in the management of intractable epistaxis. *Eur Arch Otorhinolaryngol* 2006;263:560-6.
12. Fukutsuji K, Nishiike S, Aihara T, et al. Superselective angiographic embolization for intractable epistaxis. *Acta Otolaryngol* 2008;128:556-60.
13. Cullen MM, Tami TA. Comparison of internal maxillary artery ligation versus embolization for refractory posterior epistaxis. *Otolaryngol Head Neck Surg* 1998;118:636-42.
14. Wehrli M, Lieberherr U, Valavanis A. Superselective embolization for intractable epistaxis: experiences with 19 patients. *Clin Otolaryngol Allied Sci* 1988;13:415-20.
15. Elahi MM, Parnes LS, Fox AJ, et al. Therapeutic embolization in the treatment of intractable epistaxis. *Arch Otolaryngol Head Neck Surg* 1995;121:65-9.
16. Moreau S, De Rugy MG, Babin E, et al. Supraselective embolization in intractable epistaxis: review of 45 cases. *Laryngoscope* 1998;108:887-8.
17. Siniluoto TM, Leinonen AS, Karttunen AI, et al. Embolization for the treatment of posterior epistaxis. An analysis of 31 cases. *Arch Otolaryngol Head Neck Surg* 1993;119:837-41.
18. de Vries N, Versluis RJ, Valk J, et al. Facial nerve paralysis following embolization for severe epistaxis (case report and review of the literature). *J Laryngol Otol* 1986;100:207-210.
19. Tan LK, Calhoun KH. Epistaxis. *Med Clin North Am* 1999;83:43-56.
20. Strutz J, Schumacher M. Uncontrollable epistaxis. Angiographic localization and embolization. *Arch Otolaryngol Head Neck Surg* 1990;116:697-9.
21. Metson R, Lane R. Internal maxillary artery ligation for epistaxis: an analysis of failures. *Laryngoscope* 1988;98:760-4.
22. Wang L, Vogel DH. Posterior epistaxis: comparison of treatment. *Otolaryngol Head Neck Surg* 1981;89:1001-6.