



## Bilateral Nevoid Hyperkeratosis of the Nipple and/or Areola: A Case Report

Serpil Sener<sup>1</sup>, Sezai Sasmaz<sup>2</sup>

<sup>1</sup> Department of Dermatology, Inonu University School of Medicine, Turgut Ozal Medical Center, Malatya, Turkey

<sup>2</sup> Department of Dermatology, Gazi University School of Medicine, Ankara, Turkey

### Abstract

*Nevoid hyperkeratosis of the nipple and areola (NHNA) is a rare condition, in which the skin of the nipple and/or areola becomes diffusely thickened, hyperpigmented, and covered with filiform or papular warty excrescences. Although it affects both men and woman, approximately 80% of cases occur in women. Pathogenic mechanisms have been proposed but mainly unsubstantiated. Moreover, specific treatment guidelines do not exist partly because of the unknown pathogenesis of this disorder. We report a female patient with this rare condition.*

**Key Words:** Bilateral nevoid hyperkeratosis, nipple, areola

(Rec.Date: Oct 02, 2014)

Accept Date: Oct 20, 2014)

---

**Corresponding Author:** Serpil Sener, Department of Dermatology, Inonu University School of Medicine, Turgut Ozal Medical Center, Malatya, Turkey

**E-mail:** senerserpil@hotmail.com

## Introduction

Nevoid hyperkeratosis of the nipple and/or areola (NHNA) is an unusual condition of unknown etiology. In 1938, Levy and Frankel described three clinical types of NHNA. Specific treatment guidelines do not exist because of the unknown pathogenesis of this dermatosis [1].

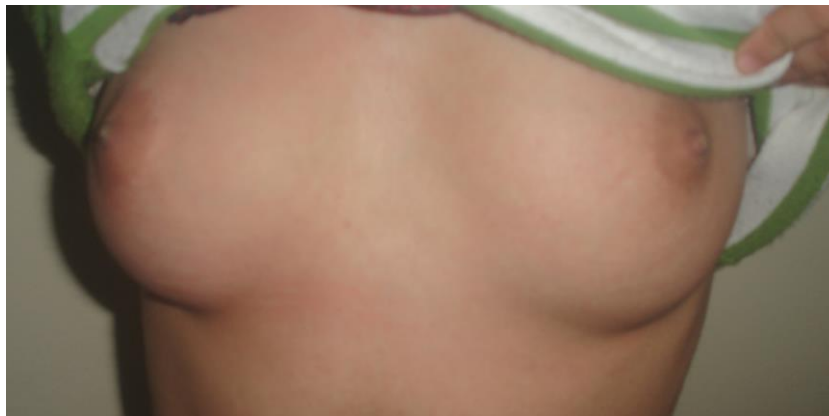## Case

A 20-year-old unmarried female presented with a 3-month history of growths on her nipples. She denied associated pain and itching. There was no history of discharge from the nipples. She was not taking any medication. There was no personal or family history of any dermatologic diseases.

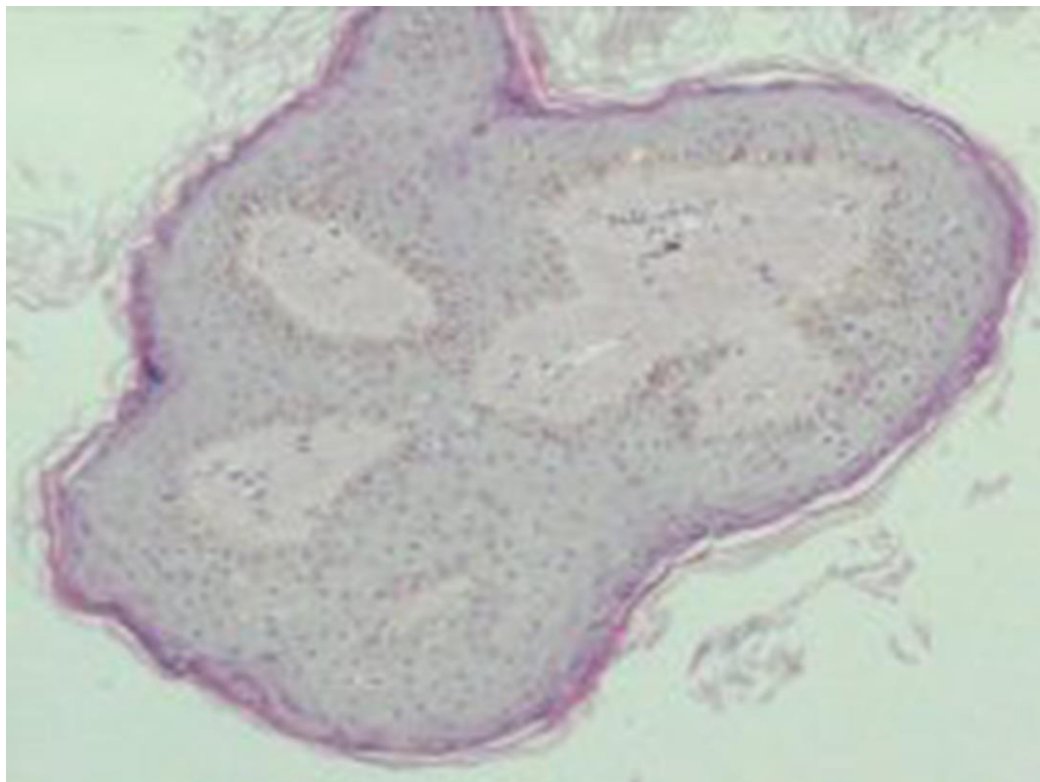
Physical examination revealed brown, verrucous plaques on both nipples (Figure1). There were no changes in the areolae. Breast examination was normal. Baseline laboratory values were within normal limits.

Histological examination of a punch biopsy specimen revealed papillomatosis, acanthosis and hyperkeratosis (Figure 2). Hyperpigmented verrucous plaque was seen as more prominent on the right nipple (Figure 3).

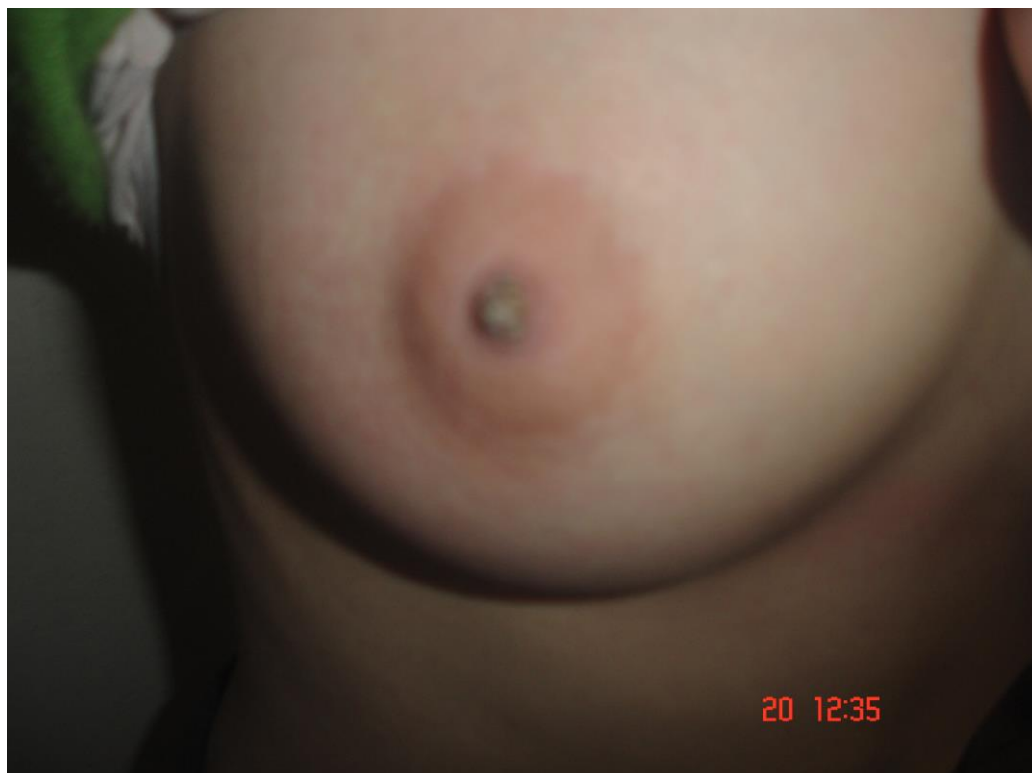We made the diagnosis of NHNA, based on clinical and histopathological findings. The patient was prescribed topical calcipotriol cream applied to the lesions twice a day, but after 4 weeks of therapy no improvement was noted.



**Figure 1.** Bilateral hyperpigmented verrucous lesions of the nipples.



**Figure 2.** Hyperkeratosis, papillomatosis and acanthosis (H&E x100).



**Figure 3.** Hyperpigmented verrucous plaque on the right nipple.

## Discussion

In 1938, Levy and Frankel described three distinct types of hyperkeratosis of the nipple and/or areola. Type 1 is hyperkeratosis as an extension of an epidermal nevus. Type 2 is hyperkeratosis associated with other dermatoses, such as acanthosis nigricans, ichthyosis, lymphoma, chronic eczema, seborrheic keratoses or Darier's disease. Type 3 is nevoid hyperkeratosis, not associated with an epidermal nevus or other dermatoses [1,2].

NHNA, is an uncommon idiopathic disorder with approximately 50 reported cases in the literature. Although it affects both men and women, 80% of the cases are women [3]. Typically, the lesions are not bothersome to the patient with the exception of their undesirable appearance [3]. On occasion an affected patient may experience pruritus.

NHNA presents as hyperkeratotic, hyperpigmented plaques. The lesions may involve the nipple, the areola, or both. Kubota et al. reviewed 45 cases of nevoid hyperkeratosis in which 17% of cases involved the nipple, 25% of cases involved the areola and 58% of cases involved both the nipple and the areola [4]. There are several reports of unilateral nevoid hyperkeratosis [5], but the lesions are often bilateral.

The etiology of NHNA is unknown. A change in estrogen levels has been thought to precipitate this condition [6]. The histological features include orthokeratotic hyperkeratosis, papillomatosis, acanthosis and occasional keratotic plugging. There may be a mild perivascular lymphocytic infiltrate in the dermis [7].

The differential diagnosis of NHNA includes verruca filiformis, seborrheic keratosis, Paget's disease, basal cell carcinoma, dermatophytosis, epidermal nevus, atopic eczema, acanthosis nigricans and Bowen's disease [7]. These disorders can be distinguished from NHNA by correlating clinical and histopathological features.

The treatment of NHNA generally consists of cryotherapy or topical keratolytic agents [5,8-10], CO<sub>2</sub> laser [11], topical corticosteroids [7], topical tretinoin [2], calcipotriol [12], etretinate [13], radiofrequency [14] and surgical excision [15] have been tried.

We present the patient with bilateral nevoid hyperkeratosis of the nipple, who have been diagnosed on the basis clinical and histopathological features and treated with topical calcipotriol ointment twice daily for 4 weeks did not improve the lesions.

## References

1. Levy-Frankel A. Les hyperkeratoses de l'areola et du mamelon. Paris Med. 1938;28:63-6.
2. Toros P, Onder M, Gurer M. Bilateral nipple hyperkeratosis treated successfully with topical isotretinoin. Aust J Dermatol. 1999;40(4):220-2.
3. Revert A, Bañuls J, Montesinos E, Jorda E, Ramon D, Torres V. Nevoid hyperkeratosis of areola. Int J Dermatol. 1993;32(10):745-6.
4. Kubota Y, Koga T, Nakayama J, Kiryu H. Nevoid hyperkeratosis of the nipple and areola in a man. Br J Dermatol. 2000;142(2):370-93.
5. Vestey J, Bunney M. Unilateral hyperkeratosis of nipple: The response to cryotherapy. Arch Dermatol. 1986;122(12):1360-1.
6. Mold DE, Jegasothy BV. Estrogen induced hyperkeratosis of the nipple. Cutis. 1980;26(1):95-6.
7. Krishnan RS, Angel TA, Roark TR, Hsu S. Nevoid hyperkeratosis of the nipple and/or areola: A report of two cases and a review of the literature. Int J Dermatol. 2002;41(11):775-7.
8. Mitxelena J, Raton J, Bilbao I, Diaz-Perez J. Nevoid hyperkeratosis of the areola in men: response to cryotherapy. Dermatol. 1999;199(1):73-4.
9. Kuhlman DS, Hodge SJ, Owen LG. Hyperkeratosis of the nipple and areola. J Am Acad Dermatol. 1985;13(4):596-8.
10. English J 3rd, Coats NV. A man with nevoid hyperkeratosis of the areola. Cutis. 1996;57(5):354-6.
11. Alpsoy E, Yılmaz E, Aykol A. Hyperkeratosis of the nipple: report of two cases. J Dermatol. 1997;24(1):43-5.
12. Bayramgurler D, Bilen N, Apaydin R, Ercin C. Nevoid hyperkeratosis of the nipple and areola: Treatment of two patient with topical calcipotriol. J Am Acad Dermatol. 2002;46(1):131-3.
13. Ortonne JP, el Baze P, Juhlin L. Nevoid hyperkeratosis of the nipple and areola: Ineffectiveness of etretinate treatment. Acta Dermatol Venereol. 1986;66(2):175-7.
14. Ozyazgan I, Kontas O, Ferahbas A. Treatment of nevoid hyperkeratosis of the nipple and areola using radiofrequency surgical unit. Dermatol Surg. 2005;31(6):703-5.
15. Mehregan AH, Rahbari H. Hyperkeratosis of nipple and areola. Arch Dermatol. 1977;113(12):1691-2.