



# No Mortality or Pancreatic Fistula After Full-Thickness Suture Pancreaticogastrostomy in 39 Patients Who Underwent Pancreaticoduodenectomy

Ozdemir Fatih<sup>1</sup>, Baskiran Adil<sup>1</sup>, Ara Cengiz<sup>1</sup>, Ates Mustafa<sup>1</sup>, Kahraman Ayşegül Sagir<sup>2</sup>, Ozdemir Zeynep Maras<sup>2</sup>, Yilmaz Sezai<sup>1</sup>

<sup>1</sup>*Inonu University School of Medicine, Turgut Ozal Medical Center, Department of Surgery, Malatya, Turkey*

<sup>2</sup>*Inonu University School of Medicine, Turgut Ozal Medical Center, Department of Radiology, Malatya, Turkey*

Pancreaticoduodenectomy is considered the standard operation for periampullary tumors. Despite major advances in pancreatic surgery, pancreatic fistula is still an important cause of morbidity and mortality after pancreaticoduodenectomy. Meticulous surgical technique and proper reconstruction of the pancreas are essential to prevent pancreatic fistula. Pancreaticogastrostomy is a safe method for reconstruction of the pancreas after pancreaticoduodenectomy. Regardless of pancreatic texture or duct diameter, the reconstruction is performed by passing full-thickness sutures through both the anterior and posterior sides of the pancreas. In this study, we report 39 cases of reconstruction with pancreaticogastrostomy after pancreaticoduodenectomy without mortality or pancreatic fistula.

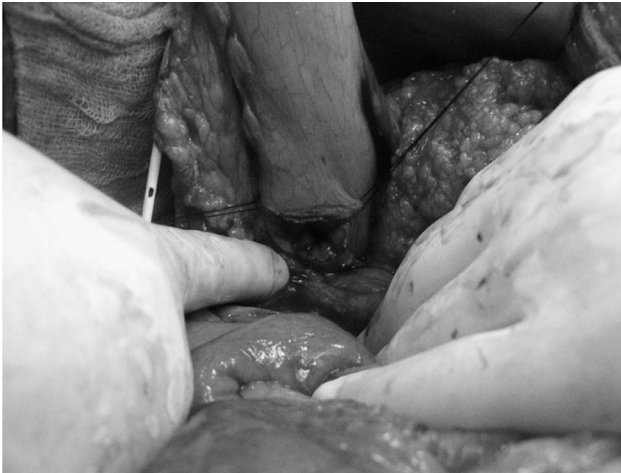*Key words:* Pancreaticogastrostomy – Pancreatic fistula – Pancreaticoduodenectomy – Full-thickness sutures

Pancreaticoduodenectomy (PD) is considered the standard treatment for periampullary tumors. Despite major advances in pancreatic surgery, overall postoperative morbidity after PD is high, even in high-volume centers.<sup>1</sup> While the operation-associated mortality rate of pancreatic surgery has decreased to less than 4%, the operation-associated morbidity rate is reported to be as high as 50%,

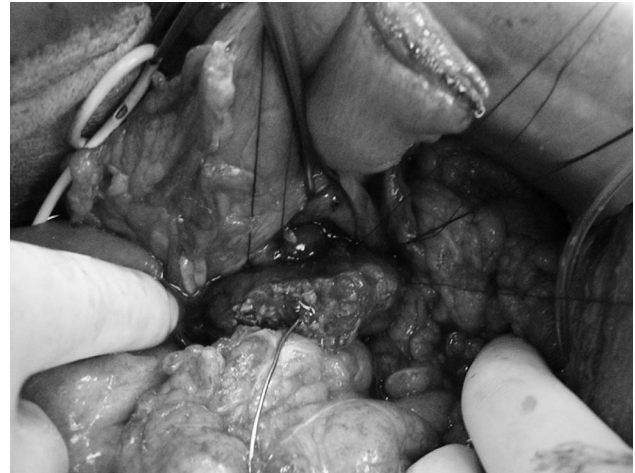---

Corresponding author: Ozdemir Fatih, Elazig Road, 15th kilometer, Inonu University School of Medicine, Department of Surgery, Malatya, Turkey 44280.

Tel.: +90 422 341 06 60- 3701 or +90 533 547 50 78; Fax: +90 422 341 06 60; E-mail: fatihup@hotmail.com



**Fig. 1** The posterior wall of the stomach was approximated to the remnant pancreas.



**Fig. 2** Sutures were passed through the posterior seromuscular layer of the stomach.

largely due to the pancreaticoenteric anastomosis, the “Achilles’ heel” of pancreatic surgery.<sup>2–4</sup>

Pancreatic fistula (PF) is the most important cause of morbidity and mortality after PD. Soft pancreatic tissue texture and small pancreatic duct diameter have been identified as risk factors for PF. Pancreatic fistula may cause life-threatening complications, such as postoperative hemorrhage and peritonitis.<sup>5</sup> We report the first cases without mortality or PF in 39 patients who were reconstructed with pancreaticogastrostomy (PG) after PD. In this study, we performed the PG by passing full-thickness sutures through the pancreas wall from both the anterior and posterior sides of the gland regardless of pancreatic tissue texture or pancreatic duct diameter.

## Methods

We retrospectively reviewed the medical records of 39 patients who underwent PD between 2010 and 2013 at Inonu University, Turgut Ozal Medical Center. Inonu University School of Medicine Ethics Committee approval was obtained. Data collected included demographic information, surgical technique, postoperative complications, mortality, laboratory values, and imaging studies. Pancreatic duct diameter of the patients was measured by 2 radiologists on the computed tomography (CT) scans obtained preoperatively. Abdominal drain amylase levels were evaluated daily during the postoperative period. Concentrations of drain amylase levels were determined from the combined 24-hour output of both abdominal drains. Abdominal drains were removed when the output was less than

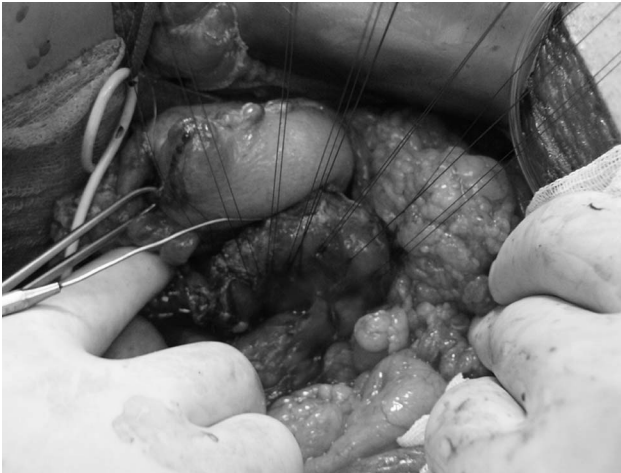30 mL/d and also when the drain amylase level was below 3 times lower than serum amylase activity.

Bassi *et al* reported an international study group definition about pancreatic fistula (ISGPF) in 2005.<sup>6</sup> We diagnosed the postoperative PF with clinical, laboratory, and radiologic findings. Actually the main sign for the diagnosis of PF was the persistent drainage of the operatively-placed drain with an amylase content greater than 3 times the upper normal serum value. Also laboratory and radiologic findings like high serum leukocyte count, increased C-reactive protein, and visualization of peripancreatic fluid collection were helpful for the diagnosis.

## Surgical technique

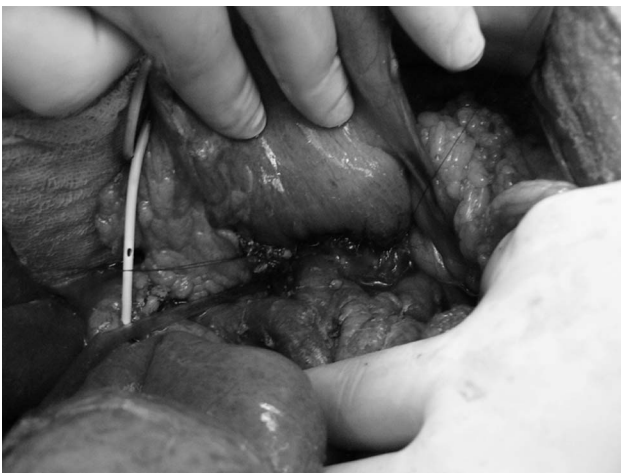PD was performed according to a standardized technique as described previously.<sup>7</sup> All patients underwent an extended lymphadenectomy. The bile duct, hepatic artery, portal vein, celiac trunk, and superior mesenteric artery were routinely skeletonized. The neck of the pancreas was transected to the left of the portal vein. After removing the specimen, the remnant pancreas was freed from the retroperitoneal attachments. The posterior wall of the stomach was approximated to the remnant pancreas without tension, and a gastrotomy was made at the antrum (Fig. 1).

To perform the PG, double-armed polypropylene sutures were passed from the posterior pancreatic wall to the anterior pancreatic wall through the full thickness of the organ. These sutures were then passed through the posterior seromuscular layer of the stomach (Fig. 2). Next, double-armed polypro-

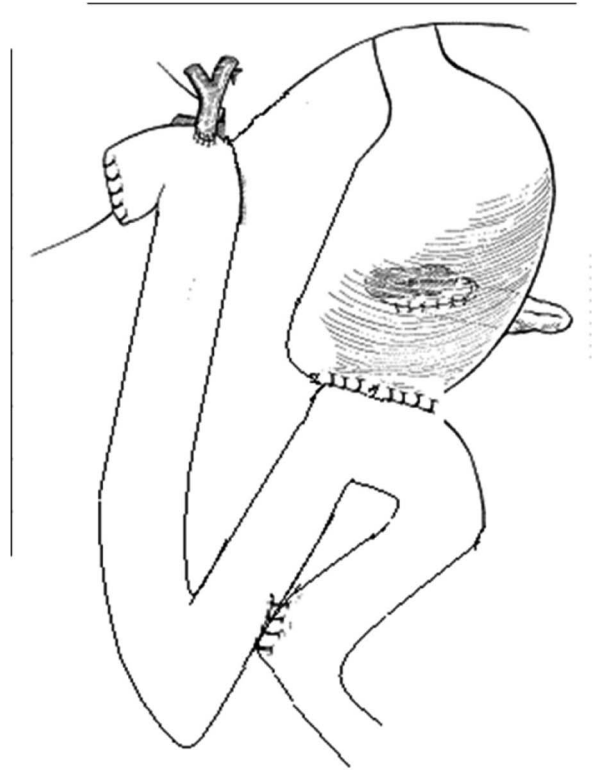


**Fig. 3** Sutures were passed from the anterior to the posterior pancreatic wall.

pylene sutures were passed through the anterior pancreatic wall to the posterior pancreatic wall through the full thickness of the organ (Fig. 3). A Bakes dilator was used to cannulate the pancreatic duct and prevent inadvertent incorporation of the duct with suture. After tying the sutures of the posterior wall, the stump of the pancreas was inverted into the stomach. The anterior side of the anastomosis was completed by passing the sutures that had already been placed through the full thickness of the pancreatic wall into the anterior seromuscular layer of the stomach. Methylene blue was instilled into the nasogastric tube to check for anastomotic leak (Fig. 4). The greater omentum was mobilized from the transverse colon and sutured to the stomach to enclose both anterior and posterior



**Fig. 4** Anastomotic leak was tested intraoperatively by giving methylene blue via the nasogastric tube.



**Fig. 5** Final illustration of the anastomosis.

aspects of the anastomosis. Finally, the procedure was completed by performing an end-to-side hepaticojejunostomy, gastrojejunostomy, and also jejunojunctionostomy for avoiding the reflux of the bile to stomach (Fig. 5).

Three abdominal drains were placed after the operation. Two drains were placed at the anterior side and posterior side of the pancreaticogastrostomy anastomosis. Last drain was placed around the hepaticojejunostomy anastomosis.

## Results

Thirty-nine patients underwent PG after PD during the study period. There were 24 males (61.54%) and 15 females (38.64%) with a mean age of 59 years (median, 59 years; range, 37–78 years). Body mass index of the patients ranged from 19 to 28. Median length of hospital stay was 11 days. The most common indication for PD was the tumors of pancreatic head (n = 22). Other indications were carcinoma of the ampulla of Vater (n = 11),

Table 1 Demographics, fitness grade, and histopathologic features

Variable	Patients (n = 39)
Age, median (IQR)	59 (37–78)
Sex, F:M	15:24
Body mass index, median (IQR)	23 (19–28)
Length of hospital stay, day, median (IQR)	11 (8–22)
ASA fitness, n (%)	
Grade I	5 (13)
Grade II	20 (51)
Grade III	12 (31)
Grade IV	2 (5)
Tumor location, n (%)	
Pancreatic head	22 (57)
Ampulla	11 (28)
Distal bile duct	4 (10)
Duodenum	2 (5)

IQR, interquartile range; ASA, American Society of Anesthesiologists.

carcinoma of the distal common bile duct (n = 4), and carcinoma of the duodenum (n = 2; Table 1).

Standard PD was performed in 36 cases (92.3%) and pylorus-preserving PD was performed in 3 cases (7.6%). Twenty-three patients had a firm pancreatic texture and the remaining 16 had a soft pancreatic texture. The mean diameter of the pancreatic ducts was 3.8 mm (1–12.4 mm). There was no intra-abdominal abundant bleeding intraoperatively. Mean abdominal drain amylase levels were 80.4 U/L (22–365) on the first postoperative day and 63.3 U/L (20–180) on the third postoperative day. We did not observe any clinical evidence for PF. There was no postoperative pancreatitis. There were no mortalities.

Ten (25.6%) patients developed complications. Two (5.1%) required reoperation. The first patient had an uncontrolled leak from the gastrojejunostomy, which was repaired with double-layer interrupted stitches. The second patient had a pancreaticojejunostomy (PJ) at another institution that leaked, and we performed a PG. The patient developed an uncontrolled leak at jejunojunction, which required revision on the fifth postoperative day. Both patients recovered uneventfully. Another patient developed a low-output (80 mL/d) leak from the hepaticojejunostomy that was treated with percutaneous placement of an external biliary drain by interventional radiology. Delayed gastric emptying occurred in 4 patients, who were treated with nasogastric tube decompression and erythromycin. All 4 patients recovered without further intervention. Two patients developed pneumonia that was treated with antibiotics. Superficial wound infection occurred in 1 patient, treated by bedside opening of the wound (Table 2).

Table 2 Complications

Complications, n (%)	Patients, n (%)
Anastomotic leak	3 (7.6)
Delayed gastric emptying	4 (10.2)
Pneumonia	2 (5.1)
Wound infection	1 (2.5)

## Discussion

Pancreaticogastrostomy has been reintroduced recently as a method for reconstruction of the pancreas after PD with several advantages over PJ.<sup>5,8</sup> Pancreaticoenteric anastomosis is more vulnerable to disruption than anastomoses between hollow viscera such as gastrojejunostomy, jejunojunction, or colocolostomy. The management of the pancreatic remnant after PD has been an area of great concern for pancreatic surgeons, and numerous techniques have been used to reduce PF. These techniques include PJ, PG, end-to-end or end-to-side anastomosis, invagination or duct-to-mucosa anastomosis, the use of an isolated Roux-en-Y limb, binding PJ, pancreatic duct stenting methods, application of topical adhesives, and duct occlusion without pancreaticoenteric anastomosis.

We performed our first PG in a patient who developed peritonitis from a leak at the PJ after PD at another institution. During the exploration, we noted a leak from both PJ and hepaticojejunostomy anastomoses. We drained approximately 1500 mL of bilious, pancreatic fluid from the peritoneal space. After revising the PJ to a PG, the patient recovered uneventfully.

Our technique for performing the PG differs from other centers.<sup>8–10,13</sup> Unlike other techniques, we pass full-thickness sutures through the pancreas from both the anterior and posterior sides of the gland. In addition, the greater omentum is mobilized from the transverse colon and fixed to the stomach to enclose the anastomosis completely. The anastomosis is tested for leak by giving methylene blue via the nasogastric tube. The patients who had an anastomotic leak intraoperatively were controlled with this test. We repaired the anastomosis at the same time during the operation for these patients and none of them developed PF.

The leak rate after PG is quite low, ranging between 0% and 13% in the literature.<sup>10–12,14,15</sup> Marcus *et al*<sup>16</sup> showed that the rate of PF was 36% in high-risk patients with a small, fragile, soft pancreas and a nondilated duct, compared with only 2% in low-risk patients with a dense, fibrotic

pancreas. Particularly in cases with a normal, soft pancreas, it is important to reconstruct the remnant pancreas with a method with the lowest fistula rate. In our study, the PF rate was 0%, even in patients with a soft pancreas and nondilated pancreatic ducts. Full-thickness sutures through both anterior and posterior sides of the pancreas and omental wrapping are unique modifications that may help to prevent PF. External pancreatic duct stenting and omental wrapping around the anastomosis may also help to prevent PF.

In a recent study it was observed that pancreatic duct diameter (< 3 mm) was associated with postoperative PF.<sup>17</sup> We measured the diameter of the Wirsung duct on the CT scans, which were obtained preoperatively. In our study, the mean diameter of the pancreatic ducts was 3.8 mm. We believe that pancreaticogastrostomy is the best surgical technique for the reconstruction after pancreaticoduodenectomy regardless of pancreatic tissue texture and pancreatic duct diameter.

We did not measure intraoperative bleeding, as we did not have abundant bleeding intraoperatively. There were only 5 patients who needed blood transfusion postoperatively. Mean transfusion volume was 2 units of erythrocyte suspension.

The main reason for removing the abdominal drains postoperatively was the impairment of the drained volume. Nevertheless, we removed the abdominal drains when the amylase level of the intra-abdominal fluid collection was below 3 times lower than serum amylase level.

We diagnosed the postoperative PF by following up the abdominal drains and also we searched the radiologic evidence for postoperative PF for every patient. And there was no evidence for postoperative PF for any of our patients clinically even radiologically, so we thought that there was no grade B and C PF due to ISGPF.<sup>6</sup> Also we would never know if our patients developed grade A PF, because all of them recovered well, though they did not receive any specific therapy.

From these results, we recommend using PG to reconstruct the pancreatic remnant regardless of pancreatic tissue texture or pancreatic duct diameter. Full-thickness sutures through both anterior and posterior sides of the pancreas and omental wrapping are unique modifications that may help to prevent PF. The weakness of this study is that there were a small amount of cases, though future studies with larger numbers will help to clarify the advantages of this technique.

## Acknowledgments

All the authors declare that there is no conflict of interest. There is no funding.

## References

1. Rosso E, Bachellier P, Oussoultzoglou E, Scurtu R, Meyer N, Nakano H *et al.* Toward zero pancreatic fistula after pancreaticoduodenectomy with pancreaticogastrostomy. *Am J Surg* 2006;**191**(6):726–732; discussion 733–734
2. Cameron JL, Pitt HA, Yeo CJ, Lillemoe KD, Kaufman HS, Coleman J. One hundred and forty-five consecutive pancreaticoduodenectomies without mortality. *Ann Surg* 1993;**217**(5): 430–435; discussion 435–438
3. Miedema BW, Sarr MG, Van Heerden JA, Nagorney DM, McIlrath DC, Ilstrup D. Complications following pancreaticoduodenectomy. Current management. *Arch Surg* 1992;**127**(8): 945–949; discussion 949–950
4. Callery MP, Pratt WB, Vollmer CM Jr. Prevention and management of pancreatic fistula. *J Gastrointest Surg* 2009; **13**(1):163–173. Epub 2008 May 22. Review
5. Yeo CJ, Cameron JL, Maher MM, Sauter PK, Zahurak ML, Talamini MA *et al.* A prospective randomized trial of pancreaticogastrostomy versus pancreaticojejunostomy after pancreaticoduodenectomy. *Ann Surg* 1995;**222**(4):580–588
6. Bassi C, Dervenis C, Butturini G, Fingerhut A, Yeo C, Izbicki J *et al.* Postoperative pancreatic fistula: an international study group (ISGPF) definition? International Study Group on Pancreatic Fistula Definition. *Surgery* 2005;**138**(1):8–13. Review
7. Oussoultzoglou E, Bachellier P, Bigourdan JM, Weber JC, Nakano H, Jaeck D. Pancreaticogastrostomy decreased re-laparotomy caused by pancreatic fistula after pancreaticoduodenectomy compared with pancreaticojejunostomy. *Arch Surg* 2004;**139**(3):327–335
8. Takao S, Shinchi H. Pancreaticogastrostomy: a pancreas-transfixing method with duct-to-mucosa anastomosis. *J Hepatobiliary Pancreat Sci* 2012;**19**(2):131–134
9. Post M, Wrzesinski M, Klek R, Lubikowski J, Wojcicki M. Pancreatoduodenectomy with subtotal stomach-preserving and uncut Roux reconstruction. *Eur Surg Res* 2011;**47**(1):1–4
10. Aranha GV, Hodul P, Golts E, Oh D, Pickleman J, Creech S. A comparison of pancreaticogastrostomy and pancreaticojejunostomy following pancreaticoduodenectomy. *J Gastrointest Surg* 2003;**7**(5):672–682
11. Peng SY, Wang JW, Li JT, Mou YP, Liu YB, Cai XJ. Binding pancreaticojejunostomy—a safe and reliable anastomosis procedure. *HPB (Oxford)* 2004;**6**(3):154–160

12. Oida T, Mimatsu K, Kano H, Kawasaki A, Kuboi Y, Fukino N *et al.* Pancreaticogastrostomy in patients with considerably dilated pancreatic ducts *Hepatogastroenterology* 2012;**59**(119): 2330–2332
13. Hong TH, Youn YC, You YK, Kim DG. An easy and secure pancreaticogastrostomy after pancreaticoduodenectomy: transpancreatic suture with a buttress method through an anterior gastrotomy. *J Korean Surg Soc* 2011;**81**(5), 332–338
14. Takano S, Ito Y, Watanabe Y, Yokoyama T, Kubota N, Iwai S. Pancreaticojejunostomy versus pancreaticogastrostomy in reconstruction following pancreaticoduodenectomy. *Br J Surg* 2000;**87**(4):423–427
15. Murakami Y, Uemura K, Hayashidani Y, Sudo T, Hashimoto Y. No mortality after 150 consecutive pancreatoduodenectomies with duct-to-mucosa pancreaticogastrostomy. *J Surg Oncol* 2008;**97**(3):205–209
16. Marcus SG, Cohen H, Ranson JH. Optimal management of the pancreatic remnant after pancreaticoduodenectomy. *Ann Surg* 1995;**221**(6):635–645; discussion 645–648
17. El Nakeeb A, Salah T, Sultan A, El Hemaly M, Askr W, Ezzat H *et al.* Pancreatic anastomotic leakage after pancreaticoduodenectomy. Risk factors, clinical predictors, and management (single center experience). *World J Surg* 2013;**37**(6):1405–1418