

# SPONTANEOUS PNEUMOPERICARDIUM AND PNEUMOMEDIASTINUM

Kemal Arda, MD, Olcay Eldem, MD<sup>1</sup>,  
Ahmet Siğirci, MD, Fikri Özgür Özkan, MD  
Department of Radiology  
<sup>1</sup>Department of Cardiology  
Türkiye Yüksek İhtisas Hospital  
Ankara, Turkey

## ABSTRACT

A 20-year-old man with a 5-year history of ulcerative colitis presented with sudden chest pain and diarrhea. Chest radiography, echocardiography, and computed tomography demonstrated pneumomediastinum and pneumopericardium. The condition resolved completely after one week.

(Asian Cardiovasc Thorac Ann 2000;8:59–61)

## INTRODUCTION

Pneumopericardium, the collection of air or gas in the pericardium, is a serious condition that may become life threatening. Pneumomediastinum is the collection of air or gas in the mediastinum. Spontaneous pneumopericardium and pneumomediastinum, sometimes called pericardial-mediastinal emphysema, is a very rare condition with a multitude of causes: parturition, pulmonary barotrauma, severe cough, asthma, cocaine inhalation, chlorine gas exposure, emesis, and athletics.<sup>1</sup> We describe a case of spontaneous pneumopericardium and pneumomediastinum with unknown etiology, which resolved completely.

## CASE REPORT

A 20-year-old man was admitted to hospital with sudden retrosternal pain and diarrhea. He had a history of ulcerative colitis for 5 years. His blood pressure was 130/80 mm Hg, pulse 80 beats·min<sup>-1</sup> and regular, respiration 12 breaths·min<sup>-1</sup> and temperature 36.5°C. There were generalized bronchovesicular sounds over both lungs. Cardiac auscultation was unremarkable. Laboratory findings were within normal limits except for an erythrocyte sedimentation rate of 38 mm·h<sup>-1</sup>. Electro-

cardiography revealed normal sinus rhythm. Chest radiography showed a double-contoured cardiac silhouette (Figure 1). Esophagograms with water-soluble contrast medium were taken to eliminate the esophageal pathologies; these were normal (Figure 2). Computed tomography of the chest and echocardiography confirmed pneumopericardium and pneumomediastinum (Figure 3).

The pneumopericardium persisted for one week, then resolved completely. In the following 3 weeks, the patient was asymptomatic, capable of normal physical activity, and the chest radiograph was normal.

## DISCUSSION

Pneumopericardium was first described by Bricketeau in 1844, who named the classical pericardial sound associated with this disorder “bruit de moulin” (water-wheel sound).<sup>2</sup> Since then, the etiology of pneumopericardium has been the subject of several case reports and reviews. The causes described in the literature were classified according to etiology.<sup>3</sup> (1) Iatrogenic, including thoracentesis, endotracheal intubation, esophagoenterostomy, postcatheterization of esophageal webs, post-sternal bone marrow aspiration. In preterm infants during treatment of idiopathic respiratory distress syndrome, the use of positive-pressure

---

For reprint information contact:

Kemal Arda, MD Tel: 90 312 481 0150 Fax: 90 312 312 4122 email: kemalarda@yahoo.com  
Ilker 1. Cadde 14/2, Dikmen, Ankara 06460, Turkey.

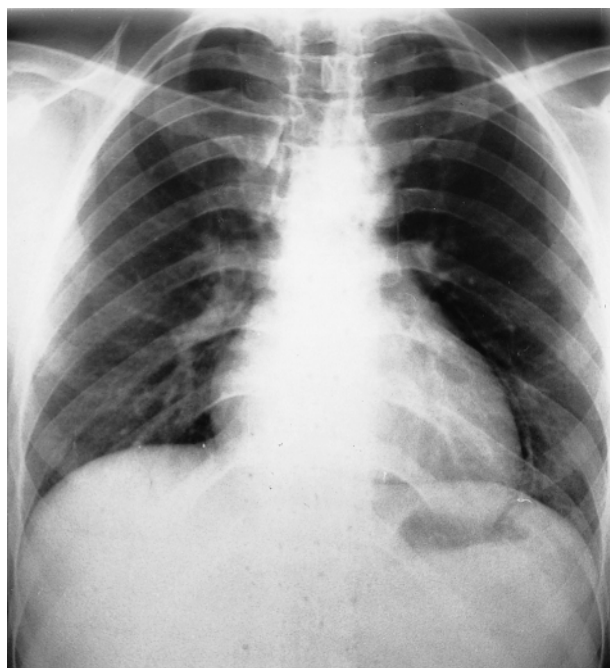
ventilation is an important cause. (2) Trauma, penetrating or blunt, including foreign body aspiration. (3) Pericarditis and production of gas caused by gas-forming organisms. It can also occur by direct extension of an inflammatory process such as lung, liver, or subphrenic abscess. (4) Fistula formation between the pericardium and air-containing structures such as the gastrointestinal tract, the pleural cavity and the bronchial tree.

The rise in the intraalveolar pressure above atmospheric pressure is important in the pathophysiology of pneumopericardium and pneumomediastinum. The alveoli then rupture and air moves to the hilar area, mediastinum, and through the pericardial reflection on the pulmonary vessels into the pericardial cavity. The parietal pericardium is reflected on the visceral pericardium near the ostia of the pulmonary veins, the weakest histological area.<sup>3</sup>

Pneumopericardium may be symptomatic or asymptomatic. The classical symptoms are dyspnea and precordial pain. Other symptoms depend on the underlying etiology. If a large quantity of air is present, the percussion note over the pericardium may become tympanic and the heart sounds may be metallic in quality, accompanied by a splashing sound of high frequency (*bruit de moulin*). However, when only a small amount of air is present, cardiac examination may be normal, as in this case. The chest radiograph confirmed the diagnosis. The gas did not rise above the upper limit of the pericardium in the erect position, differentiating pneumopericardium from pneumothorax or pneumomediastinum. There is also a strip of soft tissue consisting of the pericardium with its associated soft tissue structures.<sup>3</sup> The symptoms of

pneumomediastinum alone may mimic those of pneumopericardium, so radiographic evidence of air in the pericardial space is the pathognomonic sign that must be present to establish conclusively a diagnosis of pneumopericardium.

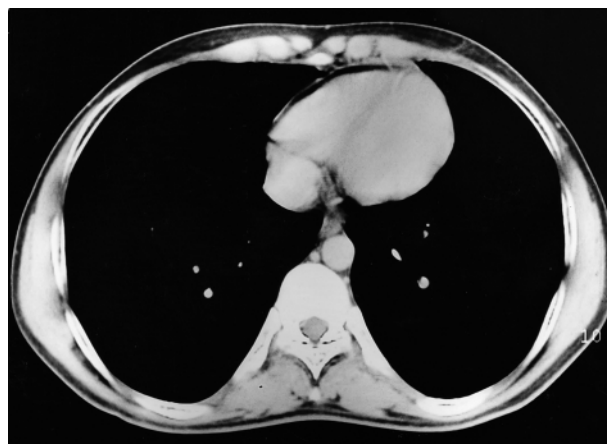
Spontaneous pneumomediastinum and pneumopericardium are almost always self-limiting. Treatment may not be required unless a large amount of air is present or if there is tension pneumopericardium.<sup>4</sup> Most patients recover spontaneously within one or two weeks, as in this case.<sup>1</sup>



**Figure 1.** The chest radiograph showing a double contour on the left side of the cardiac silhouette.



**Figure 2.** Contrast esophagogram showing no pathologic changes.



**Figure 3.** Computed tomography scan showing the appearance of the pneumopericardium at the anterior side of the right ventricle.

**REFERENCES**

1. Bartał N, Zaarura S, Marvan H. Spontaneous pneumopericardium and pneumomediastinum. *Ann Otol Rhinol Laryngol* 1990;99:1005–6.
2. Bricketeau M. Observation d'hydropneumopéricarde accompagné d'un bruit de fluctuation perceptible à l'oreille. *Arch Gén Méd* 1844;4:334.
3. Katzir D, Klinovsky E, Kent V, Shucri A, Gilboa Y. Spontaneous pneumopericardium: a case report and review of the literature. *Cardiology* 1989;76:305–8.
4. Abdalla M, Gould L, Bharathan T. Spontaneous pneumopericardium — a case report. *Angiology* 1994;45:81–3.